

## Theodoros Aretaios (1829-1893) and the Foundation of Greek Orthopedic Surgery

Panagiotis Mantzanas, Pavlos Lytsikas-Sarlis, Irina Noskova, Demetrios Zisiadis, Dimitra Makridaki, Konstantinos Laios

Medical School, National and Kapodistrian University of Athens, Athens, Greece

**Correspondence:** *konstlaios@gmail.com*; Tel.: + 30 694 7091434

**Received:** 9 November 2024; **Accepted:** 2 February 2025

### Abstract

**Objective.** This historical vignette aims to elucidate the contributions of Professor Theodoros Aretaios (1829-1893) to orthopedic surgery in nineteenth-century Greece. **Methods.** Documentary research was conducted of Aretaios' personal patient archives, preserved in the National Library of Greece, to validate and evaluate his surgical practices. **Results.** The archival records revealed a total of 22 orthopedic cases. Aretaios primarily performed upper and lower limb amputations and dislocation reductions. Reconstructive bone and joint operations were less frequent in his practice. **Conclusion.** The role which may be played by the archival records is demonstrated within this historical vignette. The work of Theodoros Aretaios highlights the procedures performed in 19<sup>th</sup> century orthopedics in the new Greek state. Aretaios contributed to the establishment of the Greek school of surgical practice and many of the surgeons of his era followed his steps.

**Key Words:** Hellenic Orthopedics ▪ Amputation ▪ Dislocation ▪ Blast Injuries ▪ Reconstructive Surgery.

### Introduction

The practice of orthopedic surgery in the nineteenth century was still in the hands of physicians who practiced general surgery. It was in the early twentieth century that orthopedics became an independent surgical branch in Greece (1). The leading figure of the era in Greek surgery was Theodoros Aretaios (1829-1893) (Figure 1).

Records are kept today in the Manuscript Department of the National Library of Greece, where documentary research was conducted during the 2023-2024 academic year. A series of surgical operations showed the framework and possibilities of treatment in the practice of orthopedic surgery in 19<sup>th</sup> century Greece. These surgical procedures consisted primarily of amputations, which were performed using Esmarch's technique. That is, an ischemic bandage was used, as massive bleeding during amputation was the fundamental issue that surgeons had to deal with. Amputation functioned as a means of treating serious injuries,



Figure 1. Theodoros Aretaios (1829-1893).

severe infections that caused caries, and bone necrosis or gangrene in the soft tissues that surrounded them. The same fate awaited limbs with tumorous diseases, especially those presenting signs of malignancy. Other procedures were: reduction of fractures and dislocations, bone branching, which meant the excision of all or part of a bone without the simultaneous excision of the surrounding soft tissues, operations to resolve pseudoarthrosis, or treatment of distortion of fractures that had healed. Osteosynthesis, osteocoagulation, sculpting, arthroplasia, arthrodesis, and osteoplasia were procedures absent from the Greek surgery for most of the nineteenth century. However, they were performed gradually from the end of the century forward, as Greek surgeons acquired greater skills by studying abroad, or through practice. Soon, surgeons demonstrated better perception of the creative regeneration of bones and joints. This progress became evident in the surgical textbooks and atlases that were published at the end of the nineteenth and the beginning of the twentieth century, such as the relevant works of Evangelos Kalliontzis (1862-1922) (2), Gerasimos Phokas (1861-1937) (3), and Konstantinos Mermigkas (1874-1942) (4).

The aim of this historical vignette is to elucidate Aretaios' pivotal role in advancing nineteenth-century Hellenic orthopedic surgery, by surveying his extensive patient archives.

## Methods

We conducted research in the Theodoros Aretaios Archives kept today in the Manuscript Department of The National Library of Greece. The information in these archives gave us information about Aretaios' contribution to the foundation of orthopedic surgery in Greece at the beginning of the modern scientific era. Within Theodoros Aretaios' archives, a small number of orthopedic cases treated in his clinic were recorded and saved. These series of cases aroused interest due to the variety of issues described. A total of 22 cases were encountered, consisting of eleven amputations, six dislocations, and five reconstructive operations. These

procedures were performed in both sexes and various age groups. Reconstructive operations were limited to pediatric and adolescent patients.

## Results

Notable cases of upper limb amputations resulted after accidents with dynamite explosions involving civilians. These injuries occurred when patients were either handling the explosive directly, or during close proximity detonation, often self-initiated. None of the incidents were war-related, and they occurred during peacetime activities, primarily involving dynamite use in fishing or construction work. This historical data provides an insight into the etiology of traumatic upper limb amputations in nineteenth-century Greece, highlighting occupational hazards and the negligence of civilians in the use of explosives. Such traumas were classified as transradial or transhumeral.

The earliest case of amputation in Aretaios' archives was dated in 1875, when the amputation was recorded of the left hand of a fisherman from Methana from the level of the wrist (5). This patient was transferred to the clinic five days after his injury, when the destruction of his hands from an explosion was ascertained, as well as the presence of burns on his chest, neck and face. Sepsis was evident in the tissues of the stump, while the patient had a fever of 38.5 °C. The surgical technique employed involved circumferential amputation of the injured stump utilizing two semicircular incisions encompassing the zone of injury, which were subsequently approximated. The archives indicate that one of the amputations was carried out by Theodoros Aretaios' assistant, Mr. Vassiliadis, and the other by Mr. Doukas. The patient exhibited tetanus symptoms on the second postoperative day, characterized by dysphagia and contractions of the masseter and cervical muscles. Treatment was initiated with subcutaneous injections of 20 chlorinating acetaldehyde granules administered every two hours, along with the application of warm covers. Despite intervention, the patient's condition deteriorated, marked by progressive muscle contractions and somnolence. The patient

---

succumbed to the infection on the fourth postoperative day.

An amputation of both forearms was documented in 1879 on a 28-year-old painter who was fishing with dynamite in Faliro. Both his hands were detached from the level of the wrist due to the explosion (6). A similar operation was performed in 1892, when Aretaios decided to amputate the lower third of both forearms of a worker from Kythnos, when cartridges of dynamite exploded prematurely during sewer drilling work (7).

Death from tetanus had already been described as early as 1875, connected with a previous injury. This was the case of a 50-year-old female patient who was shot by a gun carrying spherical projectiles at close range (8). The projectiles caused a penetrating wound to the left breast, and ruptured the tissue of the corresponding arm, shattering the humerus in its lower third. The projectiles became embedded in the soft tissues of the arm. There was no palpable pulse in either the radial or the ulnar artery. Initially, a bandage was applied and ice was placed, as the limb was not cold. The next day the patient developed a fever of up to 38° C, although her fingers and forearm were cold. Aretaios therefore decided to perform upper limb amputation due to severe arm injury. However, although the fever subsided from the first postoperative day, the patient showed symptoms of crackling and signs of universal tetanus. Although she received high doses of chlorinating acetaldehyde, which helped reduce her symptoms, the patient died after 48 hours.

Amputations performed to confront severe infections were also recorded by Theodoros Aretaios. Post-surgery lesions, septic conditions, bacteria and viruses, all contributed to severe limb infections. In 1874, a 30-year-old patient underwent amputation at the level of the middle third of his left forearm (9). Although not mentioned, the execution of the amputation would have been the result of an infection after a firearm injury eight days previously. However, the patient developed osteomyelitis postoperatively. Theodoros Aretaios, therefore, excised an additional seven centimeters of the ulna, which was necrotized due to osteomyelitis. As early as 1873, the case of a 22-year-old

patient with erysipelas throughout the body was recorded, resulting in the decision to amputate the arm (it is not mentioned which arm, or the level of the amputation) due to necrosis (10).

A subsequent case from the same year documented arm necrosis in a 26-year-old farmer. Treatment involved an ischemic bandage and bone preservation rather than amputation, although detailed outcomes were not reported. This approach is aligned with historical management of severe soft tissue infections, where conservative measures were often attempted before resorting to amputation.

Scrofula was an infectious disease that was common at that time, especially in populations living in meagre conditions. In 1875, the case was described of a 23-year-old patient who had been suffering from scrofula for five years, which caused periostitis of the right ulna (NLG 1873: leaf 105). The patient developed decay on the phalanges of the ring finger of the same hand, and this had caused distortion. The surgeon performed dislocation of the finger by creating two lateral flaps. Another case was that of a 17-year-old patient in 1876 (11). This patient had a history of scrofula that caused bone decay without being clearly identified. The cause of bone degeneration could not be determined because of preexisting concomitant osseous pathologies. Four years prior, the patient had presented with a neoplasia that had the characteristics of an oversized spindle formation, extending from the lower third of the arm (it is not specified which) to the middle third of the forearm. Theodoros Aretaios proceeded to amputate at arm level. The patient had a smooth postoperative course apart from postoperative fever. No biopsy report is recorded in the archives.

In 1892, a 37-year-old farmer presented with chronic right ankle pain and progressive swelling. Concurrently, a lymphatic tumor in the left parotid region was noted, which apparently resolved spontaneously. The ankle joint developed fungal growths, which Theodoros Aretaios initially attempted to debride. However, recurrence occurred, with evident cavernous lesions. A below-knee amputation at the distal third of the tibia was

---

performed. This case illustrates the management of chronic ankle infections in the late nineteenth century, highlighting the progression from conservative debridement to amputation when faced with persistent fungal infection. The presence of a concurrent parotid tumor suggests potential systemic involvement, though the relationship between the two conditions remains unclear from the available information (12).

In 1892, Theodoros Aretaios performed a Pirogoff amputation on a 24-year-old male patient presenting with chronic right metatarsal pain and swelling. The patient's history included unsuccessful drainage by a local folk healer, and concurrent sub genital lymphadenopathy. Upon examination, Aretaios observed significant foot edema, a crater-like ulceration on the dorsum with hyperplastic margins, and first toe swelling. Aretaios' differential diagnosis was firstly a malignant neoplasm and secondly a fungal infection. On the basis of the clinical presentation, he concluded it was a fungal infection. Noting the intact ankle joint and tarsal structures, Aretaios opted for a Pirogoff amputation, demonstrating his diagnostic acumen and familiarity with contemporary surgical techniques. This case highlights Aretaios' approach to salvaging a limb, prioritizing minimal functional impact. Postoperative follow-up at day 33 revealed no fever, with only a small, unhealed cavernous tract remaining. The Pirogoff technique, involving calcaneal rotation and tibio-calcaneal arthrodesis, can provide a full weight-bearing stump and allow short-distance ambulation without prosthesis in carefully selected patients (13).

Theodoros Aretaios used a pulley in 1875, having sedated his 55-year-old patient, to reduce an old dislocation of the left arm, as it had occurred more than three months before (14). However, the attempt was unsuccessful, as the head of the arm did not move at all. An incomplete reduction was described in a 17-year-old female patient in 1875, who, after a fall about which no further information is given, presented a dislocation of the right arm from two months earlier. At first, she had resorted to a general practitioner, to no avail, and could not move her arm. It is described how the

arm was hanging downwards and her elbow was close to her chest, and in front of and below the anterior rim of the clavicle there was a spherical prolapse that was considered to be the displaced head of the humerus. It was emphasized that the patient received deep sedation with chloroform, but the attempt was not completely successful. It is stated that the patient left the clinic, without giving any additional information. In contrast, successful results were achieved in 1875 by using the pulley again, in the case of a 50-year-old patient from Psarra (15). Twenty days before this she had developed dislocation of the arm (the side was not noted). The file records that a physician was then called, who allegedly performed the reduction but in fact did not. The surgeon described how the head of the humerus could be seen under the armpit. Due to the age of the injury, he sedated the patient with chloroform to treat the pain during reduction and, using a pulley, he restored the bone to its place, placing a bandage, as is advised for fractures of the clavicle.

Once more, in 1875, the surgeon succeeded in restoring the left arm of an 80-year-old patient, which had been dislocated at shoulder height after a fall, eight days earlier (14). This time he used the Hippocratic Method by placing his own right forearm as a fulcrum under the patient's armpit, and by falling downwards and inwards he succeeded, as he stated "probably", in reducing the dislocation. The same happened to a 22-year-old patient in 1876, who already had a dislocation of his left arm 25 days before, when he fell during a failed attempt to climb onto a moving carriage (16). With the use of a pulley and chloroform sedation, the surgeon succeeded in reducing the arm, as stated, at the first attempt.

Reconstructive procedures were aimed at removing affected areas that had elements of stiffness, to resolve the obstacle to movement, but not to create a new functional connection of the bones. This was the case for most operations in the nineteenth century. In 1874, Theodoros Aretaios treated an ankylosis of the elbow (it is not mentioned whether it was the right or left elbow) of a 24-year-old patient, which was the result of



pseudoarthrosis after being shot in the lower part of the arm (17). The surgeon planned to perform pseudoarthrosis exfiltration. However, during the operation, he noticed that there was decay and part of the joint of the humerus was also fragile, leading to the clearance of both the affected part of this bone, the pseudoarthrosis, and also the ulnar and the radius head. The operation was performed with two incisions on either side of the elbow joint. Apart from the removal of these parts of the bones, there is no mention of attaching materials or other manipulations to the stumps.

Creative reconstructive surgical treatment, but again in the form of cutting small parts of the bones or soft tissue, may be seen in the case of a three-year-old infant female in 1875 (14). The infant, due to a burn in infancy at the age of six months, had a scar on the palmar surface of the ring finger of the left hand that had caused “contraction”, as stated in the file. Theodoros Aretaios excised the scar, and the infant was then considered healed, as it was recorded that the finger was subsequently almost straight. The same core thinking was applied to the case of an 8-year-old child in 1876 who had a supernumerary finger on the outer side of his right thumb (18). It was an apparently incomplete finger, formed with only two phalanges, articulated by an exostosis of the metacarpus, clearly in an ectopic position (hexadactyly). By performing an oval incision, excision of the exostosis was performed, along with the supernumerary finger.

A fourteen-year-old teenager with bilateral congenital clubfoot underwent surgical correction by Theodoros Aretaios, in stages in 1891 and 1892. The right foot was treated first with a wedge-shaped metatarsal resection, involving the cuboid, posterior sphenoid, and partial scaphoid, combined with Achilles tendon division. Postoperatively, the foot was immobilized until healing reportedly occurred within 3-4 months. The patient achieved unassisted ambulation without orthotic devices. The following year, the left foot was addressed. Initially planned as simple ankle projection removal using Nelaton’s technique, the severity of the deformity necessitated a more extensive procedure. This included resection of the

lateral ankle apex, partial articular surface removal of the tibia and scaphoid, and Achilles tendon division. The leg was then immobilized. Postoperative follow-up was documented until day eleven, noting the absence of fever and “very moderate” blood flow without signs of ischemia (19). This case highlights the evolving surgical approaches to severe clubfoot deformities in the late nineteenth century, emphasizing the importance of staged correction and tailored surgical techniques based on intraoperative findings.

## Discussion

The archival evidence from Theodoros Aretaios’ practice reveals a discrepancy between his theoretical knowledge, as presented in his textbooks on surgical techniques (20) (Figure 2) and pathology (21), and his actual clinical practice in orthopedic surgery. While his textbooks describe a wide range of surgical approaches for bone diseases, with limited coverage of spinal surgery, the archived cases demonstrate a narrower scope of procedures. Aretaios’ documented surgeries primarily focused on amputations and dislocation reductions. Reconstructive orthopedics, particularly for foot deformities, were limited in number and employed relatively simple techniques involving bone and tendon excisions to restore joint function. This disparity likely reflects the gap between the advanced orthopedic knowledge available in Europe at the time and the practical limitations of implementing these techniques in Greece in the late nineteenth century. The archives provide valuable insights into the actual state of orthopedic practice in Greece during this period, highlighting the challenges faced in translating theoretical knowledge into clinical application.

Aretaios used the old but well established Hippocratic method for dislocations, a method widely used in European orthopedics (22). Credit for the method of winding a strip of tensile material around the limb (Esmarch’s bandage) is usually given to Johann T. Friederich August von Esmarch (1823-1908), Professor of Surgery at Kiel (23). Meanwhile, studies have revealed that Pirogoff’s

---

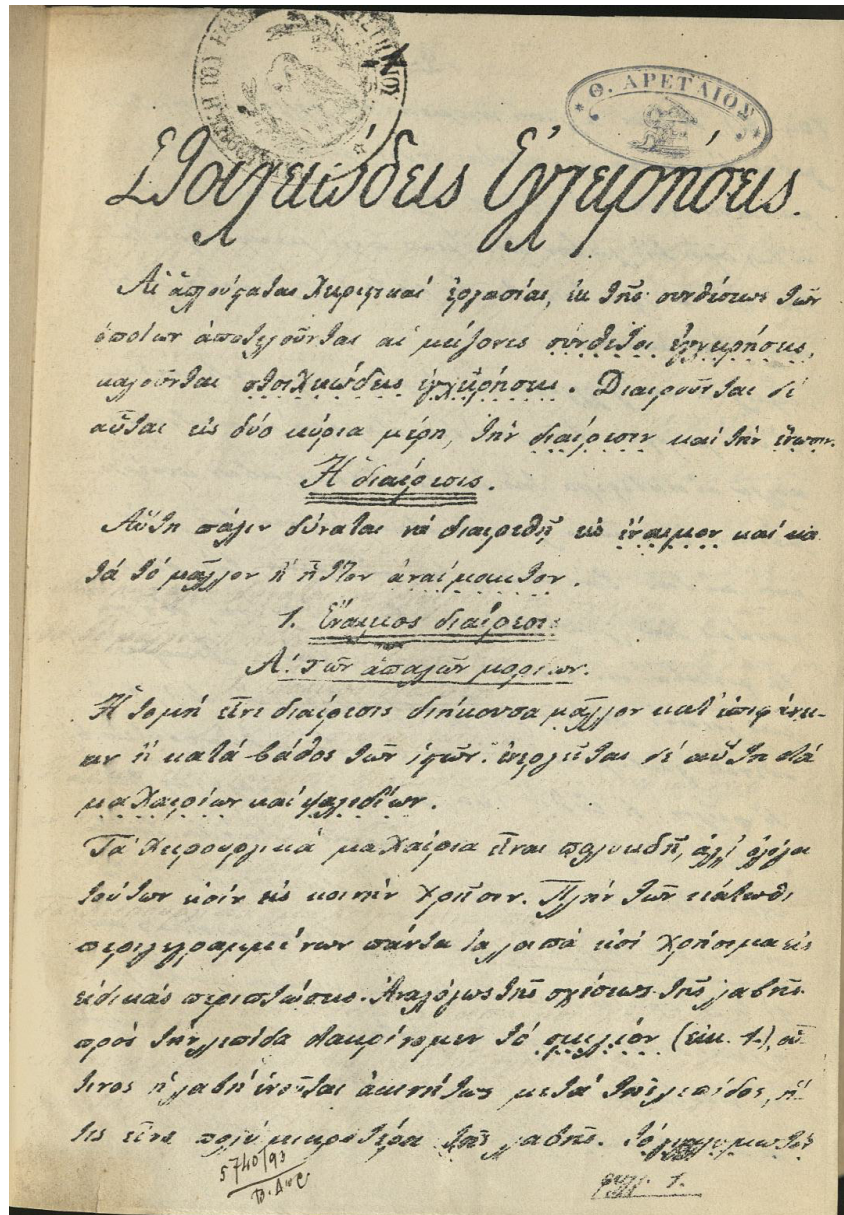


Figure 2. Front page of Theodoros Aretaios's Textbook "Surgery". National Library of Greece Manuscript no. IATP-2594-Q:Sheet 1. Under license of the National Library of Greece.

amputation was more successful, with less post-surgical implications (24). Aretaios was educated in Europe, attending universities in Berlin Vienna and Paris, and was fond of modern techniques and introduced them to Hellenic surgery (25, 26). Theodoros Aretaios' surgical practices were adopted by his successors and students, as evidenced in the medical reports of the clinic under Spyridon

Magginas' directorship (27). Late nineteenth and early twentieth century Greek surgeons, including Professors Evangelos Kalliontzis, Gerasimos Phokas, and Konstantinos Mermigkas (1874-1942), further advanced these techniques by incorporating European training into their practice in Greece (28).

## Conclusion

While Aretaios' published works on surgical techniques and pathology are well-known, this archival study provides novel insights into the actual scope of orthopedic procedures performed in Greece during his time. Despite the limited range of operations, due to contemporary constraints, Aretaios' work laid the foundation for the subsequent development of orthopedic surgery in Greece. It also highlights the discrepancy between theoretical knowledge and practical application in nineteenth-century Greek orthopedic surgery, and underscores Aretaios' pivotal role in advancing the field.

---

### What Is Already Known on This Topic:

*Previous research has primarily focused on Theodoros Aretaios' published textbooks on surgical techniques and pathology.*

### What This Study Adds:

*This article provides detailed examination of Theodoros Aretaios' actual orthopedic surgical practices, based on analysis of his personal patient archives housed in the Manuscript Department of the National Library of Greece.*

---

**Authors' Contributions:** Concept and design: KL and PM; Acquisition, analysis and interpretation of data: KL and PM; Drafting the article: KL, PM, IN and PL-S; Revising it critically for important intellectual content: PL-S, DZ and DM; Approved final version of the manuscript: PM, PL-S, IN, DZ, DM and KL.

**Conflict of Interest:** The authors declare that they have no conflict of interest.

## References

1. Bramis I, editor. The Surgery of the Greeks through the centuries. Athens: Militos; 2019.
  2. Kalliontzis E. Surgery. Athens: Tzakis Editions; 1898-1904.
  3. Phokas G. Leçons de chirurgie orthopédique [Orthopedic Surgery Lessons]. Paris: J.B. Baillièrre et fils; 1895. in French.
  4. Mermigkas K. Surgery. Athens: Makris Editions; 1925.
  5. Theodoros Aretaios. EBE 1873: sheet 103.
  6. Theodoros Aretaios. EBE 1873: sheet 355.
  7. Theodoros Aretaios. EBE 1878: sheet 1a, handwritten number sheet.
  8. Theodoros Aretaios. EBE 1873: sheet 107.
  9. Theodoros Aretaios. EBE 1873: sheet 102.
  10. Theodoros Aretaios. EBE 1873: sheet 100.
  11. Theodoros Aretaios. EBE 1873: sheet 108.
  12. Theodoros Aretaios. EBE 1873: sheet 1, handwritten numbering.
  13. Theodoros Aretaios. EBE 1873: sheet 12, handwritten numbering.
  14. Theodoros Aretaios. EBE 1873: sheet 104.
  15. Theodoros Aretaios. EBE 1873: sheet 105.
  16. Theodoros Aretaios. EBE 1873: sheet 109.
  17. Theodoros Aretaios. EBE 1873: sheet 101.
  18. Theodoros Aretaios. EBE 1873: sheet 106.
  19. Theodoros Aretaios. EBE 1873: sheet 10, handwritten numbering.
  20. Aretaios T. Surgery [Εγχειριστική]. Athens: Private Edition; 1870.
  21. Aretaios T. Surgical Pathology [Χειρουργική Παθολογία]. Athens: Private Edition; 1880.
  22. Hamilton FH. A Practical treatise on fractures and dislocations. Philadelphia: Lea Brothers & Co; 1891.
  23. Klenerman L. The tourniquet manual principles and practice. London: Springer; 2003.
  24. Barnes JK, Woodward JJ, Smart C, Otis GA, Huntington DL. The Medical and Surgical History of the War of the Rebellion (1861-65) (Volume 2, Part 3). Surgical history. Washington: G. P. O; 1883.
  25. Dimitriadis D. The benefactors of universities: Biography with images, National and Kapodistrian University of Athens. Athens: Tarousopoulos Press; 1921.
  26. Kouzis A. History of the Medical School, One Hundred Years. Athens: Pyrsos Press; 1837.
  27. Mpalanos SD. Report of the Surgical Clinic. University of Athens. Academic Year 1892-93. Athens: Fexis Editions; 1895.
  28. Kouzis A. History of the Medical School, One Hundred Years. Athens: Pyrsos Editions; 1937.
-