

Prevention of Oral Injuries during Endotracheal Intubation: Patients' and Anesthesiologists' Perspective

Marta Adam^{1,a}, Dora Arhanić^{1,b}, Iva Z. Alajbeg^{2,c}, Grgur Matolić^{3,d}, Sonja Krofak^{4,e}, Ema Vrbanović Đuričić^{2,f}

¹University of Zagreb School of Dental Medicine, Zagreb, Croatia, ²Department of Removable Prosthodontics, University of Zagreb School of Dental Medicine, Zagreb, Croatia, ³University of Zagreb School of Medicine, Zagreb, Croatia, ⁴University Department of Anesthesiology, Reanimatology and Resuscitation, Clinical Hospital Sveti Duh, Zagreb, Croatia

Correspondence: marta.adam@hotmail.com; Tel: + 385 95 1992300

Received: 2 December 2023; **Accepted:** 20 June 2024

Abstract

Objective. The aim was to design accessible, simple, inexpensive protection for teeth and soft tissues during ETI, compare damage occurrence with and without protection, and investigate post-ETI orofacial pain symptoms. **Materials and Methods.** The selection procedure for adequate protection was carried out after which a reduced elastomer mouthguard was selected. Fifty patients were divided into 2 groups. In the first group, ETI was carried out using a mouthguard, while in the second group it was performed without it. The mouthguard was fabricated by anesthesiologists. After the ETI procedure, the patients and anesthesiologists were asked to complete a survey. **Results.** No difference in intubation severity and time required for intubation between the two groups was present. Seven patients from the non-mouthguard group suffered injuries during the ETI procedure. No injuries were present in the mouthguard group. In 92% of cases anesthesiologists agreed that mouthguards should be used during ETI. However, most of them (96% of cases) agree that the mouthguard should be used only when there is an increased risk of tooth loss and/or tooth damage. There was a significant ETI effect on the emergence of new orofacial pain cases. **Conclusion.** The mouthguard adequately protected dental and soft tissues and did not affect the work of the anesthesiologist. A significantly higher number of patients experiencing temporomandibular joint and masticatory muscles pain after surgery indicates that ETI might be a risk factor for orofacial pain.

Key Words: Mouthguard ■ Endotracheal Intubation ■ Orofacial Pain.

Introduction

Endotracheal intubation (ETI) is a medical procedure in which a tube is placed directly into the trachea. During ETI, complications might occur. Injuries are common, including dental trauma, oropharyngeal laceration, perforation, and other soft tissue injuries (1). The guidelines of the European Resuscitation Council from 2021 state

that endotracheal intubation is not considered a priority in the initial phase, but the use of basic ventilation as the first line of airway control if it is effective. Only expert operators with a high success rate of intubation should perform it, weighing the benefits and risks of the procedure (2). Tooth trauma can range from simple fracture to avulsion. Tooth avulsion is the complete dislocation of the tooth from the alveolus. If this happens, desiccation, ischemia and bacterial contamination of the dental pulp and periodontal ligament begin (3).

Injuries are caused by a laryngoscope, a metal device used to establish the airway. The occurrence of dental injuries is estimated to be between 0.17 and 12.1% (1). The main causes of damage of

^aORCID: 0000-0002-5009-2359

^bORCID: 0000-0002-1889-3930

^cORCID: 0000-0001-8524-5661

^dORCID: 0000-0002-0549-4674

^eORCID: 0000-0002-8369-7637

^fORCID: 0000-0003-2881-851X

dental tissues are the poor condition of the teeth before the ETI procedure, aggressive laryngoscopy, emergency interventions and lack of experience of the doctor (4, 5). Additional causes of damage are difficult airway and reduced visibility (6). Although emergency surgery is not associated with a higher risk of dental trauma compared to elective surgery, the inability to prepare a mouthguard could be associated with the frequency of perioperative injuries (7).

Dental damage is increasingly common as people become older, with the majority of injuries affecting the periodontal ligament. Crown fractures are more prevalent in younger individuals, with the maxillary front teeth being the most commonly impacted (8). To reduce the risk of complications caused by the ETI procedure, various individually made or commercial protective appliances have been used to protect dental tissues (9). The literature states that all preoperative patients who are scheduled to have an ETI procedure should have a preventive dental examination and risk assessment, and those at risk of tooth loss should have a mouthguard made (5).

However, the production of adequate individual mouthguards would require multidisciplinary work between anesthesiologists and dentists and is time-consuming. Also, such mouthguards are extremely expensive (9). Croatia is a country where mouthguards during endotracheal intubation are not a standard practice. Nevertheless, specialists are raising concerns about the number of teeth and soft tissue damage that is happening during the procedure. Dental injuries are the most common reason for complaints against specialists in anesthesiology, resuscitation and intensive care (10). Luxation and avulsion of multiple anterior teeth during elective surgery are risk factors for complaints. Also, the lack of informing the patient about possible postoperative complications is a risk factor for conviction (11). The experience of the anesthesiologist is no guarantee that injuries to the patient's oral cavity will not occur, mainly because injuries most commonly occur due to pathologically weakened teeth and rarely as a consequence of manual manipulation (12).

Another unpleasant complication associated with ETI is postoperative orofacial pain. Strong forces, applied with a laryngoscope or manual manipulation during this procedure, can cause damage to the masticatory system and the appearance of pain. It can result in postoperative symptoms such as difficulty in mouth opening, pain in the temporomandibular joints (TMJ), masticatory muscles, and surrounding structures (13).

This study aimed to assess and compare the occurrence of damage to dental structures and soft tissues during the endotracheal intubation (ETI) procedure among two patient groups: those wearing mouthguards and those without, while also examining the overall occurrence of orofacial pain symptoms following ETI.

Materials and Methods

This was a two-centre interventional study conducted at the Department of Removable Prosthodontics, School of Dental Medicine University of Zagreb and The Clinic for Anesthesiology, Resuscitation and Intensive Care of the Sveti Duh Clinical Hospital.

Mouthguard Selection Procedure

A comparative evaluation of four distinct mouthguard designs was conducted at the Department of Removable Prosthodontics, utilizing two test participants. The aim was to identify a mouthguard design that could be easily communicated to anesthesiologists and utilized in Croatian hospitals. Additionally, the assessment sought to determine if a custom-made silicone splint could meet the necessary retention and stabilization requirements (Figure 1).

1) *Commercial thermoplastic tray*

The thermoplastic tray (*Mammoth XT*[®], *HealthCentre, Berlin, WI, USA*) was placed in hot water and after one minute adapted on the teeth with fingers. Once the material had been set, the tray was returned to the mouth to check retention. All steps were by the manufacturer's instructions.

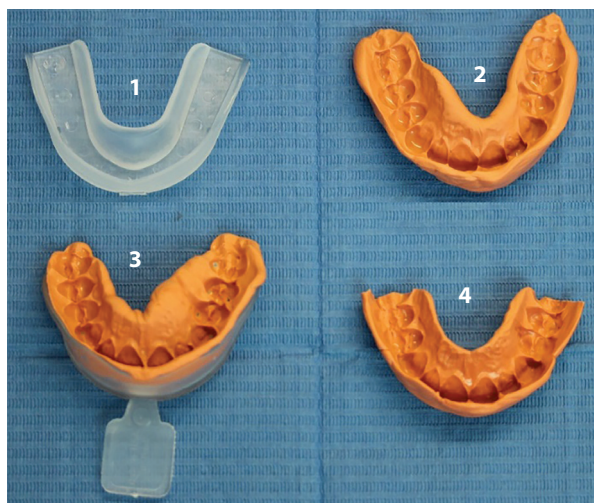


Figure 1. Four types of tested mouthguards (1- commercial thermoplastic tray, 2- custom-made elastomer mouthguard that covered all the teeth of the upper jaw, 3- individualized commercial thermoplastic tray (custom-made elastomer mouthguard placed in a commercial thermoplastic tray), 4- reduced custom-made elastomer mouthguard that covered the frontal teeth up to the second premolar of the upper jaw).

2) ***Custom-made elastomer mouthguard that covered all the teeth of the upper jaw***

The manufacturing process consisted of mixing the base and catalyst vinyl-polysiloxane (3M™ Express™ STD Putty, St. Paul, MN, USA) according to the manufacturer's instructions. The material was adapted to the teeth and surrounding soft tissues. Once the material had been set, the mouthguard was removed from the mouth and reduced with a scalpel as needed. After reduction of the mouthguard outside the mouth, it was returned to the mouth to check retention.

3) ***Individualized commercial thermoplastic tray (custom-made elastomer mouthguard placed in a commercial thermoplastic tray)***

Mixed base and catalyst vinyl-polysiloxane (3M™ Express™ STD Putty) were put in the commercial tray (Mammoth XT®, HealthCentre). Both mixed material and commercial tray were put in the mouth to adapt to the teeth. After the material had been set, the tray was returned to the mouth to check retention.

4) ***Reduced custom-made elastomer mouthguard that covered the frontal teeth up to the second premolar of the upper jaw***

The manufacturing process was the same as in 2); however, the material was adapted to cover the frontal teeth up to the second premolar of the maxilla. All splints had thickness between 3 and 4 mm.

The assessment was carried out in two steps. First, feedback from the patients was collected by the examiners (DA, MA) using a short survey in which retention, comfort, urge to vomit and overall satisfaction with mouthguards were examined on a 5-point Likert scale. The mouthguard that was rated the highest in all categories was considered the best option. Second, an experienced clinician (EV) made a clinical assessment of each mouthguard in the mouth. The mouthguard of choice had to meet the following criteria: i) retention and stability – it had to stand still on the teeth, ii) visibility – its size should not interfere with throat visibility, and iii) comfort – it should not induce the urge to vomit or be causing any discomfort. After both steps were carried out a reduced custom-made elastomer mouthguard was selected as the best option for teeth protection during an ETI procedure. Moreover, the elastomer mouthguard was deemed to be a financially viable solution, presenting no significant challenges for anesthesiologists in its handling.

One study found that the optimal thickness of a mouthguard for proper protection falls within the range of 3-4 mm. It was observed that wearing a mouthguard with a thickness exceeding 4 mm, although potentially providing enhanced protection, was less comfortable for participants (14). Therefore, the mouth guard thickness was determined to be 3 mm.

Sample Size Calculation

The sample size calculation was derived from study, aiming to compare intubation times between patients without a mouthguard and those with one. To detect a difference of 7 seconds with a margin of error of ± 5 seconds, and an allocation ratio of 1:1 between cases and controls, we determined the need to include 26 participants (13 in each group), ensuring a power of 95% at an alpha

level of 0.05. Also, in the same study authors calculated that a sample size of 40 patients in each group would provide a 99% power to detect a 5-second difference in intubation period with and without a mouthguard. If these calculations can be generalized and applied to our sample and design, the size of our sample (N=25 in each group) provided acceptable power to identify tested differences.

Eligibility Criteria

Study participants were patients of the Sveti Duh Clinical Hospital scheduled for a planned procedure under general anesthesia that requires an ETI procedure. To account for potential errors in interpreting the effects of intubation, it's important to note that loosened or previously damaged teeth could inadvertently influence the outcomes. Additionally, adjustments made to the mouthguard itself might pose a risk of injury to teeth that are not in optimal condition. In our study, we specifically excluded patients with compromised dental health to avoid these confounding factors and ensure a more accurate assessment of the impact of ETI. Therefore, only patients with natural teeth in the upper anterior segment were included in the study with at most one prosthetic work in the anterior segment of the upper jaw and the lower anterior teeth present. Excluding criteria were age <18 years, body mass index (BMI)>35 kg/m², Mallampati modified classification>3, interincisal distance <4 cm, complete edentulousness, upper jaw defects, extensive prosthetic works in the area of the upper front teeth, implant-prosthetic works in the anterior segments of the upper jaw, tooth mobility >2mm, lack of teeth in the anterior lower segment (due to disabled measurement of the interincisal opening of the mouth), tumor or carcinoma of the oral cavity, difficult/impossible intubation. The patients were assessed by anesthesiologist and two researchers of the School of Dental Medicine, University of Zagreb (MA, DA). After deciding to include a patient in the study based on inclusion and exclusion criteria, the anesthesiologist responsible for recruiting participants would assign a code to the subjects,

ensuring the anonymity of the participants during data processing. Finally, 50 patients were included in the intervention study and were randomly assigned into 2 groups. The investigator, blinded to the patient statuses, conducted simple randomization using the RAND function within the Excel program.

The first group consisted of 25 patients that underwent the procedure with mouthguard adjusted to their frontal maxillary teeth (mouthguard group), whereas the second group consisted of 25 patients that underwent the procedure without any protection on their teeth (non-mouthguard group) (Figure 2).

Study Protocol

Demographic data (age, sex, height, weight, BMI) were collected for both groups of patients. Two student examiners (DA, MA) educated anesthesiologists on how to assess the dental status of the patients. The condition of the oral cavity was marked as either treated or non-treated. Non-treated implied the presence of large amounts of soft dental plaque, calculus and/or dental caries. After the assessment of the dental status, each patient in the mouthguard group received a mouthguard.

The mouthguard was fabricated by anesthesiologists who were trained by two researchers of the School of Dental Medicine, University of Zagreb (DA, MA). It was adapted to the teeth and surrounding soft tissues as explained previously (Figure 3). After adjusting and checking the mouthguard, the anesthesiologists continued the further usual procedure of preparation for surgery. The mouthguard was removed from the mouth by anesthesiologists after the ETI procedure was completed.

Additional Data Collected

1) Oral aperture size at the maximal possible opening of the mouth

To assess the oral aperture size, patients were asked to open their mouths as wide as possible. Aperture size was measured as the interincisal

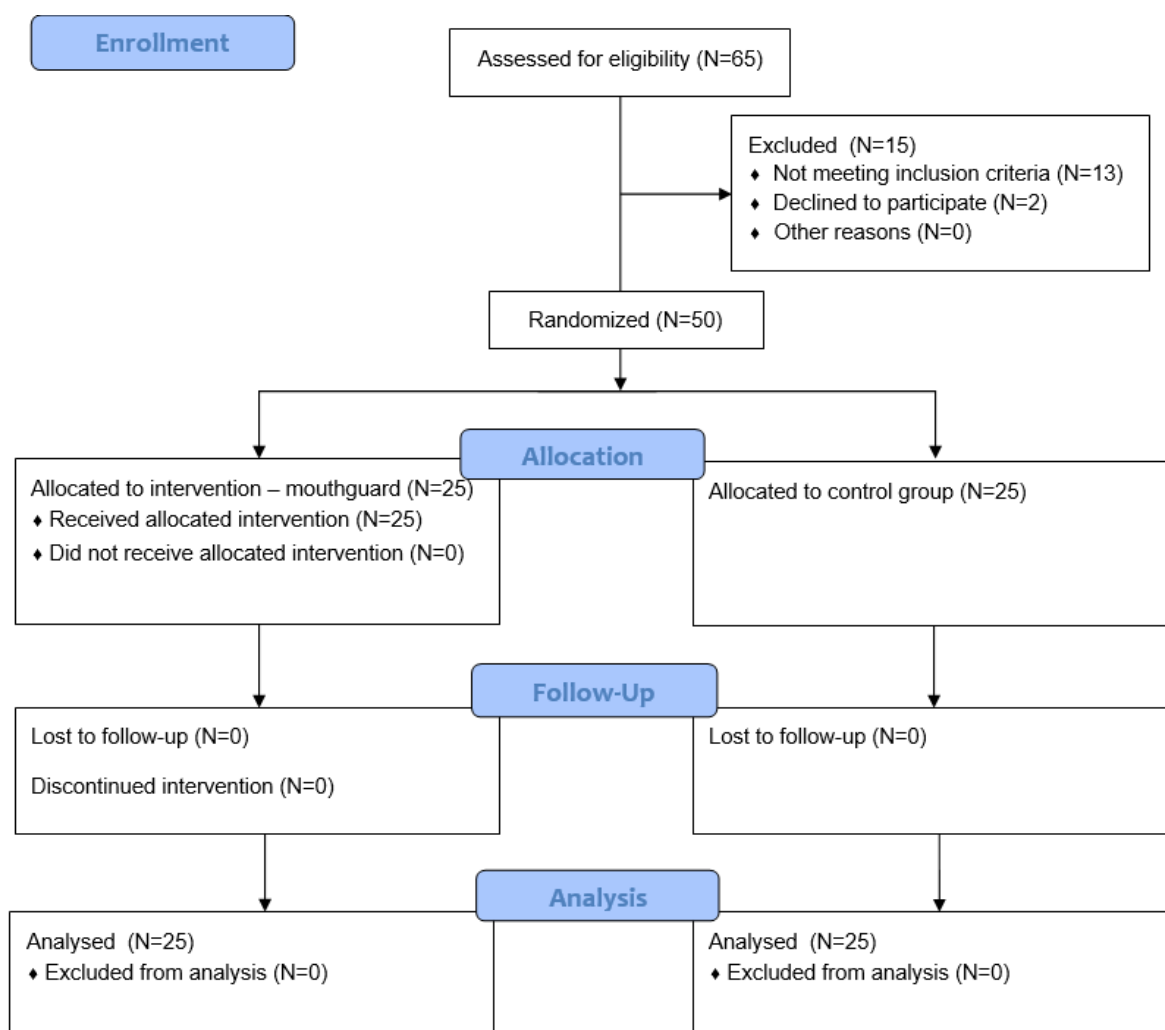


Figure 2. Flow diagram of selection of the participants.

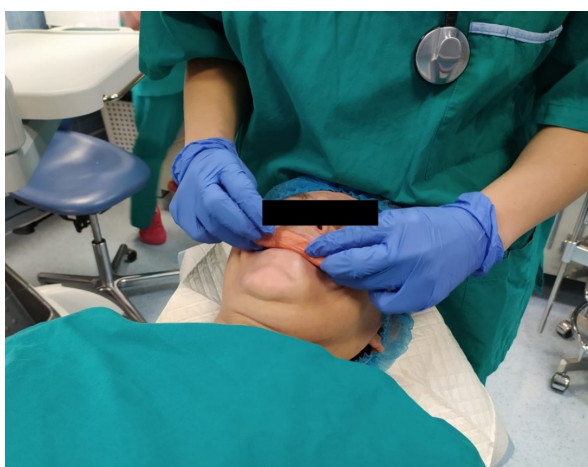

Figure 3. Adaptation of mouthguard before the ETI.

distance between the upper and lower central incisors (in the non-mouthguard and the mouthguard group before the placement of the mouthguard) or as the distance between the lower edge of the mouthguard and the incisal edge of the lower central incisors (in the mouthguard group after the mouthguard placement) (15).

2) *Mallampati modified classification*

Mallampati modified classification was assessed in both groups. Determination of the Mallampati modified classification is a routine part of preoperative anesthesia preparation.

Mallampati modified classification is used to assess the severity of intubation and is determined by the visibility of structures in the oropharynx (16). There are four levels of Mallampati classification which are determined in a sitting position with the head in a neutral position, open mouth, maximally protruding tongue without phonation. In the first degree, the tonsils, palatine arches, soft palate and uvula are visible. In the second stage, the palatine arches, uvula and the upper arch of the pharynx are visible. In the third degree, part of the soft palate and part of the uvula are visible, while in the fourth degree only the hard palate is visible. Grade three and four predictors are for difficult intubation (17).

3) *Required time for intubation*

During the ETI procedure, the time required to perform intubation was monitored (T0 - entry into the oral cavity with a laryngoscope to T1 - inflated balloon on the endotracheal tube), and the time required for intubation was calculated as the difference between T1 and T0 times.

Outcome Assessment

To assess the effectiveness of the mouthguard and the occurrence of orofacial pain after the ETI procedure, the patients were asked to complete a survey within 24 hours following the procedure. The survey consisted of 23 questions, examining awareness of the need to use mouthguards and the occurrence of damage within the oral cavity after the ETI procedure (roughness of teeth, lack of part or all of the tooth, tooth mobility, lip and soft tissue injury and palate injury). In the mouthguard group, the urge to vomit, the existence of discomfort during the mouthguard adjustment procedure and the feeling of security with the mouthguard, were additionally examined.

The patients' survey also examined the occurrence of new symptoms of orofacial pain (primarily symptoms related to temporomandibular disorders - difficulty in mouth opening, pain in the masticatory muscles and temporomandibular

joint). Given our expectation that the mouthguard wouldn't impact orofacial pain, we pooled and analyzed orofacial pain data from both groups, regardless of whether a mouthguard was worn. The intensity of pain before and after the surgery patients recorded on a numerical pain rating scale (NPRS). The NPRS is a subjective measure in which individuals rate their pain on a numerical scale from zero to ten, where zero indicates a pain-free condition and ten the strongest pain possible. Anesthesiologists who carried out the procedure completed a survey to assess the extent to which the mouthguard potentially interfered with their work and/or airway visibility. Also, doctors used the Likert scale (1-completely agree, 2-partially agree, 3-neither agree nor disagree, 4-disagree, 5-least disagree) to assess the difficulty of making the mouthguard, its mobility and whether the mouthguard should become a standard part of the preoperative preparation.

Ethics Statement

All patients were informed in detail about the objectives and course of the research and voluntarily signed informed consent. The Ethics Committee of the Faculty of Dentistry (05-PA-30-XXII-12/2020) and the Ethics Committee of the Sveti Duh Clinical Hospital (01-03-4148/1) approved this research.

Statistical Analyses

Collected data were organized into a database (Excel spreadsheets) and processed using the statistical program IBM SPSS Statistics, 27.0 (Armonk, NY: IBM Corp). Statistical data analysis consisted of descriptive statistics. Also, the Shapiro-Wilk test was used to test the normality of the distribution and appropriate statistical tests were used to test differences between groups. To test for differences in age, height, weight, BMI and oral aperture size between the mouthguard and non-mouthguard groups, a t-test for independent samples was used. The Mann - Whitney U-test was used to examine the differences in time required to perform the ETI procedure between the mouthguard and

non-mouthguard groups. A t-test for dependent samples was used to test the difference in the oral aperture size in the mouthguard group before and after mouthguard adaptation. Due to the simplicity of interpretation and analysis of the results of the Likert scale, the categories “strongly agree” and “partially agree” were interpreted as affirmative answers to the questions asked, while the categories “disagree” and “strongly disagree” were interpreted as negation. The McNamar test was used to determine whether there is a procedure (ETI) effect on the emergence of muscle and joint pain. A value of $P < 0.05$ was considered statistically significant.

The statistician was blinded to group assignment. We hypothesized that there will be differences in the presence of damage to dental structures and soft tissues between participants who underwent an ETI with protection and subjects without any protection to their teeth. Another hypothesis was that there will be more orofacial pain symptoms after the ETI than before.

Results

The demographic data of the patients are shown in Table 1.

A significant difference between the groups was present for the variable “age” ($t = -2.534$, $P = 0.015$). According to the data on the weight of the patients, there were no significant differences between the groups. Also, there was no difference in BMI

($P > 0.05$). Dental status was described as treated in 94% ($N = 47$) of patients and untreated in 6% ($N = 3$) of patients. There was no significant difference in the dental status between the two groups of patients ($P > 0.05$). When the data of the Mallampati classification were analyzed, of the total number of patients, the first degree of Mallampati classification was present in 48% of patients ($N = 24$), the second degree in 40% ($N = 20$) and the third in 6% ($N = 6$). There was no difference in intubation severity between the mouthguard and non-mouthguard group since the distribution of patients in both groups was identical (12 patients in first degree, 10 patients in second degree and 3 patients per group in third degree of Mallampati classification).

A significant reduction in the oral aperture size before (38.52 ± 4.83 mm) and after (36.04 ± 4.68 mm) mouthguard adaptation was present in the mouthguard group ($t = 3.82$, $P < 0.001$). However, there were no differences in the size of the oral aperture between the two groups (non-mouthguard group: 36 ± 10.89 , mouthguard group: 36.04 ± 4.68 ; $t = -0.02$, $P = 0.98$).

Of the total number of patients, 38 (76%) were not aware of the possibility of damage of dental tissues during ETI, while 12 (24%) were. A total of 46 (92%) patients did not know that there is protection for teeth during ETI, while four (8%) knew that there is a way to protect dental tissues during ETI. There was no difference between the

Table 1. Comparison of Data between Groups

Variable	All participants N=50 ($\bar{x} \pm$ SD)	Mouthguard group N=25 ($\bar{x} \pm$ SD)	Non-mouthguard group N=25 ($\bar{x} \pm$ SD)	P^*, \dagger
Age (years)	46.34 (11.12)	42.56 (10.37)	50.12 (10.73)	0.015
Height (m)	171.46 (8.75)	172.6 (9.06)	170.32 (8.45)	0.36
Weight (kg)	77.38 (15.97)	79.6 (14.00)	75.16 (17.73)	0.33
BMI (kg/m ²)	26.18 (4.24)	26.68 (4.09)	25.67 (4.41)	0.41
Aperture size (mm)	37.28 (4.92)	36.04 (4.68)	36 (10.89)	0.98
Time required for ETI (s)	72.10 (70.34)	77.20 (62.55)	67.0 (78.33)	0.25
Gender: male/female (N; %)	17: 34 / 33:66	10: 40 / 15:60	7:28 / 18:72	0.37
Mallampati score 1(%) / 2 (%) / 3 (%)	24/40/6	48/ 40/12	48/40/12	>0.05

N=Number of respondents; SD=Standard deviation; BMI=Body mass index; ETI=Endotracheal intubation; *Differences present between mouthguard and non-mouthguard group, a value of $P < 0.05$ was considered statistically significant; †T-test for independent samples was used.

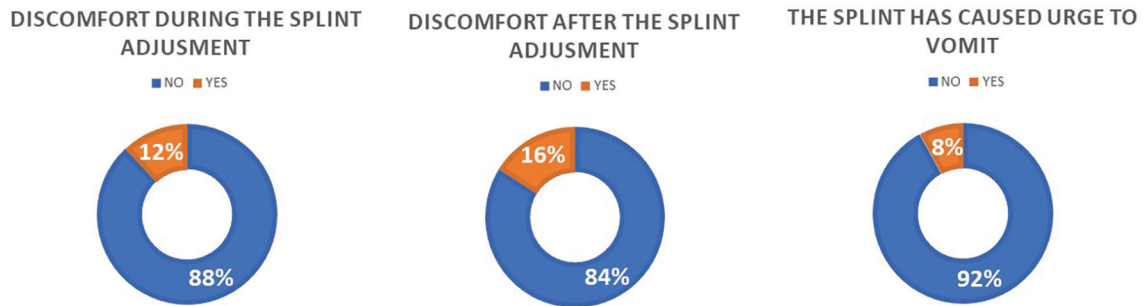


Figure 4. Percentage of discomfort during and after splint adjustment. Orange - YES; Blue - NO.

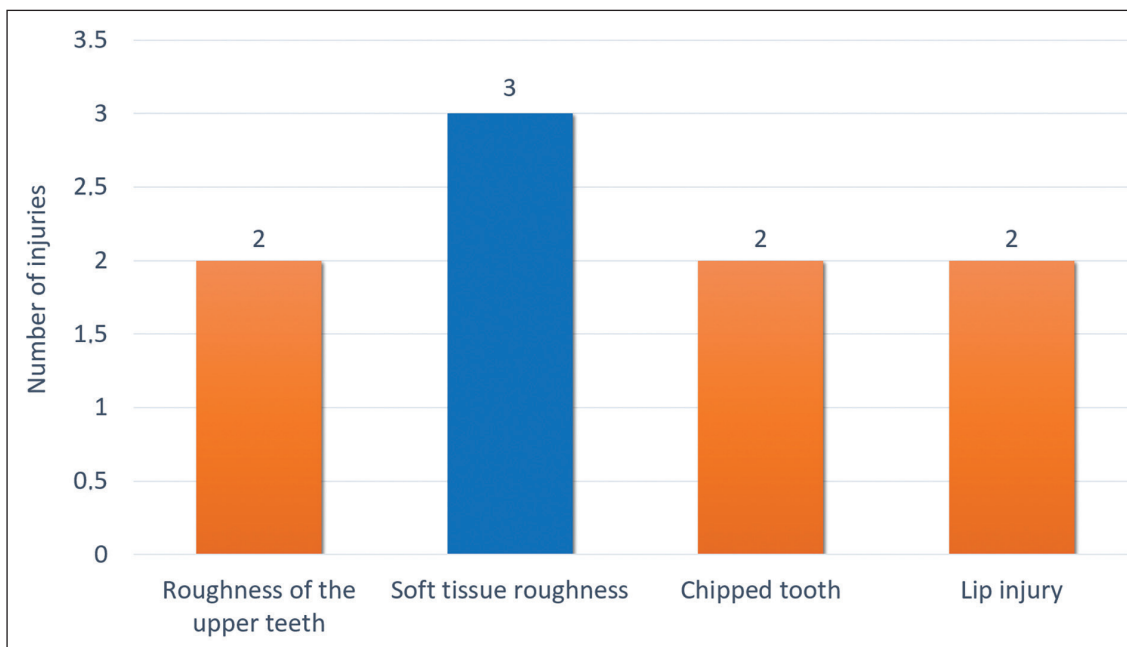


Figure 5. Number of individual injuries present in a total of 7 non-mouthguard patients that experienced injuries.

mouthguard and non-mouthguard groups concerning prior knowledge of damage and protection ($P>0.05$). In the mouthguard group, 22 patients did not feel discomfort while adjusting the mouthguard, while three felt. After adjusting the mouthguard, 21 patients said that the mouthguard did not bother them, while four said it did. Also, after adjustment, 23 patients did not feel the urge to vomit, while two did (Figure 4).

Outcome Data Obtained from Patients

Only two patients reported roughness of the upper teeth after the ETI procedure. They stated that

it was a milder roughness – one respondent reported roughness of all incisors of the upper jaw, while the other felt the roughness of both maxillary central incisors. Both belonged to the non-mouthguard group. The lack of a part of the tooth (chipped tooth) was reported by two patients from the non-mouthguard group. Both patients reported a minor chipping – one subject lacked part of the right central maxillary incisor and the other of the left lower central incisor. Three patients who reported soft tissue damage were from the non-mouthguard group, two with a minor injury, while one stated that he only feels a roughness he doesn't see. Lip injury was present in two patients from

the non-mouthguard group. Both patients reported minor injuries. None of the patients reported tooth mobility or lost a tooth after the ETI procedure. The number of individual injuries in the non-mouthguard group is shown in Figure 5. When the total number of injuries was observed and compared between groups, 7 patients from the non-mouthguard group (28% of the total N=25) suffered injuries during the ETI procedure, of which two patients had a combination of soft tissue and tooth damage. No injuries were present in the mouthguard group.

The cumulative incidence of injury in study population during ETI was 18%. When asked about the fear of injury, after participating in the study, 44 patients (88%) answered that they agree that they fear of tooth damage during ETI (15 patients fully agree, while 29 patients agree to some extent). Forty-eight patients (96%) answered affirmatively to the question “Would you feel more comfortable with the mouthguard during the ETI procedure?” (19 patients fully agree while 29 patients agree to some extent). Both responses did not differ depending on whether the patients had a mouthguard or not ($P>0.05$).

Outcome Data Obtained from Anesthesiologists

The mean time required for ETI was 72.10 ± 70.34 seconds. It took 77.20 ± 62.55 seconds in the mouthguard group and 67.0 ± 78.33 seconds in the non-mouthguard group with no significant difference in the time required to perform the ETI procedure between the groups (Mann – Whitney U-test, $P=0.25$). In 74% (N=21) cases, anesthesiologists stated that they did not agree with the statement that the mouthguard made it difficult to see through the ETI procedure, and in 80% (N=20) cases they stated that the mouthguard did not complicate the ETI procedure. In 88% of cases, when asked about the mobility of the mouthguard, anesthesiologists answered that the mouthguard did not move or was negligibly movable. In 96% of cases, the procedure of making an elastomer mouthguard was not demanding for anesthesiologists. When asked if they thought mouthguards

should be used during ETI, anesthesiologists answered affirmatively in 92% of cases. However, in 96% of cases, they agree that the mouthguard should be used only with indication (increased risk of tooth damage and/or tooth loss).

Outcome Data on Post-operative Orofacial Pain

Seven patients (14%) reported having pain in the muscles before the surgery, whereas five new cases emerged after the surgery. There was a significant ETI effect on the emergence of new muscle pain cases ($P<0.001$). Five patients (10%) reported having joint pain before the surgery, whereas 11 new cases emerged after the surgery). There was a significant ETI effect on the emergence of new joint pain cases ($P<0.001$). Muscle and joint pain did not exceed NPRS=2 which means that minor discomfort was present. None of the patients reported a feeling of a reduced mouth opening.

Discussion

One of the goals of this research was to find appropriate dental protection that anesthesiologists, without the presence of a dentist, could make and use without interference with the ETI. Previous research has shown that the use of individual and commercial mouthguards in ETI reduces the occurrence of dental trauma (18). Although the initial idea was that an individual mouthguard made of thermoplastic material, precisely tailored to the patient's teeth and made in a dental laboratory, would be the best option for protecting dental tissues, such a variant was not acceptable to the Clinical Hospital Sveti Duh's anesthesiologists as they suggested a simpler method without problems such as difficulties in coordinating with dentists and time-consumption. Mentioned problems are often cited in the literature as aggravating factors (5). When considering commercial mouthguards some disadvantages, such as impracticality and bad retention, were observed during this study's mouthguard selection procedure. The impracticality and uneconomical nature of commercial mouthguards despite good protection and

the greatest reduction of the forces were addressed by Monaca et al. (19). Individualized protection made out of high-viscosity elastomer adapted to the most endangered teeth, proved to be an option that meets all the set conditions. It is also a cost-effective option that, with relatively simple training of non-dental staff, can be introduced into the routine procedure of preoperative preparation of patients scheduled for ETI.

Although the oral aperture size significantly decreased in patients after mouthguard adaptation, data analysis showed that there was no difference between the mouthguard group and the non-mouthguard group in the size of the oral aperture. Also, the mouthguard did not lead to a decrease in the visibility of the structures nor to significant increase in the execution time of the ETI. Although the time required for ETI was generally higher in mouthguard group, anesthesiologists did not consider the ETI procedure to be more difficult when the mouthguard was in place. These results prove that a carefully adjusted elastomer mouthguard did not affect the performance of the procedure and in a large percentage did not bother patients (Figure 4). Therefore, we can say that the ETI was successful in both groups demonstrating that our mouthguards were safe to use.

Contrary to our findings, Brosnan et al. noticed a significant difference in the time required for ETI in patients with and without a mouthguard. However, authors distance themselves from the clinical significance of such results, given that the period of adjustment of the mouthguard itself was included in the measurement of the time required for the procedure (20). The protective efficacy of an elastomer mouthguard was demonstrated in this study by comparing the damage of teeth and soft tissues between patients who underwent the procedure with a mouthguard and a group without it. Given that all injuries to teeth and soft tissues happened in the non-mouthguard group we managed to confirm our hypothesis. Interestingly, a total of nine reported injuries of tooth and soft tissue injuries occurred in this study and all injuries occurred in the non-mouthguard group, even the lower central incisor injury. This result can be

explained by the fact that the mouthguard was carefully adapted to the most endangered teeth in the jaw. Also, it may have influenced the work of the anesthesiologist, who was aware of the presence of the mouthguard, to be more careful during the procedure. A more careful work of the anesthesiologist in the mouthguard group would explain the lack of damage to unprotected, mandibular teeth because, as we can see, they can also be damaged.

As far as we know, no study has compared the efficiency of dental protection in two groups during ETI, one with and one without a mouthguard. Lee et al. made individual thermoplastic mouthguards for all patients categorized according to risk factors and the evaluation was performed based on a notation on the patient's complaint after surgery in their medical charts. Also, they did not examine soft tissue injuries or compare the group with the control, so their results cannot be a representation of the real mouthguard efficacy in comparison to a situation without a mouthguard (18).

Despite a relatively high cumulative incidence of 18%, it is important to note that all of the injuries were characterized as minor or mild, and there were no losses of a substantial portion of the tooth or complete tooth loss during the ETI procedure in this study. This may be attributed to the criteria patients had to meet for inclusion in the study. They had their own, mostly rehabilitated teeth, without mobility, without major prosthetic works, and belonged to the low-risk group for dental injuries during ETI (5, 18). Additionally, asking patients to notice potential new injuries due to participation in the study may have led to noticing more than they would have otherwise (such as tooth roughness and lip damage). Both could be injuries they may not have noticed or linked to the event without being prompted.

Because anesthesiologists responded in a high percentage that mouthguard should be used with an indication rather than in all patients, risk assessment for hard dental and soft tissue injuries should become a routine part of the preoperative examination. However, for anesthesiologists to be able to recognize risky situations such as advanced

periodontitis, impaired prosthetic work, or caries-destroyed teeth, they would need to undergo some training. Another option would be to include a dentist in the team which is a potential financial and logistical problem (5, 18, 21). In addition to the poor condition of the oral cavity, the risk of tooth damage is also difficult intubation (5). Risk factors such as reduced mouth opening range and impaired visibility should also become a factor in the decision to use a mouthguard. Patients should always be informed of the risk that exists and be able to decide whether they want a mouthguard or not.

The second hypothesis of our study was that after ETI, a significant number of new symptoms of orofacial pain will appear, which was confirmed by the results. A greater number of patients reported muscle and joint pain after the procedure which showed that ETI affected the emergence of new orofacial pain symptoms. The pain was of low intensity, and this coincides with claims in the literature that say the pain is of lower intensity and mostly short-lived (13). In assessing orofacial pain, categorizing patients based on their groups was unnecessary since the study did not anticipate the mouthguard having any impact on post-operative pain. The sole influencing factor was endotracheal intubation itself. Therefore, it wasn't significant to mask or blind participants regarding the presence or absence of a mouthguard in relation to symptoms of temporomandibular disorder (TMD). It is important to note that for an appropriate assessment, it would be good to measure the extent of postoperative maximal interincisal opening to be able to objectively assess possible functional limitations resulting from the ETI procedure. Given the results obtained, endotracheal intubation could be considered a risk factor for acute orofacial pain. A greater sample size and a medical history that would examine the previous existence of temporomandibular disorders symptoms in more detail, would provide a better insight into this issue. Identifying the risk of subsequent orofacial pain is important to minimize such consequences of ETI.

The clinical implications of our findings are twofold. Firstly, our study emphasizes the critical

importance of implementing dental protection protocols during ETI procedures to mitigate the risk of dental trauma. Dental injuries during ETI can have significant implications for patients, leading to discomfort, pain, and potentially long-term dental issues. By utilizing effective dental protection measures, such as mouthguards, healthcare providers can substantially reduce the likelihood of such injuries, thereby enhancing patient safety and well-being during medical procedures. Secondly, the observation of postoperative orofacial pain following ETI underscores the necessity for comprehensive pain management strategies in patients undergoing such procedures. The occurrence of muscle and joint pain post-ETI, albeit of low intensity, indicates a need for healthcare practitioners to be vigilant in assessing and addressing potential pain symptoms. Comprehensive pain management approaches may include pharmacological interventions, physical therapy modalities, and patient education on pain management techniques. By proactively addressing postoperative pain, healthcare providers can optimize patient comfort, promote faster recovery, and improve overall patient satisfaction with their medical care.

Limitations of the Study

A limiting factor of the study could be the significant difference in age between groups, which is a consequence of random selection and distribution of patients into groups. Additionally, a significant limitation stems from the subjective nature of the results, as both injuries and orofacial pain rely on patients' subjective reports. Having a dentist and an expert in orofacial pain evaluate post-operative outcomes would enhance the validity of the findings. Due to the specific situation caused by the COVID-19 pandemic, it is a great achievement that we managed to educate the staff of the Sveti Duh Clinical Hospital and train them for basic assessment of dental status and making an elastomer mouthguard that proved effective for protecting dental and soft tissues. Last, in this paper, we proposed an effective model of patient protection during ETI.

Conclusion

The placement of a mouthguard can effectively mitigate the side effects associated with endotracheal intubation (ETI) without adding complexity to the anesthesiologists' procedure. We firmly advocate for the incorporation of mouthguards as a standard part of preoperative preparation, particularly in patients with an elevated risk of tooth and soft tissue injuries. A thorough preoperative assessment is essential to evaluate the potential for oral tissue injuries and orofacial pain. The observed increase in postoperative orofacial pain compared to preoperative levels underscores the ETI procedure as a significant risk factor for such symptoms. This highlights the imperative need for proactive measures such as the use of mouthguards to mitigate associated risks and enhance patient comfort and safety.

What Is Already Known on This Topic:

Endotracheal intubation (ETI) is a medical procedure in which a tube is placed directly into the trachea. During ETI, complications might occur. The literature states that all preoperative patients who are scheduled to have an ETI procedure should have a preventive dental examination and risk assessment, and those at risk of tooth loss should have a mouthguard made.

What This Study Adds:

To create adequate protection for teeth and soft tissue and to investigate the occurrence of oral injuries during endotracheal intubation (ETI). Another aim was to assess the occurrence of orofacial pain following ETI.

Acknowledgements: This work is partly supported by the project of the Croatian Science Foundation "Association of gene polymorphisms with temporomandibular disorders" (IP-2019-04-6211, PI: prof. dr. sc. Iva Alajbeg).

Authors' Contributions: Conception and design: IA, DA, MA, EVĐ, SK and GM; Acquisition, analysis and interpretation of data: EVĐ, DA and MA; Drafting the article: EVĐ, DA and MA; Revising it critically for important intellectual content: IA and EVĐ; Approved final version of the manuscript: IA, DA, MA, EVĐ, SK and GM.

Conflict of Interest: The authors declare that they have no conflict of interest.

References

- Galvão AK, Cabral GM, Miranda AF, Baeder FM, Santos MT. Tooth avulsion accidents due to urgent and emergency orotracheal intubation. *Med Oral Patol Oral Cir Bucal*. 2020;25(3):e353-8. doi: 10.4317/medoral.23375.
- Schmutz T, Guechi Y, Le Terrier C, Ribordy V. Emergency endotracheal intubation: best practice versus reality. *Swiss Med Wkly*. 2022;152:w30189. doi: 10.4414/smw.2022.w30189.
- Salarić I, Tikvica Medojević D, Baždarić K, Kern J, Miličević A, Đanić P, et al. Primary School Teachers' Knowledge on Tooth Avulsion. *Acta Stomatol Croat*. 2021;55(1):28-36. doi: 10.15644/asc55/1/4.
- Rosa Maria G, Paolo F, Stefania B, Letizia T, Martina A, Massimiliano D, et al. Traumatic dental injuries during anaesthesia: part I: clinical evaluation. *Dent Traumatol*. 2010;26(6):459-65. doi: 10.1111/j.1600-9657.2010.00935.x.
- Chadwick RG, Lindsay SM. Dental injuries during general anaesthesia: can the dentist help the anaesthetist? *Dent Update*. 1998;25(2):76-8. PMID: 9791212.
- Touman AA, Stratakos GK. Long-Term Complications of Tracheal Intubation. [Internet]. *Tracheal Intubation*. InTech. 2018. doi: http://dx.doi.org/10.5772/intechopen.74160.
- Kotani T, Inoue S, Kawaguchi M. Perioperative Dental Injury Associated With Intubated General Anesthesia. *Anesth Prog*. 2022;69(1):3-9. doi: 10.2344/anpr-68-03-02.
- Vogel J, Stübinger S, Kaufmann M, Krastl G, Filippi A. Dental injuries resulting from tracheal intubation--a retrospective study. *Dent Traumatol*. 2009;25(1):73-7. doi: 10.1111/j.1600-9657.2008.00670.x.
- Nakahashi K, Yamamoto K, Tsuzuki M, Tatebayashi S, Morimoto Y, Hirai K, et al. Effect of teeth protector on dental injuries during general anesthesia [In Japanese]. *Masui*. 2003;52(1):26-31.
- Chidylo SA, Zukaitis JA. Dental examinations prior to elective surgery under anesthesia. *N Y State Dent J*. 1990;56(9):69-70. PMID: 1979158.
- Diakonoff H, De Rocquigny G, Tourtier JP, Guigon A. Medicolegal issues of peri-anaesthetic dental injuries: A 21-years review of liability lawsuits in France. *Dent Traumatol*. 2022;38(5):391-6. doi: 10.1111/edt.12770. Epub 2022 May 31.
- Bory EN, Goudard V, Magnin C. Les traumatismes dentaires lors des anesthésies générales, des endoscopies orales et des sismothérapies [Tooth injuries during general anesthesia, oral endoscopy and vibro-massage]. *Actual Odontostomatol (Paris)*. 1991;45(173):107-20. French. DOI:10.1016/j.annfar.2010.03.019
- Martin MD, Wilson KJ, Ross BK, Souter K. Intubation risk factors for temporomandibular joint/ facial pain. *Anesth Prog*. 2007;54(3):109-14. doi: 10.2344/0003-3006(2007)54[109:IRFFTF]2.0.CO;2.
- Westerman B, Stringfellow PM, Eccleston JA. EVA mouthguards: how thick should they be? *Dent Traumatol*. 2002;18(1):24-7. doi: 10.1034/j.1600-9657.2002.180103.x.
- Türp JC, Lothaller H, Scioscia A. Maximum mandibular mobility in patients with temporomandibular disorders.

- Swiss Dent J. 2020;130(9):668-75. doi: 10.61872/sdj-2020-09-670.
16. Detsky ME, Jivraj N, Adhikari NK, Friedrich JO, Pinto R, Simel DL, et al. Will This Patient Be Difficult to Intubate?: The Rational Clinical Examination Systematic Review. *JAMA*. 2019;321(5):493-503. doi: 10.1001/jama.2018.21413. Erratum in: *JAMA*. 2020;323(12):1194. doi: 10.1001/jama.2020.2069.
 17. Kumar HV, Schroeder JW, Gang Z, Sheldon SH. Mallampati score and pediatric obstructive sleep apnea. *J Clin Sleep Med*. 2014;10(9):985-90. doi: 10.5664/jcsm.4032.
 18. Lee KH, You TM, Park W, Lee SH, Jung BY, Pang NS, et al. Protective dental splint for oroendotracheal intubation: experience of 202 cases. *J Dent Anesth Pain Med*. 2015;15(1):17-23. doi: 10.17245/jdapm.2015.15.1.17. Epub 2015 Mar 31.
 19. Monaca E, Fock N, Doehn M, Wappler F. The effectiveness of preformed tooth protectors during endotracheal intubation: an upper jaw model. *Anesth Analg*. 2007;105(5):1326-32, table of contents. doi: 10.1213/01.ane.0000281909.65963.c8.
 20. Brosnan C, Radford P. The effect of a toothguard on the difficulty of intubation. *Anaesthesia*. 1997;52(10):1011-4. doi: 10.1111/j.1365-2044.1997.221-az0355.x.
 21. Deppe H, Reeker W, Horch HH, Kochs E. Intubationsbedingte Zahnschäden--diagnostische und therapeutische Aspekte [Tooth injury during intubation--diagnostic and therapeutic aspects]. *Anesthesiol Intensivmed Notfallmed Schmerzther*. 1998;33(11):722-5. German. doi: 10.1055/s-2007-994843.
-