

## An Ectopic External Jugular Vein Draining into the Axillary Vein: a Rare Anatomical Variation with Clinical Implications

Dimitra Daskalopoulou<sup>1,2</sup>, Dimosthenis Chrysikos<sup>1</sup>, Amir Shihada<sup>1</sup>, Alexandros Samolis<sup>1</sup>, Nikolaos Pappas<sup>1</sup>, Dimitrios Filippou<sup>1</sup>, Theodore Troupis<sup>1</sup>

<sup>1</sup>Department of Anatomy, Medical School, National and Kapodistrian University of Athens, Athens, Greece, <sup>2</sup>Department of Plastic and Reconstructive Surgery, Naval Hospital Athens, Athens, Greece

**Correspondence:** [ttroupis@med.uoa.gr](mailto:ttroupis@med.uoa.gr); [dimi\\_dsk@yahoo.gr](mailto:dimi_dsk@yahoo.gr); Tel.: + 30 210 7462388; Tel.: + 30 210 7462002-3

**Received:** 11 February 2024; **Accepted:** 25 March 2024

### Abstract

**Objective.** The external jugular vein drains a considerable part of the head and neck and constitutes a vessel implicated in various procedures in the cervical region. The aim of this study is to present an uncommon anatomical variation of the external jugular vein, and discuss the clinical implications of its presence. **Case Report.** We present a rare case of an ectopic external jugular vein terminating into the axillary vein, that we came across during routine dissection of a male cadaver of Greek origin. **Conclusion.** The venous system of the external jugular vein is used during procedures for the treatment of various conditions such as cardiac arrhythmias, hydrocephalus and defects of the head and neck. Hence, encountering the unpredictable course of a variant draining into the axillary vein may complicate these interventions, leading to multiple manipulations and undesirable results. Surgeons should be aware of the alternate anatomy of the venous system of the cervical region, and mindful of the possibility of encountering them.

**Key Words:** External Jugular Vein ▪ Axillary Vein ▪ Anatomical Variants ▪ Cephalic Vein ▪ Jugulocephalic Vein.

### Introduction

The venous drainage of the head and neck is conducted by a subcutaneous and a deep venous system. Specifically, the subcutaneous venous system consists of the external jugular vein and the anterior jugular vein, while the internal jugular vein corresponds to the deep venous system. The external jugular vein (EJV), constituting part of the superficial venous system, drains the blood from the scalp and deep regions of the face (1, 2). The cephalic vein (CV) collects blood from the hand and radial side of the upper limb. The anatomic variability of the EJV correlates clinically with a number of interventional and surgical procedures, highlighting the importance of thorough knowledge and relevant suspicion. The common embryonic genesis with the cephalic vein conjoins with anatomic variants concerning both vessels, and the

sustenance of their interconnection is considered an atavistic feature in human development (3).

We present a rare case of ectopic drainage of the external jugular vein into the axillary vein that was encountered during dissection of a male cadaver of Greek origin, that took place in the Department of Anatomy, Medical School, National and Kapodistrian University of Athens.

### Case Report

During a routine dissection of an 85-year-old Caucasian male formalin-embalmed cadaver, that took place in the Hall of Dissections of the Department of Anatomy, School of Medicine, of the National and Kapodistrian University of Athens for educational and research purposes, an alternate course of the external jugular vein

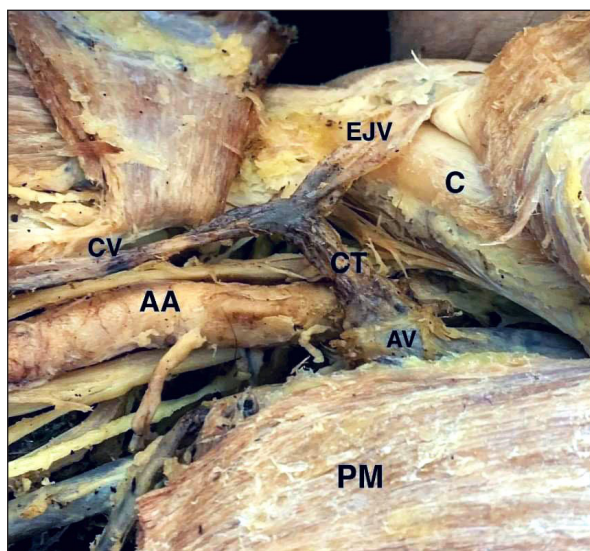


Figure 1. The region of the right deltopectoral triangle. The EJV joins the right cephalic vein with a common trunk (red arrow) that corresponds to a jugulocephalic vein that finally drains into the axillary vein. C=Clavicle; EJV=External jugular vein; CV=Cephalic vein; CT=Common trunk between CV and EJV; AA=Axillary artery; AV=Axillary vein; PM=Pectoralis major muscle.

was encountered, following the preparation of the cervical region and deltopectoral triangle on the right side. Specifically, the EJV descended superficially to the sternocleidomastoid muscle and the midpoint of the clavicle, and joined the right cephalic vein in the deltopectoral triangle, forming a common trunk. This common trunk corresponded to a jugulocephalic vein, which is a remnant that is normally present during the early stages of embryogenesis. The jugulocephalic vein passed under the pectoralis muscle and, crossing over the axillary artery, terminated into the axillary vein. A limitation of this study could be that the left jugular vein was traumatized during central line insertion when the patient was still alive and hospitalized in an intensive care unit, hence, the course of the left jugular vein could not be documented accurately.

## Discussion

The external jugular vein (EJV) is traditionally formed by the junction of the posterior division of the retromandibular vein and the posterior

auricular vein, at the level of the angle of the mandible. The configuration of the EJV takes place in the parenchyma of the parotid gland, and the vessel crosses the sternocleidomastoid muscle in an oblique fashion below the platysma muscle, reaching the midpoint of the clavicle. In the area of the major supraclavicular fossa, the EJV perforates the deep cervical fascia and enters the subclavian vein (1, 3).

The anatomic morphology of the EJV may present with considerable variability regarding its origin, course, tributaries and termination. Fenestrations of the EJV have been reported, i.e. the division of the vessel into two branches, which subsequently reunite to form the same vessel again (4, 5). Duplication of the EJV, on the other hand, is associated with the division of the vessel and the separate terminating points of its ensuing branches (4). Phlebectasia of the vessel has also been documented as well as absence in the form of an undivided retromandibular vein joining the internal jugular vein or as a continuation of the facial vein (4, 6). Russu et al. also presented the rare case of a EJV draining into the IJV (4).

The cephalic vein constitutes the continuation of the lateral end of the dorsal venous arch of the hand over the anatomical snuff box, and runs in the deltopectoral groove. At the deltopectoral triangle, the EJV penetrates the clavipectoral fascia and drains into the axillary vein (1, 3). Variations of the cephalic vein are indeed rare, and include its absence and merger with the subclavian vein, the internal jugular vein, the external jugular vein or the basilic vein (3, 5, 7). Communication of the cephalic vein with the external jugular vein has been recorded, where it assumes the form of the cephalic vein, following a supraclavicular course, or an anastomotic channel, uniting the terminal segment of the cephalic vein with the external jugular vein (3, 7-10). This anastomotic channel correlates to a persistent jugulocephalic vein, which represents a relic pertaining to human ontogenesis (7, 11). Świętoń et al. analysed 324 venographies and came across two cases of a supraclavicular cephalic vein, and 12 cases of persistent supraclavicular jugulocephalic veins (12).

During embryonic development, the superficial veins of the neck emerge from a superficial plexus of capillaries, which merge, creating larger venous stems. Initially the EJV emanates from the plexus and empties into the internal jugular vein (3, 11, 13). The cephalic vein forms as an anastomotic channel of the EJV and joins the axillary vein at a later stage of embryogenesis, while the EJV joins the subclavian vein. Subsequently, the segment crossing the clavicle, namely the jugulocephalic vein, atrophies (11, 13).

Nayak et al. encountered an anatomic variant of the external jugular vein, which communicated with the cephalic vein through an interconnecting vein (1). The communicating vein traversed the superficial surface of the clavicle, whereas the cephalic vein ran between the clavicle and the subclavius muscle, and terminated into the axillary vein (1). In contrast, the common trunk formed by the external jugular vein and the cephalic vein in this case report drained into the axillary vein. There are few reports in the literature describing the configuration of a common trunk between the cephalic vein and the EJV emptying in the subclavian vein (13, 14). Novakov et al. describe the case of a clavicular vein bifurcating into a main branch, which joined the axillary vein under the pectoralis major muscle, and a branch representing a “jugulocephalic anastomosis”, which crossed the anterior surface of the clavicle reaching the EJV (3).

A thorough understanding of the morphology of the superficial veins of the neck is pertinent due to the widespread catheterization of these veins for central venous access, as well as pacemaker and defibrillator implantation (1, 12, 15). An attempt to catheterize cases where the cephalic vein communicates with the external jugular vein could result in ectopic placement of the wire, and the inability to implant the device correctly (12, 14). According to Steckiewicz et al., a supraclavicular course as well as the presence of multiple branches are considered unfavorable for the introduction of leads and subsequent implantation of a device (15). In the case described, the right cephalic vein formed a common trunk with the right external jugular vein, hence, introduction

of a lead into the particular cephalic vein would result in its placement in the external jugular vein. Anatomical variations of the EJV are also relevant for catheterization and the implementation of ventriculoperitoneal shunting for treatment of hydrocephalus (16). Conducting a contrast venography prior to the procedure enables the surgeon to visualize the morphology of the veins and enhances success rates, as well as ensuring time and effort efficiency by reducing unnecessary manipulation.

Orthopedic surgeons treating clavicular fractures with concomitant blood loss should be aware of these anatomic variants since the supraclavicular course of the cephalic or external jugular vein could be interrupted by dislocated clavicular bone fragments and these vessels could be encountered during osteosynthesis (1, 2). Anastasopoulos et al. describe the course of an EJV crossing the lateral third of the clavicle, forming a common trunk with the CV, and draining into the subclavian vein (2).

The EJV may also serve as an alternative for venous outflow in free breast reconstruction, in cases where the internal thoracic vein and the thoracodorsal vein are deemed insufficient for conducting an anastomosis with the donor vessels (4, 17). Additionally, the sustenance of the EJV in the reconstruction of defects of the head and neck provides the possibility of harvesting regional flaps, such as the platysma myocutaneous flap, as the venous outflow of the part of the flap is regulated by the internal jugular vein, whereas the EJV drains the posterior part (18).

### ***Limitation of Case Report***

A limitation of this case report could be that the left external jugular vein was traumatized during central line insertion when the patient was still alive and hospitalized in an intensive care unit. As a result, the left external jugular vein of the cadaver could not be adequately depicted and documented, and no correlation in the morphology of the vessels between the two cervical sides could be established and discussed further.

---

## Conclusion

The widespread use of the superficial veins of the neck for catheterization, venous access and reconstructive purposes renders a thorough knowledge of their configuration and anatomic variability pertinent and necessary for establishment of safe surgical dissection and interventional manipulation. This case of ectopic drainage of the external jugular vein into the axillary vein, after forming a common trunk with the cephalic vein, is extremely rare, and any attempt to utilize these vessels for the treatment of various conditions, such as cardiac arrhythmias, hydrocephalus and defects of the head and neck, may lead to undesirable results and multiple manipulations, should the surgeon proceed without suspecting the presence of anatomical variants. Preoperative imaging of the venous anatomy is suggested in order to increase the level of safety, by designing an anatomical map of the region, and revealing any relevant variants prior to any intervention.

### What Is Already Known on This Topic:

*Various studies have delved into the anatomical variability of the venous system of the head and neck. Moreover, the wide range of interventional and surgical procedures that involve the external jugular vein reflect its clinical significance and impact on the treatment of conditions, such as cardiac arrhythmias, hydrocephalus and defects of the head and neck.*

### What This Study Adds:

*The aim of this report was to present an extremely rare variation of an ectopic external jugular vein draining into the axillary vein, and highlight the possible implications of performing procedures in patients carrying this anatomical particularity. The diversity of these procedures renders knowledge of the morphology of such anatomic variants indispensable for the improvement of safety and to reduce the number of iatrogenic injuries, unnecessary manipulations and inadvertent sequelae.*

**Authors' Contributions:** Conception and design: DD, DC and TT; Acquisition, analysis and interpretation of data: DD, DC and NP; Drafting the article: DD; Revising it critically for important intellectual content: DC, FD, AS and AS; Approved final version of the manuscript: DC, TT.

**Conflict of Interest:** The authors declare that they have no conflict of interest.

## References

- Nayak SB, Soumya KV. Abnormal formation and communication of external jugular vein. *Int J Anat Var.* 2008;1:15-6.
- Anastasopoulos N, Paraskevas G, Apostolidis S, Natsis K. Three superficial veins coursing over the clavicles: a case report. *Surg Radiol Anat.* 2015;37(9):1129-31. doi: 10.1007/s00276-015-1445-4. Epub 2015 Feb 15.
- Novakov S, Krasteva E. Anatomical variants in the termination of the cephalic vein. *Acta Morphol.* 2018;25:3-4.
- Rusu MC, Tudose RC, Vrapciu AD, Toader C, Popescu ŞA. Anatomical Variations of the External Jugular Vein: A Pictorial and Critical Review. *Medicina (Kaunas).* 2023;59(3):622. doi: 10.3390/medicina59030622.
- Vani PC, Rajasekhar SSSN, Gladwin V. Unusual and multiple variations of head and neck veins: a case report. *Surg Radiol Anat.* 2019;41(5):535-8. doi: 10.1007/s00276-019-02203-0. Epub 2019 Feb 18.
- Czyżowski J, Tomaszewski KA, Walocha JA. Jugular phlebectasia presenting as globus pharyngeus. *Folia Morphol (Warsz).* 2013;72(3):278-80. doi: 10.5603/fm.2013.0046.
- Shetty P, Nayak SB, Thangarajan R, D'Souza MR. A rare case of persistent jugulocephalic vein and its clinical implication. *Anat Cell Biol.* 2016;49(3):210-12. doi: 10.5115/acb.2016.49.3.210. Epub 2016 Sep 29.
- Loukas M, Myers CS, Wartmann ChT, Tubbs RS, Judge T, Curry B, et al. The clinical anatomy of the cephalic vein in the deltopectoral triangle. *Folia Morphol (Warsz).* 2008;67(1):72-7.
- Ramírez, JD, Sáenz LC, Rodríguez D, Restrepo AJ, Villegas F. Supraclavicular course of the cephalic vein. *Int J Case Rep Images.* 2014;5(4):281-4.
- Lee WJ, Choi HK, Cho SS, Kim J, Yoon SP. Two different variants of the jugulocephalic vein with supraclavicular course. *Folia Morphol (Warsz).* 2020;79(2):407-10. doi: 10.5603/FM.a2019.0078. Epub 2019 Aug 26.
- Wysiadecki G, Polguy M, Topol M. Persistent jugulocephalic vein: case report including commentaries on distribution of valves, blood flow direction and embryology. *Folia Morphol (Warsz).* 2016;75(2):271-4. doi: 10.5603/FM.a2015.0084.
- Świętoń EB, Steckiewicz R, Grabowski M, Stolarz P. Selected clinical challenges of a supraclavicular cephalic vein in cardiac implantable electronic device implantation. *Folia Morphol (Warsz).* 2016;75(3):376-81. doi: 10.5603/FM.a2015.0125. Epub 2015 Dec 29.
- Araújo RC, Pires LAS, Andrade ML, Perez MC, Filho CSL, Babinski MA. Embryological and comparative description of the cephalic vein joining the external jugular vein: A case report. *Morphologie.* 2018;102(336):44-7. doi: 10.1016/j.morpho.2017.10.002. Epub 2017 Nov 11.
- Kim DI, Han SH. Venous variations in neck region: cephalic vein. *Int J Anat Var.* 2010;3:208-10.
- Steckiewicz R, Świętoń E, Stolarz P, Grabowski M. Clinical implications of cephalic vein morphometry in routine cardiac implantable electronic device insertion. *Folia Morphol (Warsz).* 2015;74(4):458-64. doi: 10.5603/FM.2015.0107.

16. Kano T, Kurosaki S, Iwasa S, Wada H. Migration of a distal ventriculoperitoneal shunt catheter into the internal jugular vein and heart through the external jugular vein: case report. *Neurol Med Chir (Tokyo)*. 2010;50(10):945-8. doi: 10.2176/nmc.50.945.
17. Casey WJ 3rd, Rebecca AM, Smith AA, Craft RO, Buchel EW. The cephalic and external jugular veins: important alternative recipient vessels in left-sided microvascular breast reconstruction. *Microsurgery*. 2007;27(5):465-9. doi: 10.1002/micr.20388.
18. Agarwal A, Schneck CD, Kelley DJ. Venous drainage of the platysma myocutaneous flap. *Otolaryngol Head Neck Surg*. 2004;130(3):357-9. doi: 10.1016/j.otohns.2003.12.005.