

## Entrapment of the Subscapular Artery between the Radial Nerve and the Posterior Wall of the Axilla: An Anatomical Variation with Clinical Significance

Dimitra Daskalopoulou<sup>1,2</sup>, Dimosthenis Chrysikos<sup>1</sup>, Alexandros Samolis<sup>1</sup>, George Tsakotos<sup>1</sup>, Amir Shihada<sup>1</sup>, Maria Piagkou<sup>1</sup>, Theodore Troupis<sup>1</sup>

<sup>1</sup>Department of Anatomy, Medical School, National and Kapodistrian University of Athens, Athens, Greece, <sup>2</sup>Department of Plastic and Reconstructive Surgery, Naval Hospital Athens, Athens, Greece

**Correspondence:** [ttroupis@med.uoa.gr](mailto:ttroupis@med.uoa.gr); [dimi\\_dsk@yahoo.gr](mailto:dimi_dsk@yahoo.gr); Tel.: + 30 210 7462388; Tel.: + 30 210 7462002-3

**Received:** 10 December 2023; **Accepted:** 12 February 2024

### Abstract

**Objective.** The subscapular artery vascularizes a substantial region of the thoracic wall, and the significance of its distribution is well depicted in the diversity of reconstructive procedures that rely on its blood supply. The aim of this study is to present an uncommon anatomical variation of the artery and discuss the clinical implications of its presence. **Case Report.** This case report depicts a rare variant of compression and the kinking of the subscapular artery by the radial nerve on the posterior wall of the axilla that was encountered during dissection of a male cadaver of Greek origin. **Conclusion.** The use of autologous tissues in the reconstruction of defects and treatment of lymphedema is expanding, so the need to establish safer surgical dissections is also becoming more apparent. The case of entrapment of the subscapular artery by the radial nerve is extremely rare, however, utilizing tissues perfused by this artery for reconstructive purposes could potentially be futile and unsuccessful due to the inadequate blood supply or vessel thrombosis. Hence, the surgeon should adapt the treatment plan according to preoperative findings, as the presence of anatomical variants should always be suspected.

**Key Words:** Subscapular Artery ■ Artery Entrapment ■ Kinking of Artery ■ Radial Nerve ■ Reconstructive Surgery.

### Introduction

The subscapular artery constitutes the largest branch of the axillary artery and provides the blood supply to the posterior wall of the axilla, as well as the posterior scapular region (1, 2). The significance of the distribution of the subscapular arterial system has been well established, considering the diversity of surgical procedures of a reconstructive nature that rely on its blood supply. The radial nerve originates from the posterior cord of the brachial plexus and passes through the lower triangular interval between the teres major muscle, the long head of the triceps brachii muscle, and the shaft of the humerus, accompanied by the profunda brachii artery. In relation to the subscapular artery, in most cases the radial nerve runs anterior to the artery (3, 4).

Knowledge of topographical anatomy and clinically relevant arterial and neural variations of the axillar region is crucial to improve safety in surgical procedures involving the vascularized region. The increase in the number of reconstructive procedures using autologous tissues reflects the necessity to minimize the risk of inadvertent complications. A prerequisite for successful transplantation of autologous tissues is the sustenance of blood flow through the pedicle of the flap. Hence, disruption of the longitudinal direction of the vessels, such as kinking of the vessels, could have devastating implications as a result of impaired blood supply.

The aim of this study is to present a rare case of entrapment of the subscapular artery by the radial nerve on the posterior wall of the axilla with subsequent kinking of the vessel, and discuss its clinical implications. This uncommon anatomical

variation was encountered during routine dissection of a male cadaver of Greek origin for educational and research purposes.

## Case Report

The anatomic variation in our study was depicted in a formalin-fixed 85 year old male cadaver of Greek origin. The cadaveric dissection took place in the Dissections Hall of the Department of Anatomy, School of Medicine, National and Kapodistrian University of Athens. The axillar region of the cadaver was dissected and cleaned by the contributors, and the anatomical specimen was photographed. While proceeding with the routine dissection of the right axillary region of the Greek male cadaver, we encountered the variation of entrapment of the right subscapular artery by the radial nerve. After preparation and release of the vessel from the nerve, we detected an

area of kinking of the subscapular arterial trunk, which corresponded to the point of compression by the radial nerve. The artery presented no further anatomical variations and followed its usual course, dividing into the thoracodorsal and circumflex scapular arteries. The specific distribution and compression of the subscapular artery by the radial nerve were encountered bilaterally. The left subscapular artery presented with an analogous area of kinking as a result of entrapment by the left radial nerve.

## Discussion

Traditionally, the subscapular artery originates from the posterior surface of the third part of the axillary artery, then runs along the posterior wall of the axilla, following the inferior margin of the subscapularis muscle for a short distance, and bifurcates into its two terminal branches, the

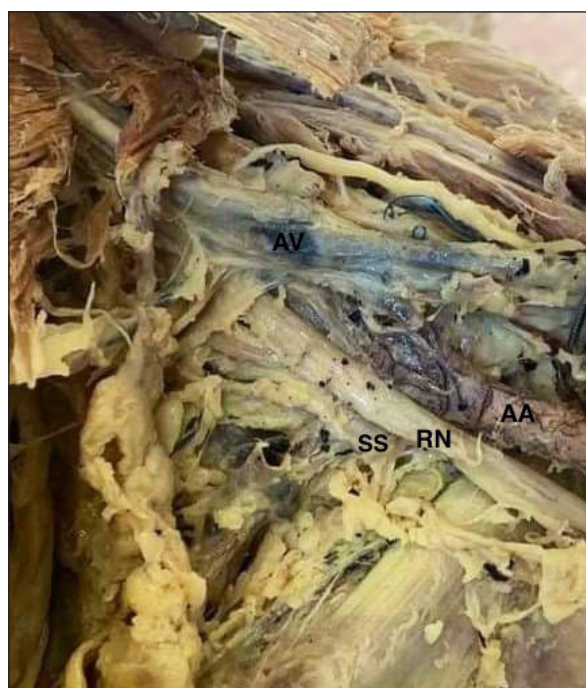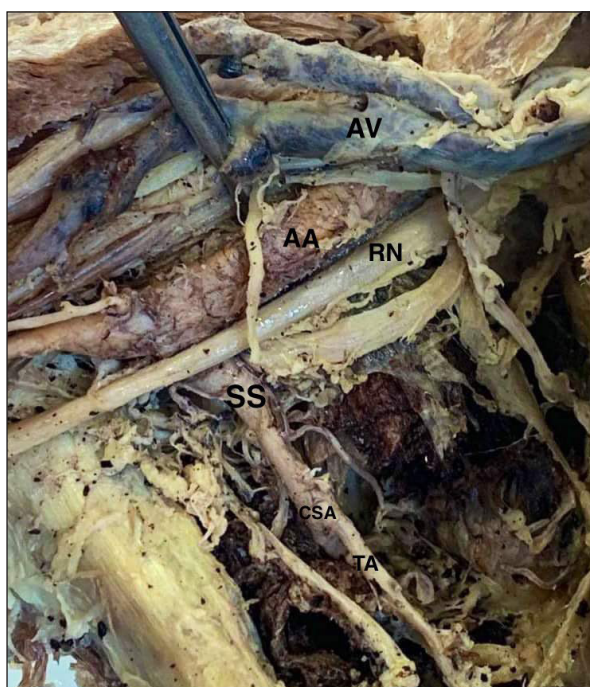


Figure 1. Right axillary region. The right radial nerve compresses the origin of the right subscapular artery from the axillary artery. An area of kinking is detected on the subscapular arterial trunk, corresponding to the point of compression by the radial nerve. AV: Axillary vein, AA: Axillary artery, SS: Subscapular artery, RN: Radial nerve, CSA: circumflex scapular artery, TA: Thoracodorsal artery. Figure 2. Left axillary region. The left radial nerve compresses the origin of the left subscapular artery from the axillary artery. An area of kinking is detected on the subscapular arterial trunk. AV: Axillary vein, AA: Axillary artery, SS: Subscapular artery, RN: Radial nerve.

circumflex scapular artery and the thoracodorsal artery (2).

The branches of the circumflex scapular artery provide the blood supply for regional flaps (scapular and parascapular flaps), which are widely used in the reconstruction of simple and complex defects. Musculocutaneous flaps, as well as perforator flaps based on the thoracodorsal vessels can also be elevated with the purpose of reconstructing defects of areas of the head and neck, thorax and axilla, as well as distant regions, using microsurgical techniques (5). Olinger et al. investigated the branching morphology of the subscapular, lateral thoracic and posterior circumflex humeral arteries, and their relationship to the radial and axillary nerve. According to this study, in 88.5% of cases where the lateral thoracic artery and subscapular artery presented with a classic branching pattern, the two nerves traveled posterior to the lateral thoracic artery, while the radial nerve ran anterior to the subscapular and the axillary nerve posterior to the artery. In 9.2% of cases both nerves were detected posterior to the two arteries, and in 2.3% of the specimens both nerves traveled posterior to the lateral thoracic artery, but anterior to the subscapular artery (4).

Previous studies have reported different variations of the subscapular artery. Lhuairé et al. proposed a classification concerning the subscapular pedicle variations. Three types of arterial variation were presented, where specifically type Ia involved the classic pattern of the artery originating from the inferior border of the axillary artery and bifurcating into two terminal branches. Arteries associated with the type Ib classification presented with a similar pattern, originating, however, from a proximal point of the axillary artery, while type II was associated with the absence of the subscapular artery (6). Cases have also been presented where the subscapular artery terminates into three branches, namely the thoracodorsal, the circumflex scapular, and the posterior circumflex humeral arteries (7, 8). This branching pattern was observed in 12% of cases in a study conducted by Olinger et al. Dimovelis et al. reported a case of tetrafurcation of the subscapular artery. Variations

concerning the origin of the subscapular artery have also been reported. According to Samuel et al. the subscapular artery may also emanate from a common trunk, branching out into the posterior circumflex humeral, radial collateral, middle collateral and superior ulnar collateral arteries (9). A common trunk involving the profunda brachii, subscapular, anterior and posterior circumflex humeral arteries and the superior ulnar collateral artery has also been described (10).

In the context of its relationship with the brachial plexus, entrapment of the subscapular artery between the two roots of the median nerve has also been observed (1, 11). Kuwar et al. described a case where the subscapular artery was encircled by two roots emanating from the posterior cord of the brachial plexus, forming the radial nerve (3). Mistry et al. observed a variant of the radial nerve, which split into two roots following its formation, and encased the subscapular artery (12). To the best of our knowledge no case of compression of the subscapular artery by the radial nerve with subsequent kinking of the artery has been reported previously in the literature.

Successful upper limb revascularization has been documented using parts of the subscapular arterial system as arterial grafts and replacing damaged segments of the arterial systems of the upper extremity (13, 14). According to Malikov et al., patients with critical limb ischemia and large tissue defects may be treated by harvesting a subscapular artery flow-through muscle flap, using the subscapular artery as an arterial graft, and a serratus anterior muscle flap supplied by the distal branch of the thoracodorsal artery to cover the deficit (15). The utility of the subscapular arterial system in the creation of conduits for revascularization has also been established in coronary bypass surgery in cases where the revascularization cannot be achieved using other conventionally used arterial conduits (16-19).

The terminal branches of the subscapular vessels demarcate the posterior limit of axillary lymph node dissection, and they also constitute the pedicles of various regional flaps that can be harvested for reconstructive purposes, such as the latissimus

dorsi and the scapular flaps. The longitudinal direction of the vessels is a prerequisite for successful autologous reconstruction, as twisting and kinking of the pedicle may impair blood flow. According to studies, kinking of the vascular pedicle constitutes the most common cause of vessel occlusion and flap failure (20, 21). An experimental study on rats demonstrated that acute angulation of the vascular pedicles may obstruct blood flow increasing the risk of tissue ischemia and flap failure (22). Vascularized lymph node transfer (VLNT) has, additionally, emerged as a feasible treatment option in cases of lymphedema occurring after lymph node dissection, as the ability of the lymphatics to regenerate after VLNT has been well investigated. Patients suffering from lymphedema previously had to endure conservative decongestive therapies or debulking procedures to relieve their symptoms. Hence, the development of techniques that aim to restore the function of the lymphatic system has revolutionized the treatment of these patients and improved their quality of life. Lymph node flaps supplied by the thoracodorsal artery can be harvested and transplanted in the affected region, while the use of a latissimus dorsi flap and a thoracodorsal artery perforator flap with lymph node transfer has also been introduced as a tool for treating lymphedema (23-26). The thoracodorsal vessels are also used as recipient blood vessels in autologous breast reconstruction, as well as reconstruction of defects of the thoracic wall using microsurgical techniques. Therefore, familiarity with the anatomical variations and branching patterns of the subscapular artery and its spatial relationship to the nerves of the brachial plexus is indispensable for safe surgical dissection and harvesting of flaps.

## Conclusion

The widespread use of autologous tissues in the reconstruction of defects renders the optimization of surgical dissections necessary, thus surgeons should be aware of alternate anatomies of the vessels and neural structures of the axillar region before proceeding with any intervention in order to

prevent postoperative complications as a result of ischemia of the tissues. This case of entrapment and kinking of the subscapular artery by the radial nerve on the posterior wall of the axilla is extremely rare. However, an attempt to utilize the tissues supplied by this artery for reconstructive purposes could potentially lead to flap loss due to inadequate blood supply or vessel thrombosis, if the surgeon does not suspect the presence of an anatomical variant. Preoperative imaging of the arterial anatomy is suggested to increase the level of safety by revealing unpredictable variations and establishing a more familiar path for the surgeon during dissection.

---

### What Is Already Known on This Topic:

*The anatomical variability of the subscapular artery has been elucidated in various case reports. Moreover, the clinical significance of its variants has been depicted in several surgical fields, especially in procedures involving the reconstruction of defects, as well as the treatment of lymphedema.*

### What This Study Adds:

*The case of entrapment of the subscapular artery by the radial nerve with subsequent kinking of the vessel has not been reported in previous anatomical studies. The presence of this particular variation could negatively influence the outcome of reconstructive procedures involving the subscapular artery, thus preoperative imaging of the axillar region could assist in avoiding the use of tissues of this area and turning attention to alternative and more viable reconstructive options.*

---

**Authors' Contributions:** Conception and design: DD, DC and TT; Acquisition, analysis and interpretation of data: DD, DC and MP; Drafting the article: DD; Revising it critically for important intellectual content: DC, GT, AS and AS; Approved final version of the manuscript: DC and TT.

**Conflict of Interest:** The authors declare that they have no conflict of interest.

## References

1. Naveen K, Satheesha NB, Ashwini AP, Suhani S, Mamatha H. Subscapular arterial entrapment between two roots of median nerve with concurrent higher division of radial nerve– A case report. *J Surg Acad.* 2013;3(2):86-8.
  2. Drake RL, Vogl AW, Mitchell AW. *Gray's Anatomy for Students.* 4th ed. Philadelphia: Churchill Livingstone/Elsevier; 2019.
  3. Kuwar RB, Bilodi AK. Claspings of subscapular artery by radial nerve. *Kathmandu Univ Med J (KUMJ).* 2007;5(2):253-5.
-



4. Olinger A, Benninger B. Branching patterns of the lateral thoracic, subscapular, and posterior circumflex humeral arteries and their relationship to the posterior cord of the brachial plexus. *Clin Anat.* 2010;23(4):407-12. doi: 10.1002/ca.20958.
  5. Zenn M, Jones G. *Reconstructive Surgery: Anatomy, Technique, and Clinical Application.* 1st ed. New York: Thieme Publishers; 2012.
  6. Lhuair M, Hivelin M, Derder M, Hunsinger V, Delmas V, Abrahams P, et al. Anatomical variations of the subscapular pedicle and its terminal branches: an anatomical study and a reappraisal in the light of current surgical approaches. *Surg Radiol Anat.* 2019;41(4):385-92. doi: 10.1007/s00276-018-2161-7.
  7. Lengele B, Dhém A. Unusual variation of vasculonervous elements of the human axilla report of three cases. *Arch Anat Histol Embryol (Strasb).* 1989;72:57-67.
  8. Durgun B, Yucel AH, Kizilkanat ED, Dere F. Multiple arterial variation of the human upper limb. *Surg Radiol Anat.* 2002;24(2):125-8. doi: 10.1007/s00276-002-0011-z.
  9. Dimovolis I, Michalinos A, Spartalis E, Athanasiadis G, Skandalakis P, Troupis T. Tetrafurcation of the subscapular artery. Anatomical and clinical implications. *Folia Morphol.* 2017;76(2):312-5. doi: 10.5603/FM.a2016.0057.
  10. Venieratos D, Lolis ED. Abnormal ramification of the axillary artery: subscapular common trunk. *Morphol.* 2001;85(270):23-4.
  11. George BM, Nayak S, Kumar P. Clinically significant neurovascular variations in the axilla and the arm – a case report. *Neuroanat.* 2007;6(1):36-8.
  12. Mistry P, Rajguru J, Dave M. Unique variation of the radial nerve involving the subscapular artery- A case report. *Int J Anat Radiol Surg.* 2020;9(3):AC01-2. doi: 10.7860/IJARS/2020/44494:2552.
  13. Masden D, Seruya M, Higgins J. A systematic review of the outcomes of distal upper extremity bypass surgery with arterial and venous conduits. *J Hand Surg.* 2012;37(11):2362-7. doi: 10.1016/j.jhsa.2012.07.028.
  14. Valnicek S, Mosher M, Hopkins J, Rockwell B. The subscapular arterial tree as a source of microvascular arterial grafts. *Plast Reconstr Surg.* 2004;113(7):2001-5. doi: 10.1097/01.prs.0000122235.09892.da.
  15. Malikov S, Magnan PE, Champsaur P, Casanova D, Branchereau A. Subscapular artery Y-shaped flow-through muscle flap: A novel one-stage limb salvage procedure. *J Vasc Surg.* 2008;48(1):159-66. doi: 10.1016/j.jvs.2008.02.023.
  16. Yaginuma G, Sakurai M, Meguro T, Ota K. Thoracodorsal artery as a free arterial graft for myocardial revascularization. *Ann Thorac Surg.* 2001;72(3):915-6. doi: 10.1016/s0003-4975(00)02413-9.
  17. Šimić O, Zambelli M, Zelić M, Pirjavec A. Thoracodorsal artery as a free graft for coronary artery bypass grafting. *Eur J Cardiothorac Surg.* 1999;16(1):94-6. doi: 10.1016/s1010-7940(99)00144-x.
  18. Moro H, Ohzeki H, Hayashi JI, Eguchi S, Tamura Y, Funazaki T, et al. Evaluation of the thoracodorsal artery as an alternative conduit for coronary bypass. *Thorac Cardiovasc Surg.* 1997;45(6):277-9. doi: 10.1055/s-2007-1013749.
  19. Mills N, Dupin C, Everson C, Leger C. The Subscapular Artery: An alternative conduit for coronary bypass. *J Card Surg.* 1993;8:66-71. doi: 10.1111/j.1540-8191.1993.tb00576.x.
  20. Williams J, French R, Lalonde D. Why do free flap vessels thrombose? Lessons learned from implantable Doppler monitoring. *Can J Plast Surg.* 2004;12(1):23-6. doi: 10.1177/229255030401200112.
  21. Khouri RK. Avoiding free flap failure. *Clin Plast Surg.* 1992;19(4):773-81.
  22. Biglioli F, Rabagliati M, Gatti S, Brusati R. Kinking of pedicle vessels and its effect on blood flow and patency in free flaps: an experimental study in rats. *J Craniomaxillofac Surg.* 2004;32(2):94-7. doi: 10.1016/j.jcms.2003.12.001.
  23. Inbal A, Teven C, Chang D. Latissimus dorsi flap with vascularized lymph node transfer for lymphedema treatment: Technique, outcomes, indications and review of literature. *J Surg Oncol.* 2016;115(1):72-7. doi: 10.1002/jso.24347.
  24. Becker C, Vasile J, Levine J, Studinger R, Chen C, Riquet M. Microlymphatic surgery for the treatment of iatrogenic lymphedema. *Clin Plast Surg.* 2012;39:385-98. doi: 10.1016/j.cps.2012.08.002.
  25. Gerety PA, Pannucci CJ, Basta MN, Wang AR, Zhang P, Mies C, et al. Lymph node content of supraclavicular and thoracodorsal-based axillary flaps for vascularized lymph node transfer. *J Vasc Surg Venous Lymphat Disord.* 2016;4(1):80-7. doi: 10.1016/j.jvsv.2015.06.004.
  26. Gazyakan E, Bigdeli AK, Kneser U, Hirche C. Chimeric thoracodorsal lymph node flap with a perforator-based fasciocutaneous skin island for treatment of lower extremity lymphedema: A case report. *Microsurgery.* 2020;40(7):792-6. doi: 10.1002/micr.30584. Epub 2020 Apr 7.
-