

Spontaneous Bleeding in Vestibular Schwannoma in Patients on Oral Anticoagulant Therapy: Report of Two Cases and Review of Literature

Mirza Pojskić^{1,2}, Domagoj Gajski³, Alisa Arnautović⁴, Kenan I. Arnautović^{5,6}

¹Department of Neurosurgery, University of Marburg, Marburg, Germany, ²Faculty of Medicine, Josip Juraj Strossmayer University, Osijek, Croatia, ³Department of Neurosurgery, University Clinical Hospital Center "Sestre Milosrdnice," Zagreb, Croatia, ⁴Department of Surgery, Emory University School of Medicine and Health Sciences, Atlanta, GA, USA, ⁵Semmes Murphey Neurologic & Spine Institute, Memphis, TN, USA, ⁶Department of Neurosurgery, the University of Tennessee Health Science Center, Memphis, TN, USA

Correspondence: *kenanarnaut@yahoo.com*; Tel.: +1 901 5222671

Received: 14 August 2023; **Accepted:** 19 December 2023

Abstract

Objective. Anticoagulant therapy is a risk factor for repeated intratumoral hemorrhage and acute enlargement of a vestibular schwannoma (VS) with neurological deficits. Therefore, we describe two cases of patients on oral anticoagulant therapy with intratumoral hemorrhage in which anticoagulant therapy prior to surgical resection was discontinued. We also discuss other similar cases from the literature since this is a rare event. **Case Reports.** We described the two cases of intratumoral hemorrhage in acoustic neurinoma and conducted a literature review of similar cases of patients with intratumoral hemorrhage in acoustic neurinoma who were also on oral anticoagulants. Both patients presented with CN-VII palsy prior to surgery; both also fully recovered after surgery except for hearing loss on the tumor side. Our literature review found 50 cases of VS (reported as vestibular schwannomas in the literature) with intratumoral hemorrhage. From this total, 11 patients used oral anticoagulant therapy with reported poor outcomes and high mortality; 9 of these 11 cases were reported in the past 20 years. The incidence is expected to rise due to increased use of anticoagulant therapy due to onset of atrial fibrillation, atherosclerosis, and thromboembolism from longer human lifespan. **Conclusion.** Anticoagulant therapy represents a risk factor for intratumoral hemorrhage and acute enlargement of VS tumor mass with neurological deficits.

Key Words: Anticoagulants ■ Hemorrhage ■ Neuroma ■ Acoustic ■ Risk Factors ■ Vestibular Schwannoma.

Introduction

Vestibular schwannomas (VS), represent 80% of cerebellopontine angle (CPA) tumors and roughly 8% of all intracranial neoplasms (1). These types of tumors commonly present with slow and progressive hearing loss, tinnitus, disequilibrium, and vertigo (1). Intratumoral hemorrhage (ITH) is a potentially devastating development associated with VSs due to the close proximity of the brainstem, the confined anatomy of the posterior fossa, and the potential for acute fourth ventricular obstruction. Patients may deteriorate rapidly, and in some instances the tumor can become sizable and potentially life-threatening (2-5). Common

risk factors for ITH in VS are anticoagulant therapy (6), and previous radiation therapy (7, 8), as well as hypertension (9), trauma (10), pregnancy (11), tumor size >25 mm (5, 12, 13), and high tumor vascularization (14). Surgical treatment is the therapy of choice in patients with VS who present with ITH (5, 15). The use of antithrombotic agents, either antiplatelet or anticoagulant drugs has increased due to longer human lifespan and increased incidence of atrial fibrillation, atherosclerosis, and thromboembolism (16).

Herein, we present two cases of patients with oral anticoagulant therapy who presented with acute onset of facial nerve (CN-VII) palsy and symptoms

of raised intracranial pressure due to ITH and enlargement of the tumor size with brain stem compression. The senior author (KIA) operated on both patients.

Case Presentations

Case 1

A 56-year-old male with headache and acute onset of left CN-VII palsy with a House-Brackmann (HB) score of Grade III (i.e., moderate nerve damage) presented to our clinic. The patient experienced progressive left-sided hearing loss several years prior to acute onset of CN-VII palsy. The patient was on anticoagulant therapy with warfarin due to atrial fibrillation. Post-contrast magnetic resonance imaging (MRI) of the head revealed a left-sided VS with intratumoral bleeding (Figure 1). The patient underwent surgical treatment 3 days after initial presentation. Urgent surgery was not performed due to the need to optimize the coagulation status of the patient first, and also due to the fact that the patient did not neurologically deteriorate. Warfarin therapy was paused and therapy with low-molecular-weight heparin (LMWH) was applied due to indication for persistent anticoagulation due to atrial fibrillation. Preoperative substitution of the coagulation factors with prothrombin complex concentrate (PCC) until normalization of the international normalized ratio (INR) was applied. Gross total resection of the VS was performed via suboccipital retrosigmoid approach. Intratumoral

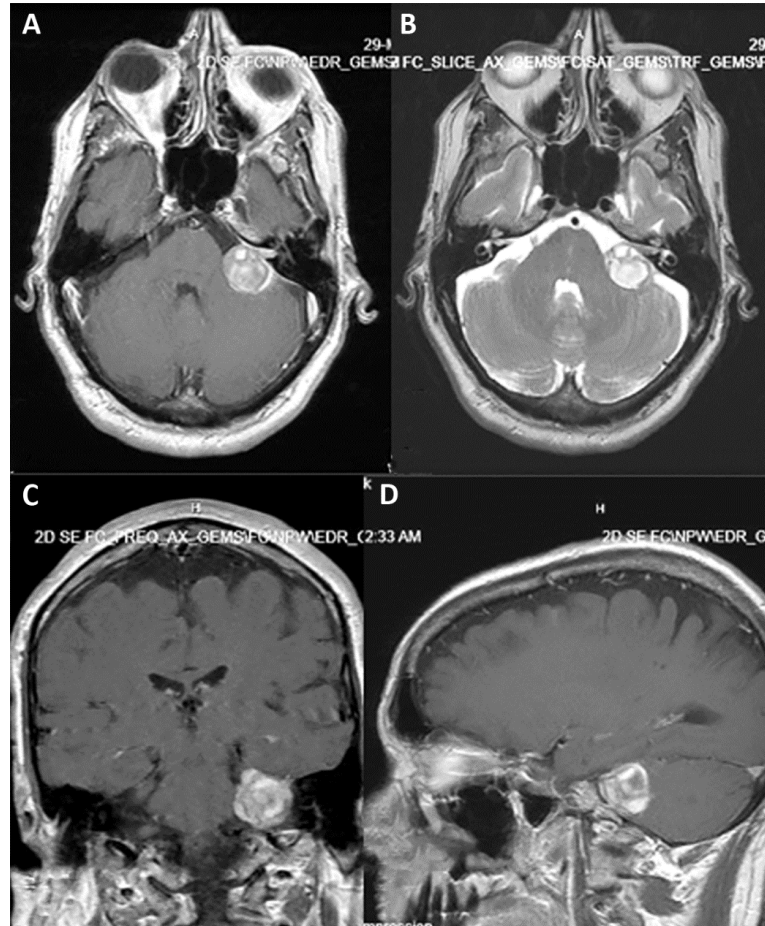


Figure 1. Preoperative head MRI of a 56-year-old patient with acute onset of left CN-VII palsy. (A) Axial T1-post contrast MRI, (B) axial T2 MRI, (C) coronal T1-post contrast, and (D) sagittal T1-post contrast head MRI shows left sided VS with signs of intratumoral bleeding and effacement of the pons.

bleeding was demonstrated in the course of surgical resection. The patient recovered his facial nerve palsy and was neurologically intact apart from complete hearing loss on the left side (Figure 2). Postoperative MRI revealed resection of the tumor (Figure 3). Warfarin therapy was continued 4 weeks following surgery, which overlapped with LMWH.

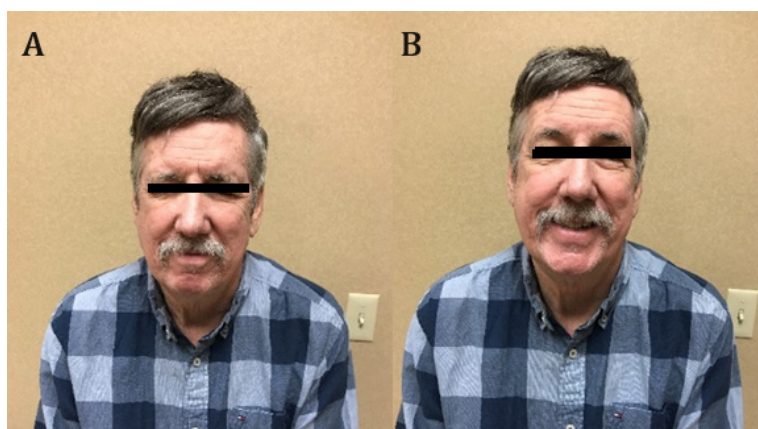


Figure 2. Patient from Figure 1 at 3 months follow up. CN-VII palsy resolved completely.

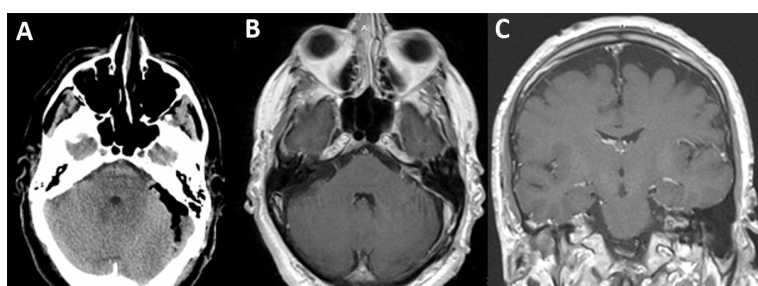


Figure 3. Postoperative imaging of the patient. (A) immediate postoperative CT of the head following surgery. (B) Axial and (C) coronal postoperative post-contrast head MRI showing resection of the tumor.

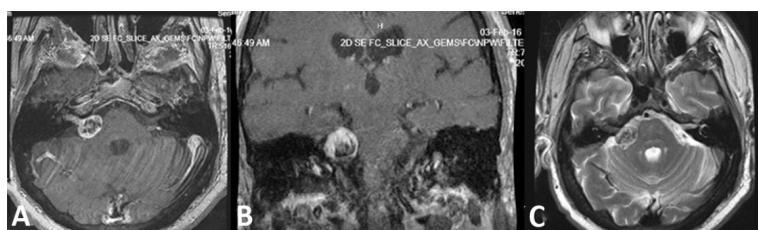


Figure 4. Initial T1-weighted post-contrast MRI of the 58-year-old patient (Case 2). (A) Axial, (B) coronal, and (C) T2 axial views show right-sided VS. The tumor was followed up.

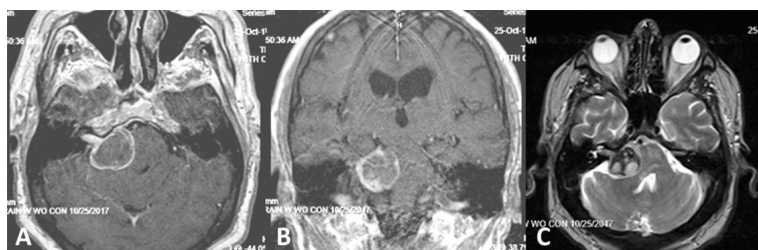


Figure 5. MRI of the patient from Case 2 on warfarin therapy due to artificial heart valve, showing enlarged VS on the left side with intratumoral bleeding. (A) T1 weighted axial MRI, (B) T1 weighted coronal post-contrast MRI of the head, and (C) axial T2 weighted MRI of the head show intratumoral hemorrhage.

Case 2

A 58-year-old male with known right-sided VS diagnosed due to progressive right-sided hearing loss (Figure 4). The tumor was followed up due to patient refusal for surgical or radiosurgical treatment. The patient was morbidly obese with a known history of heart failure with an ejection fraction (EF) of 20%, an artificial heart valve, and treatment with warfarin therapy. The patient presented 3 years prior after initial MRI with headache, acute onset of CN-VII palsy on the right side, complete hemifacial numbness, and inability to walk. Subsequent MRI revealed an enlarged right sided VS with ITH and compression of the brain stem (Figure 5). Warfarin therapy was paused and LMWH was applied due to the indication for persistent anticoagulation related to the patient's artificial heart valve. Preoperative substitution of the coagulation factors with prothrombocyte concentrate until normalization of the international normalized ratio (INR) was applied. Surgery was performed 3 days following the initial presentation with a subtotal resection of the VS via the suboccipital retrosigmoid approach. Intratumoral bleeding was demonstrated during the resection, but the patient significantly improved his facial nerve palsy and was neurologically intact apart from complete hearing loss on the left side (Figure 6). Postoperative MRI revealed subtotal resection of the tumor (Figure 7). Warfarin was continued 4 weeks following surgery, which overlapped with LMWH.

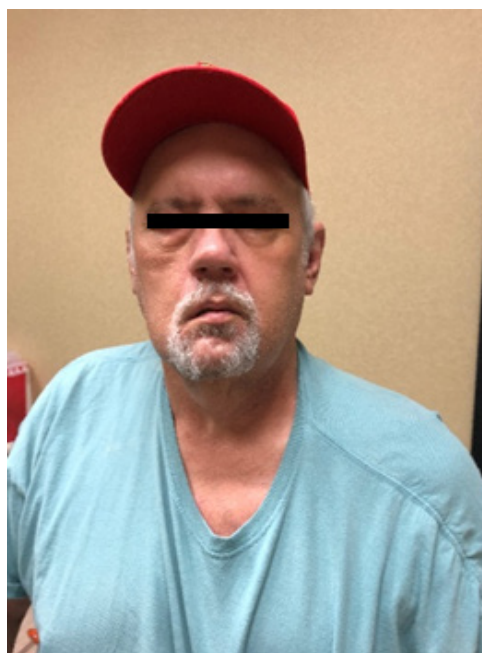


Figure 6. Patient from Figures 4 and 5 at 3-month follow-up with significant improvement of the CN-VII palsy (from Gr V to Gr III).

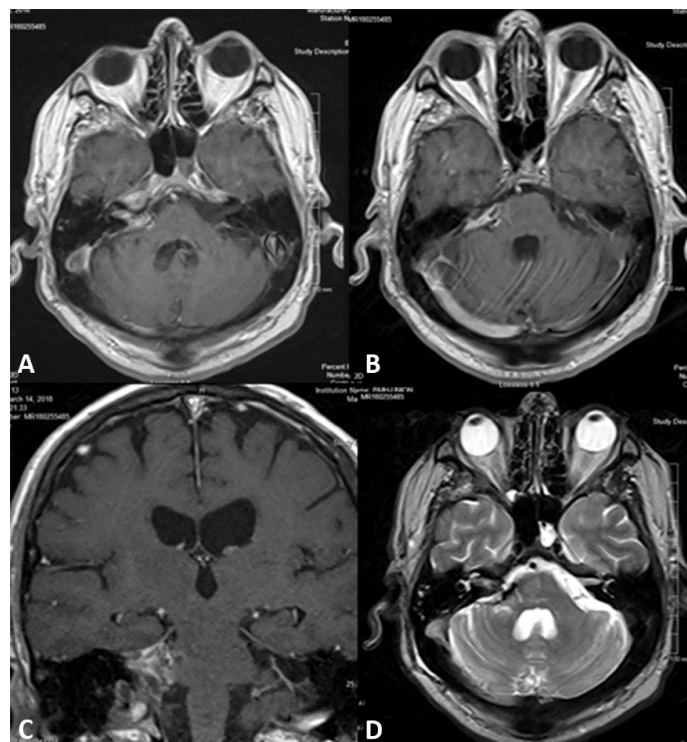


Figure 7. Postoperative head MRI at 3-month follow up shows subtotal resection of the tumor. (A) Post-contrast MRI of the head axial T1-weighted image in the level of the internal meatus and (B) axial T1-weighted image in the level of apex of the pyramid, and (C) coronal T1-weighted and (D) axial T2-weighted MRIs show subtotal resection of the tumor without brain stem compression (45).

Discussion

ITH in VS is a rare but well-known event. Most commonly, it happens in cystic cases and not in solid cases. It is estimated that tumor-associated hemorrhage in VS occurs in 0.4% of cases and commonly presents with acute neurological change (6). However, prospective analyses have suggested that ITH might be a part of the natural history of VS (5). Microbleeding in the tumor bed of VSs with subsequent fibrosis is a described phenomenon, which has been proposed as a possible mechanism for hearing loss in these tumors (17). On the molecular level, it has been postulated that ITH, vessel density, and the inflammatory reaction contribute to volume increase of sporadic VSs (18). Cystic and inhomogeneous tumors showed significantly more hemosiderin deposition than homogeneous tumors, and micro-vessel density was significantly higher in tumors with a high number of

CD68-positive cells (18). Intratumoral microhemorrhage is a possible mechanism of pathogenesis in cystic VS, characterized by unpredictable expansion of the cyst component (1). Most VSs demonstrate microhemorrhages on T2-weighted gradient-echo (GRE) MRI, which is useful for differentiating these tumors from meningiomas of the CPA (17).

Clinically significant ITH occurs in approximately 11% of all brain tumors and is most common in glioblastoma multiforme, choriocarcinomas, pituitary adenomas, meningiomas, choroid plexus papillomas, and oligodendrogliomas (9). Intratumor bleeding in an VS can lead to a rapid and profound onset of symptoms due to the limited confines of the posterior fossa and the immediate expansion of tumor size, which results in severe headaches, nausea and vomiting, abrupt deterioration in hearing, and a significantly higher

incidence of facial weakness (15). Mathkour et al. found 48 cases of intratumoral hemorrhage in patients with VSs in 30 published articles in the period 1974–2019 (15). One further review of 39 cases with ITH in VS showed an average tumor size of 3.11 ± 1.12 cm; the authors postulated that patient age and tumor size in hemorrhagic cases of VS did not differ significantly from non-hemorrhagic cases of VS (5). Carlson et al., in a retrospective case series, found that anticoagulated patients had a 25-fold increase in significant VS hemorrhage (6). Facial nerve dysfunction at presentation occurred with greater frequency in cases of hemorrhagic VS (33.3%) than in non-hemorrhagic VS (6.0%), and death occurred more frequently in cases of hemorrhagic VS (10.0%) than in non-hemorrhagic VS (0.2%) (5). Abnormality of tumor-associated vasculature was noted histologically in many cases, and many the cases reported prior treatment by stereotactic radiosurgery (5). Cystic formation, large size, mixed Antoni type, and anticoagulation therapy seem to enhance the risk of tumor hemorrhage (19). Risk of ITH in patients with VS has been shown to be related to hypertension (9), trauma (10), pregnancy (11), tumor size >25 mm (5, 12, 13), high tumor vascularization (14), cocaine use (20), methotrexate (21), and weight lifting (22). The prognosis of surgery for patients with acute hemorrhagic VS may be better than that for microhemorrhage in multicystic VS (9). Timely microsurgical treatment is also important to relieve symptoms (9).

Antithrombotic agent use has increased as human longevity leads to increased atrial fibrillation, atherosclerosis, and thromboembolism (16). Six million Americans have been found to use anticoagulant drugs (~2% of the population), putting them at an increased risk of ITH (23). A recent meta-analyses revealed that anticoagulation therapy in patients with brain tumors due to venous thromboembolism was not associated with an increased risk of intracerebral hemorrhage (ICH) in the setting of brain metastasis; however, anticoagulation therapy use resulted in a greater than

3-fold increased risk of ICH in patients with gliomas (24, 25). Direct oral anticoagulants (DOACs) have brought advantages in the management of many patients, with evidence showing a lower risk of intracranial bleeding versus vitamin K antagonists (VKAs) (26). However, due to the increased number of anticoagulated patients worldwide, major and life threatening oral anticoagulant-related bleeding is also increasing, and effective reversal strategies are needed (26).

The risk of clinically significant hemorrhage increases 25-fold in patients receiving anticoagulation versus the general VS population (6, 27). Anticoagulation treatment, as well as previous radiation therapy, appear to be crucial risk factors for subarachnoid hemorrhage from an VS (7), as well as for ITH (8). Interestingly, recent literature emphasized the use of anticoagulant therapy as a major risk factor for ITH in VS but did not analyze this issue further (5, 15). This issue was not addressed specifically in Mathkour et al. (15). Niknafs et al. described only 2 cases of anticoagulant therapy with ITH in VS (5). Out of 78 patients reported with bleeding in acoustic neurinomas reported until 2022, there were 9 cases that used anticoagulation therapy (11.5%) (28).

The first case report on intratumoral bleeding in patient with VS on oral anticoagulant therapy was published in 1987 (29). A 58-year-old man bled into an undiagnosed VS while on long-term anticoagulation therapy, which was started following aortic valve replacement. The patient presented with multiple cranial nerve-paralysis of sudden onset. The tumor was removed sub-totally, but the patient died 5 days postoperatively from recurrent hemorrhage into the tumor bed (29). Duration of anticoagulation is not necessarily a strong predictor of hemorrhage risk with VS (6). Prior to the year 2000, there was one additional case report of ITH in VS in a patient taking aspirin (30). We identified 9 cases in 8 articles with ITH in VS due to use of oral anticoagulant therapy in the past 20 years (Table 1).

Table 1. Literature Review on ITH in Patients on Oral Anticoagulant Therapy with VS

Author and year	Cases (age, gender)	Oral anti-coagulant therapy	Comorbidities	Side and size	Previous diagnosis and treatment of the VS	Presentation	Hydro-cephalus	Reversal of co-agation therapy	Surgical treatment	Outcome
Vellin et al. 2006 (33)	73, F	Anti Vitamin-K overdose (INR not specified)	Arterial hypertension		No	Rapid onset of headache, facial palsy, diplopia, and hoarseness	Yes	Not specified	No	Massive intratumoral and brainstem bleeding, coma and death 3 days following admission
Yates et al. 2010 (34)	69, M	Warfarin (INR not specified)	Hypertension, hyperlipidemia, coronary artery disease with myocardial infarction, paroxysmal atrial fibrillation.	Left, 3.2x2.6 cm	No	CN-VII palsy (HB IV), decreased facial sensation on the left, wheel-chair-bound due to disequilibrium, no other focal neurologic signs; patient was alert and oriented; moderate-to-severe sensorineural hearing loss on the left with poor word recognition ability	Yes	Warfarin dosing was discontinued; patient was given interim therapy with LMWH to continue anticoagulation until surgery	Scheduled for urgent, non-emergent surgery	Emergent ventricular drain due to hydrocephalus and re-bleeding 2 days following admission; posterior fossa craniectomy and evacuation of hematoma for decompression; death on the first post-operative day
Carlson et al. 2017 (6)	Case 1: 39, M	Warfarin (INR, 2.8)	Atrial septal defect, hypertrophic nonobstructive cardiomyopathy, severe pulmonary hypertension	Left, 4.2 cm ³	No	HA, Diz, HL, ataxia, hemiparesis	Yes	Not specified	GTR via retro-sigmoid approach; VP shunt due to hydrocephalus	CN-VII (HB VI) (complete resolution), improvement of ataxia and disequilibrium
	Case 3: 68, M	Long term low dose aspirin followed by warfarin and enoxaparin 2 weeks prior to ITH due to pulmonary embolism (INR, 2.3)	Hypertension, diabetes, pulmonary embolism	Right, 3.1 cm ³	No	Headache, dizziness, hearing loss, CN-VII paresis (HB IV), hypoesthesia	Yes	Not specified	STR via retro-sigmoid approach, VP shunt due to hydrocephalus	CN-VII palsy (HB I) (CN-VII was not preserved during surgery)
Schlieter et al. 2005 (32)	49, M	Phenprocoumon (INR, >7)	Not specified	Right, 15 mm axial diameter	No	Acute right-side palsy of the CN-VII and CN-VIII, acute hearing loss, headache, vertigo, and vomiting.	No	Not specified	Surgical resection, details not specified	7th cranial nerve dysfunction improved slightly, deafness

Continuation of Table 1.

Author and year	Cases (age, gender)	Oral anti-coagulant therapy	Comorbidities	Side and size	Previous diagnosis and treatment of the VS	Presentation	Hydrocephalus	Reversal of coagulation therapy	Surgical treatment	Outcome
Ganslandt et al. 2008 (19)	72, F	Warfarin (INR not specified)	Cardiac arrhythmia	Left, initially 3.8 cm ³	Yes VP Shunt due to hydrocephalus and SRS with 35 Gy	15 months after SRS sudden onset of hemiparesis and progressive loss of consciousness due to ITH, additional bleeding into the cerebellum and compression of the brain stem.	Yes	Not specified	Emergent resection via posterior fossa decompression	Death following surgery due to central regulation failure
Moscovici et al. 2020 (7)	67, F	Warfarin (INR, 5.5)	Mechanical aortic valve replacement for which patient was taking warfarin, obstructive sleep apnea, hypertension, depression, morbid obesity, type 2 diabetes	Left, 12x20.5 mm with subarachnoid hemorrhage	Yes SRS with 12 Gy in a single fraction 7 years before acute onset	Sudden onset of disequilibrium, HA, vomiting, diplopia and left sided facial weakness, hyperlaccimation and intermittent hemifacial spasm, CN VII palsy (HB IV) as well as abducens palsy	No	Prothrombinex and Vitamin K	Semi-urgent elective GTR via translabryrithine approach	The degree of left facial nerve palsy appeared to be similar (HB IV); however, symptoms of disequilibrium improved
Banaama et al. 2016 (12)	76, F	Anticoagulant therapy (not specified)	Hypertension, hypercholesterolemia, thrombosis of the right carotid artery, acute myocardial infarction, total knee replacement, thoracic and lumbar fractures, diabetic retinopathy, aortic valve replacement, coronary artery bypass surgery, postoperative arterial fibrillation	Left, giant, size not specified	Yes Diagnosis of polycystic VS due to hearing loss 5 years prior to initial presentation	Severe headache and a facial palsy House and HB V	Yes	Not specified	Emergent surgery for hematoma evacuation and partial resection of the VS via retrosigmoid approach	Death due to rebleeding 36 hours following initial surgery

Continuation of Table 1.

Author and year	Cases (age, gender)	Oral anti-coagulant therapy	Comorbidities	Side and size	Previous diagnosis and treatment of the VS	Presentation	Hydro-cephalus	Reversal of co-agation therapy	Surgical treatment	Outcome
Rizk et al. 2019 (45)	83, M	Antiplatelet drug (aspirin and clopidogrel)	Coronary heart disease, stents	Left, cystic, size not specified	Yes Diagnosis of left sided VS 2.5 years prior to surgery due to CN-VII palsy (HB V) and hearing loss	Follow up MRI without new symptoms showed approximately 3 times enlargement of the tumor with ITH	No	After holding aspirin and clopidogrel for 5 days, surgery was performed within 3 weeks of the onset of facial weakness	STR through retro-sigmoid approach	Neurologically unchanged with persistent CN-VII palsy (HB V)

GTR=Gross total resection; HB=House-Brackmann; INR=International normalized ratio; ITH=Intratumoral hemorrhage; LMWH=Low-molecular-weight heparin; MRI=Magnetic resonance imaging; SRS=Stereotactic radiosurgery; STR=Sub-total resection; VP=Ventriculoperitoneal; VS=Vestibularschwannoma.

Because the risk of hemorrhage in VS is significantly greater with systemic anticoagulation, and because reports have demonstrated poorer clinical outcomes while on anticoagulation therapy, the management of this subset of patients becomes a critical point of discussion (6). One fifth of all reported cases of ITH in VS were using oral anticoagulant therapy. Seven fatalities have been reported so far in patients with ITH in VS (15); out of these, 4 were patients on oral anticoagulant therapy. In the setting of significant ITH, cranial nerve-VII dysfunction is observed in 46.9% of cases (6); in contrast, all patients on oral anticoagulant therapy had a sudden onset or worsening of CN-VII palsy. A recent review of 47 cases of hemorrhagic VS showed that 7 patients experienced improved facial nerve function after resection, with the remainder either remaining unchanged or not reported (15). In comparison, our 2 cases have excellent outcome with complete resolution of symptoms and CN-VII palsy. Out of 9 reported cases, VS was previously diagnosed in 4 patients; in 2 cases, observation with follow up MRI scans was performed; in 2 further cases, stereotactic radiosurgery (SRS) was performed. One patient who was followed up and one patient who underwent SRS died following urgent surgery for ITH in VS. ITH after VS radiosurgery is a rare phenomenon with a cumulative incidence rate of 0.26% (31). Given the poor outcome with high mortality and

improvement of CN-VII palsy only in 2 out of 5 patients who survived ITH in VS, we recommend surgical treatment at initial diagnosis for patients on oral anticoagulant therapy in order to prevent secondary ITH and acute enlargement of the tumor mass. The most common oral anticoagulants were overdosed vitamin-K-antagonist warfarin (Coumadin, Jantoven) and phenprocoumon. Fortunately, reversal of anticoagulant effect is very easily possible with PCC. Out of 6 patients on warfarin, warfarin was overdosed in 4 cases (Table 1)—2 cases from Carlson et al. (6), and 1 case each from Schlieter et al. (32) and Moscovici et al. (7). Velin et al. (33), Yates et al. (34) and Ganslandt et al. (19) did not specify INR.

As for aspirin use, there is currently a Phase II study on use of aspirin as a possible medication therapy to halt progression of vestibular schwannomas (35). In a previous retrospective study of 347 vestibular schwannoma patients seen at Mass Eye and Ear, the probability of a tumor growth in patients who took aspirin for unrelated medical reasons was about half that of patients who did not take aspirin. However, that trend was not observed in retrospective studies from other institutions (36).

It seems that anticoagulation treatment acts as a secondary trigger to intratumoral microhemorrhages by enhancing bleeding and preventing the self-tamponade phenomenon achieved by the tumor's capsule (6). In hemorrhagic VS, 1 out of 5

patients were previously treated with SRS (5). A 7-element bundle for treating major or life-threatening oral anticoagulant-associated bleeding has been proposed and includes the following: (a) withdrawing the anticoagulant until local hemostasis is safe; (b) replacing fluids; (c) conducting blood tests (hemoglobin level, platelet count, renal function, liver function, prothrombin time [PT], and activated prothrombin time [aPTT]), and DOAC plasma level when necessary; (d) transfusing red blood cells, platelets and/or fresh frozen plasma, and tranexamic acid; (e) measuring local hemostasis (endoscopy, interventional radiology procedure or surgical intervention); (f) checking and managing additional bleeding risk factor; and (g) reversing the anticoagulant effect (26). Specific reversal is possible for direct thrombin inhibitors (idarucizumab for dabigatran) and factor Xa inhibitors (andexanet for apixaban, edoxaban, and rivaroxaban); in addition, non-specific reversal treatment can be used for both of these medication groups as well as for vitamin K antagonists PCC (37), which was the strategy used in our two cases. Guidelines suggest that patients with major or life-threatening vitamin K antagonist-associated bleeding should be promptly treated with 4-factor PCCs at doses tailored on INR value in addition to intravenous vitamin K (38). A histological review of 274 VS specimens revealed that nearly all exhibited varying levels of intratumoral microhemorrhage, and more extensively involved tumors were independently associated with preoperative unserviceable hearing (39). It has also been suggested that multiple hemorrhagic events could account for the existence of cystic VS that comprise 5%–10% of tumors and are widely described as demonstrating rapid growth, shorter symptom durations, and worse outcomes after resection (40). In a histopathologic examination of VS, Niknafs et al. reported 2 vascular abnormalities, including dilated thin-walled vessels and hypervascularity in every specimen examined. These vascular abnormalities likely predispose the tumor to develop microhemorrhages (5). Recently, matrix metalloproteinase II activity within the tumor, which leads to vascular fragility and microhemorrhage,

has been proposed as a causative agent in VS cystic degeneration (41).

Several recommendations regarding the use of anticoagulation in VS patients have been proposed, such as tight management of INR to avoid supratherapeutic levels that may increase the risk and severity of hemorrhage, reevaluation of the need for anticoagulation and finding alternatives to systemic anticoagulation (such as cardioversion or ablation for arrhythmia when feasible), and maintaining a low threshold for intracranial imaging following any change in neurological symptoms (done under the assumption that earlier recognition can result in improved outcome) (6). Most patients on long-term anticoagulation with small-to-medium sized VSs are treated conservatively with observation or radiotherapy due to the risks associated with surgery (6). Based on a limited clinical data, Carlson et al. suggested that observation is the best initial treatment strategy for anticoagulated patients with small or medium sized tumor (6). DOACs were not associated with an increased incidence of ICH relative to LMWH in patients with brain metastases or primary brain tumors (42).

As a possible alternative to surgical treatment, Shelfer et al. proposed a discontinuation of the oral anticoagulant therapy in a case report of an elderly female patient with VS and a high risk of falls without previous history of strokes (43). The authors thought that since the patient was a high fall risk, the potential consequences of a head injury with intracranial bleeding on anticoagulation therapy outweighed the risk of atrial fibrillation-related embolus formation (43). A study of 48 patients between 70 to 90 years of age with VS recommended that surgical resection is a good option in patients >70 years of age with a tumor size <1.5 cm if the patient's hearing is viable, the tumor demonstrates a growth of more than 2 mm per year, and the patient is in good general health. If one of these 3 criteria is not met, then follow up was recommended with serial imaging (30, 44). Yates et al. recommended consideration of anticoagulant therapy when deciding between surgery and conservative management (34). The risk of hemorrhage with

antiplatelet therapy was not evaluated so far but is relevant to VS since recent data suggested that cyclooxygenase inhibitors, such as aspirin, may reduce the probability of future tumor growth in conservatively managed VS (36).

Both our cases were solid in nature. Surgery was performed with gross total resection in one case and subtotal resection in the second case. The CN-VII palsy resolved fully and there were no further neurological deficits apart from deafness on the side of the lesion. We also conducted a literature review of patients on oral anticoagulant therapy who underwent surgical treatment due to ITH in VS, which shows that oral anticoagulant therapy increases the risk of ITH in VS, as well as poor outcomes that prompt surgical treatment. To our knowledge this is the first article on two cases of patients on oral anticoagulant therapy with ITH in VS with a literature review solely dedicated to ITH in VS due to use of oral anticoagulants.

Conclusions

Spontaneous ITH in patients on oral anticoagulant therapy is a rare event. Nevertheless, anticoagulant therapy is a major risk factor for intratumoral bleeding in VSs and may be associated with higher mortality among patients with ITH in VS and an unfavorable prognosis for recovery of neurological deficits. Vitamin K antagonists were the most common oral anticoagulants in patients with ITH in VS. Microsurgical resection should be pursued as soon as possible in symptomatic patients especially with brain stem compression since resection of the tumor may improve neurological symptoms, decompress the brainstem, and reduce the risk of repeat hemorrhage. Preoperative reversal effect of oral anticoagulants with postoperative coagulation assessment with bridging therapy is mandatory. Discontinuation of oral anticoagulant therapy in elderly patients with risk of falls and VS could be an alternative to surgical treatment.

What Is Already Known on This Topic:

Spontaneous intratumoral hemorrhage in patients on oral anticoagulant therapy is a rare event. Nevertheless, oral anticoagulants are a known risk for intratumoral bleeding in VS and may be associated with

higher mortality among patients experiencing this phenomenon. Intratumor bleeding can lead to a rapid and profound onset of symptoms due to the tight and limited confines of the posterior fossa and the immediate expansion of the size of the tumor, which result in severe headache, vomiting, nausea, sudden decline in hearing, and a significantly high incidence of facial weakness. Reports of intratumoral hemorrhage in VS show poor clinical outcomes for patients on anticoagulation therapy, which therefore necessitate recommendations for the use of anticoagulation, especially for withdrawing anticoagulant therapy prior to surgical treatment.

What This Study Adds:

We present the first article in the literature of two cases of patients on oral anticoagulant therapy with intratumoral hemorrhage of VSs and a companion literature review dedicated to this rare phenomenon. After surgery, all neurological deficits for the two patients resolved apart from deafness on the side of the lesion. Our literature review confirmed that patients on oral anticoagulant therapy have an increased risk of intratumoral hemorrhage in VS and poor outcomes that prompt surgical treatment.

Acknowledgements: Andrew J. Gienapp (Children's Foundation Research Institute, Le Bonheur Children's Hospital, Memphis, TN; Department of Neurosurgery, the University of Tennessee Health Science Center, Memphis, TN) provided technical and English language editing, prepared the manuscript, figures, and tables for publishing, drafted publishing related content, and assisted with the publication process.

Authors' Contributions: Conception and design: MP and KIA; Acquisition, analysis, and interpretation of data: MP, GD, AA and KIA; Drafting the article: MP, DG and AA; Revising it critically for important intellectual content: MP and KIA; Approved final version of the manuscript: MP, DG, AA and KIA.

Conflict of Interest: The authors declare that they have no conflict of interest.

References

1. Park CK, Kim DC, Park SH, Kim JE, Paek SH, Kim DG, et al. Microhemorrhage, a possible mechanism for cyst formation in vestibular schwannomas. *J Neurosurg.* 2006;105(4):576-80. doi: 10.3171/jns.2006.105.4.576.
2. Chu M, Wei LL, Li GZ, Lin YZ, Zhao SG. Bilateral acoustic neurinomas presenting as subarachnoid hemorrhage: case report. *Chin Med J (Engl).* 2007;120(1):83-4.
3. Ohta S, Yokoyama T, Nishizawa S. Massive haemorrhage into acoustic neurinoma related to rapid growth of the tumour. *Br J Neurosurg.* 1998;12(5):455-7. doi: 10.1080/02688699844709.
4. Odabasi AO, Buchman CA, Morcos JJ. Tumor-associated hemorrhage in patients with acoustic neuroma. *Am J Otol.* 2000;21(5):706-11.

5. Niknafs YS, Wang AC, Than KD, Etame AB, Thompson BG, Sullivan SE. Hemorrhagic vestibular schwannoma: review of the literature. *World Neurosurg.* 2014;82(5):751-6. doi: 10.1016/j.wneu.2013.02.069. Epub 2013 Feb 27.
6. Carlson ML, Tombers NM, Driscoll CLW, Van Gompel JJ, Lane JJ, Raghunathan A, et al. Clinically significant intratumoral hemorrhage in patients with vestibular schwannoma. *Laryngoscope.* 2017;127(6):1420-6. doi: 10.1002/lary.26193. Epub 2016 Aug 12.
7. Moscovici S, Limb R, Azriel A, Briggs R, Hall N, Kaye AH. Repeated spontaneous intra-tumoural and subarachnoid haemorrhage in an anticoagulated patient with a previously-irradiated vestibular Schwannoma: Case report. *J Clin Neurosci.* 2020;73:323-5. doi: 10.1016/j.jocn.2019.11.018. Epub 2019 Dec 28.
8. Thombre B, Sadashiva N, Krishnan JB, Prabhuraj AR, Rao KN, Arima A. Symptomatic Post-Radiosurgery Intratumoral Hemorrhage in a Case of Vestibular Schwannoma: A Case Report and Review of the Literature. *Stereotact Funct Neurosurg.* 2019;97(5-6):399-403. doi: 10.1159/000504264. Epub 2019 Nov 26.
9. Yang X, Liu J, Zhang Y, Richard SA. Tumor-associated hemorrhage in patients with vestibular schwannoma. *Acta Neurochir (Wien).* 2018;160(8):1563-9. doi: 10.1007/s00701-018-3588-7. Epub 2018 Jun 18.
10. Kojima Y, Tanaka N, Kuwana N. Massive hemorrhage in acoustic neurinoma after minor head trauma--case report. *Neurol Med Chir (Tokyo).* 1990;30(12):972-6. doi: 10.2176/nmc.30.972.
11. Mateo-Sierra O, Delgado-López PD, García-Leal R, Carrera-Fernández J, Traba-López A, Carrillo-Yagüe R. [Massive intratumoral haemorrhage as a clinical presentation of acoustic neuroma]. *Rev Neurol.* 2002;35(7):656-60. Spanish.
12. Banaama S, van Overbeeke J, Temel Y. An unusual case of repeated intracranial hemorrhage in vestibular schwannoma. *Surg Neurol Int.* 2016;7(Suppl 37):S869-71. doi: 10.4103/2152-7806.194494.
13. Asari S, Katayama S, Itoh T, Tsuchida S, Furuta T, Ohmoto T. Neurinomas presenting as spontaneous intratumoral hemorrhage. *Neurosurgery.* 1992;31(3):406-11; discussion 411-2. doi: 10.1227/00006123-199209000-00004.
14. Misra BK, Rout D, Bhiladvala DB, Radhakrishnan V. Spontaneous haemorrhage in acoustic neurinomas. *Br J Neurosurg.* 1995;9(2):219-21. doi: 10.1080/02688699550041593.
15. Mathkour M, Helbig B, McCormack E, Amenta PS. Acute Presentation of Vestibular Schwannoma Secondary to Intratumoral Hemorrhage: A Case Report and Literature Review. *World Neurosurg.* 2019;129:157-63. doi: 10.1016/j.wneu.2019.05.075. Epub 2019 May 17.
16. Macdonald RL. Management of Intracranial Hemorrhage in the Anticoagulated Patient. *Neurosurg Clin N Am.* 2018;29(4):605-13. doi: 10.1016/j.nec.2018.06.013. Epub 2018 Aug 14.
17. Thamburaj K, Radhakrishnan VV, Thomas B, Nair S, Menon G. Intratumoral microhemorrhages on T2*-weighted gradient-echo imaging helps differentiate vestibular schwannoma from meningioma. *AJNR Am J Neuroradiol.* 2008;29(3):552-7. doi: 10.3174/ajnr.A0887. Epub 2007 Dec 13.
18. de Vries M, Hogendoorn PC, Briaire-de Bruyn I, Mallesy MJ, van der Mey AG. Intratumoral hemorrhage, vessel density, and the inflammatory reaction contribute to volume increase of sporadic vestibular schwannomas. *Virchows Arch.* 2012;460(6):629-36. doi: 10.1007/s00428-012-1236-9. Epub 2012 May 4.
19. Ganslandt O, Fahrig A, Strauss C. Hemorrhage into cystic vestibular schwannoma following stereotactic radiation therapy. *Zentralbl Neurochir.* 2008;69(4):204-6. doi: 10.1055/s-2008-1077074. Epub 2008 Jul 29.
20. Yapor WY, Gutierrez FA. Cocaine-induced intratumoral hemorrhage: case report and review of the literature. *Neurosurgery.* 1992;30(2):288-91. doi: 10.1227/00006123-199202000-00028.
21. Mandl ES, Vandertop WP, Meijer OW, Peerdeman SM. Imaging-documented repeated intratumoral hemorrhage in vestibular schwannoma: a case report. *Acta Neurochir (Wien).* 2009;151(10):1325-7. doi: 10.1007/s00701-009-0213-9. Epub 2009 Mar 3.
22. Goetting MG, Swanson SE. Massive hemorrhage into intracranial neurinomas. *Surg Neurol.* 1987;27(2):168-72. doi: 10.1016/0090-3019(87)90290-4.
23. Tomaselli GF, Mahaffey KW, Cuker A, Dobesh PP, Doherty JU, Eikelboom JW, et al. 2017 ACC Expert Consensus Decision Pathway on Management of Bleeding in Patients on Oral Anticoagulants: A Report of the American College of Cardiology Task Force on Expert Consensus Decision Pathways. *J Am Coll Cardiol.* 2017;70(24):3042-67. doi: 10.1016/j.jacc.2017.09.1085. Epub 2017 Dec 1.
24. Zwicker JL, Karp Leaf R, Carrier M. A meta-analysis of intracranial hemorrhage in patients with brain tumors receiving therapeutic anticoagulation. *J Thromb Haemost.* 2016;14(9):1736-40. doi: 10.1111/jth.13387. Epub 2016 Jul 29.
25. Porfidia A, Giordano M, Sturiale CL, D'Arrigo S, Donadini MP, Olivi A, et al. Risk of intracranial bleeding in patients with primary brain cancer receiving therapeutic anticoagulation for venous thromboembolism: A meta-analysis. *Brain Behav.* 2020;10(6):e01638. doi: 10.1002/brb3.1638. Epub 2020 Apr 21.
26. Moia M, Squizzato A. Reversal agents for oral anticoagulant-associated major or life-threatening bleeding. *Intern Emerg Med.* 2019;14(8):1233-9. doi: 10.1007/s11739-019-02177-2. Epub 2019 Aug 24. Erratum in: *Intern Emerg Med.* 2019 Nov 27.
27. Carlson ML, Driscoll CL, Link MJ, Inwards CY, Neff BA, Beatty CW. A hemorrhagic vestibular schwannoma presenting with rapid neurologic decline: a case report.

- Laryngoscope. 2010;120 Suppl 4:S204. doi: 10.1002/lary.21671.
28. Woo PY, Lam PL, Ip YH, Chan TS, Ng OK, Kwan MC, et al. "When the Benign Bleed" Vestibular Schwannomas with Clinically Significant Intratumoral Hemorrhage: A Case Series and Review of the Literature. *Asian J Neurosurg*. 2021;16(1):221-7. doi: 10.4103/ajns.AJNS_287_20.
 29. Chee CP, Bailey IC, Refsum SE. Spontaneous massive haemorrhage into acoustic neuroma during anticoagulation therapy. *Br J Neurosurg*. 1987;1(4):489-93. doi: 10.3109/02688698708999641.
 30. Chou D, Sampath P, Brem H. Hemorrhagic vestibular schwannoma: an unusual clinical entity. Case report. *Neurosurg Focus*. 1998;5(3):e9. doi: 10.3171/foc.1998.5.5.10.
 31. Bin-Alamer O, Fogg D, Wei Z, Duehr J, Mallela AN, Niranjan A, et al. Intratumoral hemorrhage in vestibular schwannomas after stereotactic radiosurgery. *J Neurosurg*. 2022;138(2):413-9. doi: 10.3171/2022.5.JNS22935.
 32. Schlieter M, Zoubaa S, Kress B, Unterberg A, Jacobi C, Hähnel S. Hemorrhagic acoustic schwannoma: radiological and histopathological findings. *J Neuroradiol*. 2005;32(3):210-2. doi: 10.1016/s0150-9861(05)83139-6.
 33. Vellin JF, Bozorg Grayeli A, Kalamarides M, Fond C, Bouccara D, Sterkers O. Intratumoral and brainstem hemorrhage in a patient with vestibular schwannoma and oral anticoagulant therapy. *Otol Neurotol*. 2006;27(2):209-12. doi: 10.1097/01.mao.0000188339.45772.be.
 34. Yates CW, Weinberg M, Packer MJ, Jacob A. Fatal case of tumor-associated hemorrhage in a large vestibular schwannoma. *Ann Otol Rhinol Laryngol*. 2010;119(6):402-5. doi: 10.1177/000348941011900607.
 35. Mass General Brigham. Does Aspirin help in the treatment of Vestibular Schwannoma/Acoustic Neuroma? Mass General Brigham. [cited 2023 Nov 11]. Available from: https://rally.massgeneralbrigham.org/study/aspirin_in_vestibular_schwannoma.
 36. Kandathil CK, Dilwali S, Wu CC, Ibrahimov M, McKenna MJ, Lee H, et al. Aspirin intake correlates with halted growth of sporadic vestibular schwannoma in vivo. *Otol Neurotol*. 2014;35(2):353-7. doi: 10.1097/MAO.0000000000000189.
 37. Steffel J, Verhamme P, Potpara TS, Albaladejo P, Antz M, Desteghe L, et al. [The 2018 European Heart Rhythm Association Practical Guide on the use of non-vitamin K antagonist oral anticoagulants in patients with atrial fibrillation: executive summary]. *Kardiol Pol*. 2018;76(9):1283-98. Polish. doi: 10.5603/KP.2018.0180.
 38. Sarode R, Milling TJ Jr, Refaai MA, Mangione A, Schneider A, Durn BL, et al. Efficacy and safety of a 4-factor prothrombin complex concentrate in patients on vitamin K antagonists presenting with major bleeding: a randomized, plasma-controlled, phase IIb study. *Circulation*. 2013;128(11):1234-43. doi: 10.1161/CIRCULATIONAHA.113.002283. Epub 2013 Aug 9.
 39. Sughrue ME, Kaur R, Kane AJ, Rutkowski MJ, Yang I, Pitts LH, et al. Intratumoral hemorrhage and fibrosis in vestibular schwannoma: a possible mechanism for hearing loss. *J Neurosurg*. 2011;114(2):386-93. doi: 10.3171/2010.5.JNS10256. Epub 2010 Jun 18.
 40. Piccirillo E, Wiet MR, Flanagan S, Dispenza F, Giannuzzi A, Mancini F, et al. Cystic vestibular schwannoma: classification, management, and facial nerve outcomes. *Otol Neurotol*. 2009;30(6):826-34. doi: 10.1097/MAO.0b013e3181b04e18.
 41. Moon KS, Jung S, Seo SK, Jung TY, Kim IY, Ryu HH, et al. Cystic vestibular schwannomas: a possible role of matrix metalloproteinase-2 in cyst development and unfavorable surgical outcome. *J Neurosurg*. 2007;106(5):866-71. doi: 10.3171/jns.2007.106.5.866.
 42. Carney BJ, Uhlmann EJ, Puligandla M, Mantia C, Weber GM, Neuberger DS, et al. Intracranial hemorrhage with direct oral anticoagulants in patients with brain tumors. *J Thromb Haemost*. 2019;17(1):72-6. doi: 10.1111/jth.14336. Epub 2018 Dec 11.
 43. Shelfer J, Zapala D, Lundy L. Fall risk, vestibular schwannoma, and anticoagulation therapy. *J Am Acad Audiol*. 2008;19(3):237-45. doi: 10.3766/jaaa.19.3.8.
 44. Glasscock ME, Pappas DG, Manolidis S, Von Doersten PG, Jackson CG, Storper IS. Management of acoustic neuroma in the elderly population. *Am J Otol*. 1997;18(2):236-41; discussion 241-2.
 45. Rizk AR, Mehlitz M, Bettag M. Chances of Improvement in Cases of Vestibular Schwannoma Presenting with Facial Nerve Weakness: Presentation of Two Cases and Literature Review. *J Neurol Surg B Skull Base*. 2019;80(1):40-5. doi: 10.1055/s-0038-1661414. Epub 2018 Jul 3.
-