

The Hyoid Bone - the Anatomy of a Small Bone of the Neck in Hellenic and Greco-Roman Medical Literature

Maria Rachi, George Dages, Panagiotis Georgakopoulos, Evaggelos Mavrommatis

Medical School, National and Kapodistrian University of Athens, Athens, Greece

Correspondence: *evagmavrommatis@protonmail.com*; Tel.: + 30 697 6778252

Received: 31 July 2023; **Accepted:** 14 November 2023

Abstract

Objectives. To understand the nomenclature of the hyoid bone. **Materials and Methods.** Hyoid, a small bone of the neck, is a bony part that is rather difficult to unearth and discover among skeletal remains. **Results.** The name was coined by the ancient Greeks, along with its anatomic description. Galen (2nd – 3rd c. AD) and Theophilus Protospatharius (7th century AD), facing religious and social barriers, succeeded in presenting its anatomy and suggesting its probable function in speech and swallowing, regarding the bone as a muscle pillar of the neck area. **Conclusion.** Authorities of Hellenic antiquity surprise us with their accuracy and the resilience of their anatomical descriptions.

Key Words: Hyoid Bone ■ Galen ■ Theophilus Protospatharius.

Introduction

The hyoid bone is found in the superior anterior region of the neck (Figures 1 and 2). It is characteristic of this bone that it is one of the few that have no contact with any other bone, but is held in position by muscles alone. It has a role as a supportive structure for the tongue and the various muscles around it. It may have various shapes, but it is mainly U-shaped or receives a similar one. In very rare cases it is not present or missing one of the greater or lesser of its horns. Sometime it is situated higher or lower than its usual anatomical area (1). During the 19th century it was regarded as the border distinguishing the upper and lower parts of the neck area (2). This small bone has been situated above the larynx since the era of the Neanderthals, but specimens are very hard to find in human skeleton remains (3). Since the Hellenic antiquity the hyoid bone has been well known as a point used to produce severe pain in opponents in the martial arts (4). However, it was scarcely described in the literature on human anatomy, as the

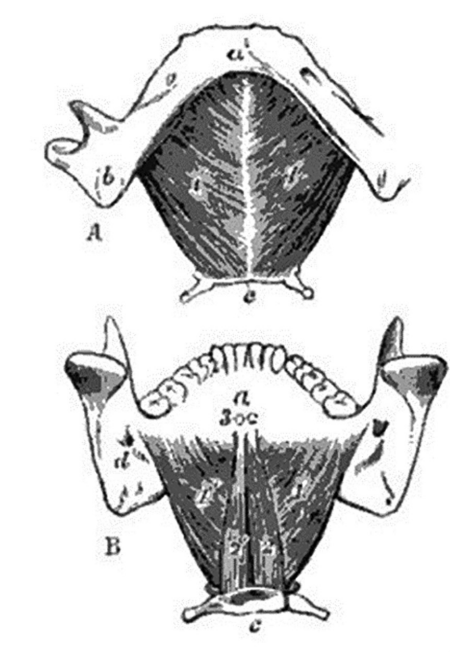
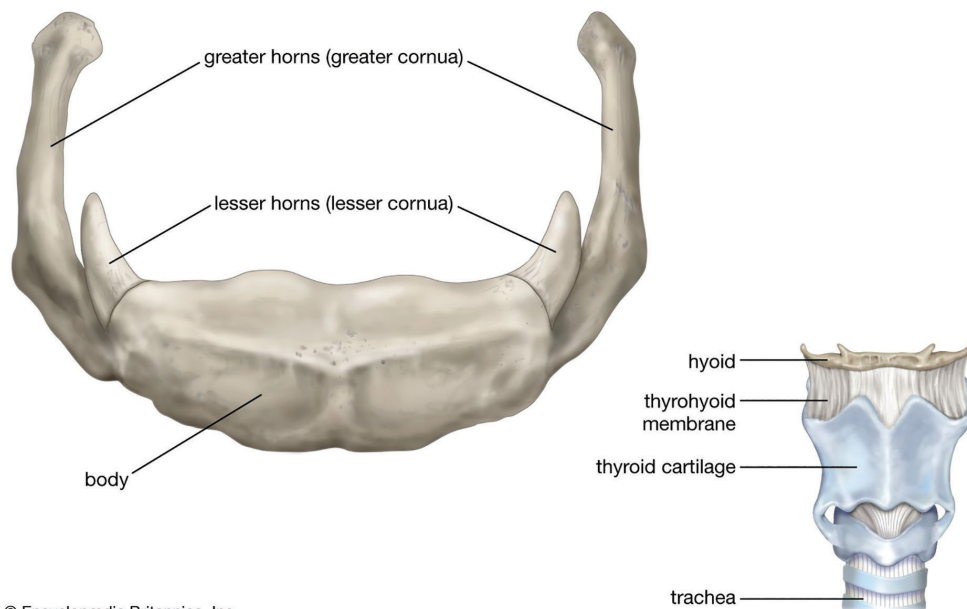


Figure 1. A. The lower jaw and hyoid bone (c) from below, with the mylo-hyoid muscles attached; B. The same with the genio-hyoid muscles attached. Figure by Allen Thomson in Jones Quain's *Elements of Anatomy*, Longmans, Green, and Company, London, 1894.

Human hyoid bone

© Encyclopædia Britannica, Inc.

Figure 2. Hyoid bone. From Encyclopaedia Britannica 2023

body was considered sacred due to social and religious issues (5). The opportunity to observe it directly was rare, usually resulting from battle injuries, fight wounds (as in gladiator games) or during surgical operations on the area (6). This historical review surveys a time period of 7 centuries, from 100 BC to 800 AD, a time span including the Late Hellenistic period and the Late Eastern Roman Empire (Byzantium).

The research aims to unveil data concerning the hyoid bone and describe its anatomy, while simultaneously recording the opinions of various scholars of the eras in question.

Materials and Methods

Our material was derived from the data base Thesaurus Lingua Graeca and was focused on ancient Greek and Byzantine medical literature.

The Greeks

The anatomical examination of the hyoid bone began very early in the history of medicine. Ancient

Greek physicians described this anatomic entity of the human body in numerous ancient Greek medical texts, and coined its name. As we may observe, in the work of Rufus of Ephesus (1st – 2nd c. AD), the names of the human anatomical parts are listed and categorized (7). The ancient Greek anatomist informs us that this bone received two different names. The first term used by the majority of the ancient physicians was hyoid, due to the fact that its shape resembled the Hellenic letter “Y” of the ancient Greek alphabet. The second term, as Rufus informs us, was mentioned by Herophilus of Chalcedon (335–280 BC), who named it “παραστάτης” (Greek: ‘assistant’) due to its position close to the tonsils (Rufus Med. De corporis humani appellationibus 155.1-156.1) (8).

Apart from these terms, in ancient Hellenic medical literature this bone was also given the name “Λαμβδοειδής” (Greek: lambda bone, L-shaped), under the belief that it resembled the Greek letter “Λ” (that is ‘L’ in Greek) as an eversion of the letter “Y”. In some cases, the term “Υψυλοειδής” (Greek: hypsiloid) was used, as an expanded type of the term “hyoid” (9).

The hyoid bone was of special interest in clinical medicine among ancient Greek physicians. Galen (2nd – 3rd c. AD), the authoritarian anatomist of the Greeks, wrote that the lower part of this bone, reaching the sternum, did not receive any nerves from the VIth cranial nerve, as Galen defines it, that is the glossopharyngeal, vagus, and spinal accessory combined as a single nerve, due to their joint exit through a common foramen (Galen, *De nervorum dissectione* 2.841.5-8) (10). Meanwhile, he underlined its significance, noting, that despite its small dimensions, a cluster of muscles originates beside it, extending in different directions. These are: all the muscles that extend towards the tongue, the small ones towards the larynx, the long and the narrow ones towards the shoulders, the robust one towards the sternum, and the other oblique ones towards the area of the mentum (Galen, *De usu partium* 3.591.10-19) (11).

The Byzantines

Although Galen is considered to be a great anatomist, the most detailed presentation of the hyoid bone, shedding light on its anatomical characteristics, is found in the work of the Byzantine physician, Theophilus Protospatharius (7th century AD). This prolific Byzantine physician, in his work on the anatomy of the human body (12), summarized all the ancient anatomical knowledge on the subject, pointing out its topographical area in the neck, its relationship to the nearby musculature, its nomenclature, and finally its clinical role. The actions attributed to the hyoid were emphasized, indicating the fact that all the muscles were linked to the bones which open and close the larynx, as well as the locomotor muscles of the tongue. However, his most important observation was the first understanding of the substance of this bone, writing that it is sometimes as hard as a regular bone, but also softer than cartilage. He was also the first to introduce some data on its shape, noting that each side of the bone (horn) is thinner than the thick middle area, adding that each side is linked to the other by an hymenoid ligament (Theoph.

Protospatharius, *De corporis humani fabrica libri quinque* 3.21.1-21) (13).

Results

The key role concerning the basihyal (body of the hyoid) was found in the fact that many different muscles of the area received part of their name from the hyoid bone. Thus, the terms Sterno-, Omo- Stylo-, Thyreo-, Mylo-, and Genio-hyoideus were introduced to the Latin anatomical nomenclature in the Renaissance and have remained until the present day (14).

Discussion

Modern embryology and gross anatomy testify that the hyoid bone ossifies from six centers. These are the basihyals from which the lateral parts of the body grow, the thyrohyals from which the two centers of the greater horns grow, and the ceratohyals from which the lesser horns grow. It can also be absent, and is sometimes positioned in an area more inferior than its usual position. Moreover, the lesser horns may articulate with the greater ones, while they may be unilaterally or bilaterally absent. Greek and Greco-Roman physicians did not have the opportunity for thorough anatomical examinations of the human body for religious reasons, and the prohibitions of philosophical and spiritual principals. These difficulties rendered accurate description impossible. The more precise delineation of the bone was conducted by Andreas Vesalius. Physicians of the Hellenic antiquity connected the hyoid bone with functions such as speech and swallowing, naming it as a part involved in the movements of the neck (15).

Conclusion

The hyoid bone was observed by the Greeks and was included in all their anatomical works. Books from the late 18th century contain detailed references to the bone, based on Greco-Roman knowledge, which influenced Arab medicine and its

concept of anatomy, while Chinese anatomical ideas did not differ from the ancient Greek approach to the theme (16). Its name derives from its origin in ancient Hellenic medico-philosophy. Its role was accurately described in Greco-Roman medical literature, and entered Western Medicine during the Renaissance.

What Is Already Known on This Topic:

The roots of the name are found in ancient Greek medical literature.

What This Study Adds:

This study presents and discusses the development of the nomenclature and the study of this special bone and how the term has survived until today, highlighting the historical background.

Authors' Contributions: Conception and design: MR and GD; Acquisition, analysis and interpretation of data: MR, GD and PG; Drafting the article: MR, GD and EM; Revising it critically for important intellectual content: EM; Approved final version of the manuscript: MR, GD, PG and EM.

Conflict of Interest: The authors declare that they have no conflict of interest.

References

1. Tubbs RS, Shoja MM, Loukas M, editors. Bergman's Comprehensive Encyclopedia of Human Anatomic Variation. Malden, MA: Wiley-Blackwell; 2016.
2. Leidy J. An Elementary Treatise on Human Anatomy. Philadelphia: Lippincott; 1861.
3. Chazan M. World Prehistory and Archaeology. 3rd ed. New York: Routledge; 2015.
4. Dervenis K, Lykiardopoulos N. The Martial Arts of Ancient Greece: Modern Fighting Techniques from the Age of Alexander. Merrimac, MA: Destiny Books; 2007.
5. Nutton V. Greek medicine dissected. *Hist Sci.* 1974;12(1):59-69. doi: 10.1177/007327537401200105.
6. Toledo-Pereyra LH. Claudius Galenus of Pergamum: surgeon of gladiators. Father of experimental physiology. *J Invest Surg.* 2002;15(6):299-301. doi: 10.1080/08941930290086100.
7. Bujalkova M. Rufus of Ephesus and his contribution to the development of anatomical nomenclature. *Acta Med Hist Adriat.* 2011;9(1):89-100.
8. Daremberg C, Ruelle C, editors. On the appellations of the human body, Work of Rufus of Ionia [in Latin]. Amsterdam: Hakkert; 1963.
9. Liddel HG, Scott R. A Greek-English lexicon. Oxford: Clarendon Press; 1940.
10. Kakkert CG, editors. On the dissection of nerves[in Latin]. Hildesheim: Olms; 1964.
11. Helmreich G. Galen on the use of parts of book xvii [in Latin]. Leipzig: Teubner; 1907.
12. The Five Books of Theophilus Protospatharius on the Construction of the Human Body. *Br Foreign Med Rev.* 1843;15(30):439-54.
13. Greenhill GA. Theophilus Protospatharius on the structure of the human body, book v [in Latin]. Oxford: Oxford University Press; 1842.
14. Sakai T. Historical evolution of anatomical terminology from ancient to modern. *Anat Sci Int.* 2007;82(2):65-81. doi: 10.1111/j.1447-073X.2007.00180.x.
15. Dubrovin IA, Dubrovin AI. Study of morphometric parameters of the hyoid bone [in Russian]. *Sud Med Ekspert.* 2021;64(6):34-8. doi: 10.17116/sudmed20216406134.
16. Persaud TVN, Loukas M, Tubbs RS. A History of Human Anatomy. 2nd edition. Springfield Illinois U.S.A.: Charles C. Thomas Publisher; 2014.