

The Clinical and Radiological Evaluation of Impacted Third Molar Position, Crown and Root Morphology

Naida Hadziabdic^{1, a}, Aida Dzankovic², Madzda Maktouf³, Irmina Tahmiscija², Lajla Hasic-Brankovic², Samra Korac², Amila Haskic¹

¹Department of Oral Surgery, University of Sarajevo-Faculty of Dentistry with Dental Clinical Center, Bosnia and Herzegovina, ²Department of Restorative Dentistry with Endodontics, University of Sarajevo-Faculty of Dentistry with Dental Clinical Center, Bosnia and Herzegovina, ³Dr Madzda Maktouf Dental Clinic, Luka 14, Travnik, Bosnia and Herzegovina

Correspondence: nsulejma@yahoo.com; Tel.: +387 61 157132

Received: 16 June 2023; **Accepted:** 8 August 2023

Abstract

Objective. This study aimed to analyze the crown and root morphology of maxillary and mandibular third molars, and assess their position in relation to adjacent anatomical structures using clinical examination and radiographic images. **Materials and Methods.** A total of 176 extracted impacted or partially impacted third molars were included in this study. Orthopantomogram images (OPG) were used to evaluate the number of roots, position, depth of impaction relative to the occlusal plane of the second molar, and angulation of maxillary and mandibular third molars. The extracted teeth were examined to determine the actual number of roots. The root morphology was classified using the Alavi classification system for maxillary third molars and the Machado classification for mandibular third molars. Additionally, the number of cusps, crown dimensions, and morphology were analyzed using digital and dental calipers. **Results.** The extracted samples exhibited a significantly higher number of roots compared to the number assessed on OPG images ($P < 0.001$). The majority of mandibular third molars had two fused roots (37.39%) and a five-cuspid crown (48.70%), while maxillary third molars had three fused roots (26.23%) and four cusps (42.62%). Both maxillary (60.66%) and mandibular third molars (61.74%) were predominantly vertically positioned. Regarding the depth of impaction, maxillary third molars were primarily classified as Class C (65.57%), while mandibular third molars were classified as Class B (47.83%). Differences in crown shape were observed, with maxillary crowns being mostly triangular (36.07%) and mandibular crowns being oval (38.26%). Maxillary third molars had shorter crowns compared to mandibular third molars ($P < 0.05$). **Conclusion.** The root morphology of maxillary and mandibular third molars in the population of Bosnia and Herzegovina displays variability. Orthopantomogram imaging was found to be inadequate for accurate determination of the number of roots in third molars. The number of cusps on third molars cannot be relied upon as a predictor of the number of roots. The study's findings will have implications for dental practice, particularly for oral surgeons and restorative dentists.

Key Words: Wisdom Teeth ▪ Impacted Third Molar ▪ Root Morphology ▪ Crown Morphology ▪ Depth Of Impaction.

Introduction

The impaction of third molars is considered a developmental feature of modern civilization that occurs due to a lack of space for their eruption, the presence of physical barriers that prevent them from reaching the occlusal plane, and malposition (1).

It is well known that third molars are characterized by morphological complexity and that their place within the dental arch affects almost all dental disciplines (2, 3). Their distal position and enhanced fissure system contribute to plaque retention and the development of caries, which consequently leads to the need for tooth restoration and endodontic treatment (4). From a dental prosthetic point of view, they can act as abutments for fixed prosthetic restorations (5). Difficulties

^aORCID ID <https://orcid.org/0000-0003-4808-703X>

with the eruption of third molars and their often irregular position in the oral cavity can affect the results of orthodontic treatment and lead to periodontal disease (6). In oral surgery, it is of great importance to be familiar with the morphological characteristics of third molars, as their operative extraction is one of the most common oral-surgical interventions (7). Both clinical and radiographic evaluation of the position of the third molars should be performed to reduce complications and achieve the best possible outcome. To the best of our knowledge, this is the first study that addresses the morphology of impacted and partially impacted third molars in the population of Bosnia and Herzegovina.

Therefore, the goals set for this study were to analyze the number and morphology of maxillary and mandibular third molar roots, the morphology and dimensions of their crowns, and their position regarding adjacent anatomic structures, using clinical examination and radiographic images.

Materials and Methods

The Sample

The patients were recruited from the Department of Oral Surgery, University of Sarajevo, Faculty of Dentistry with Dental Clinical Center, and they submitted signed informed consent forms after being introduced to the details of the study. With the exception of samples with crowns and roots damaged during operative extraction, fractured roots, and incomplete root and crown development, all intact, surgically extracted, impacted or partially impacted third molars were included in the study. Initially, 176 third molars (61 maxillary and 115 mandibular) were included in the study. The total sample size was drawn from 140 patients, with the youngest being 14 years old and the oldest being 59 years old (39 men and 101 women). The extracted teeth were stored in a 3% solution of sodium hypochlorite (NaOCl).

Analysis of the Orthopantomogram Images

OPG images were used to determine the number of roots, the position of the third molars, the depth

of their impaction measured in relation to the occlusal plane of the second molars, and the angulation of the maxillary and mandibular third molars (8-10). Orthopantomogram imaging was also used preoperatively to assess the number of roots of impacted and partially impacted third molars. The samples were divided into three categories: Group 1 had a single root, Group 2 had two roots, and Group 3 had three roots.

Analysis of the Number and Morphology of the Roots of Extracted Impacted or Partially Impacted Third Molars

The extracted teeth were used to determine the real number of roots. On the basis of the data acquired, the sample was divided into 4 groups: Group 1 had a single root, Group 2 had two roots, Group 3 had three roots, and Group 4 had four roots.

In terms of morphology and the number of roots, maxillary third molars were classified using the Alavi classification system, while mandibular third molars were classified using the Machado classification (11, 12). In detail, the Alavi classification divides upper wisdom teeth into ten classes based on the number and shape of their roots (I- three roots: all separate, II- three roots: Buccal roots fused, III- three roots: Distobuccal and palatal fused, IV- three roots: all fused, V- two roots separate, VI- two roots fused, VII- one root conical, VIII- one root C shaped, IX- four roots fused, X- four roots other (11). According to root morphology, the Machado classifies mandibular third molars as convergent, parallel, fused, single, or divergent (12).

Analysis of the Crown Morphology of Impacted and Partially Impacted Third Molars

The samples were used to analyze the number of cusps and the shape of the crown. The shape of the crown was classified according to the geometric figure it resembled: oval, cubic, rectangular, rhomboid, circular, triangular, and trapezoidal (13).

Metric Analyses of the Samples

Metric analyses were performed using a stereomicroscope (Kern Opticus OZL 464) at 15x

magnification. The samples were photographed using a Kern Opticus ODC 824 camera, and digital images were stored in JPEG format. The digital caliper was calibrated and adjusted before each measurement on the basis of the calibration block, which is an integral part of the Kern Opticus OZL 464, in accordance with the manufacturer's instructions. In other words, the distance measured by the digital caliper must correspond to the distance measured by two points on the calibration block. JPEG images of the third molars were used to measure the length of the third molar roots, the mesiodistal (MD) diameter, and the buccolingual (BL) diameter of the crown, using a digital caliper. The "single line" option was used to measure the crown's MD and BL diameters, while the "poly-line" software option was used to measure the length of the roots, due to their variable morphology and curvature. The measurements were given in millimeters.

A dental caliper was used to measure the dimensions of the extracted teeth: crown length (from the crest of the buccal cusp or cusps to the crest of curvature at the cemento-enamel junction), root length (from the crest of curvature at the crown cervix to the apex of the root), tooth length (from the crest of the buccal cusp or cusps to the apex of the root), the MD diameter of the tooth crown (from the crest of the curvature on the mesial surface (mesial contact area) to the crest of the curvature on the distal surface (distal contact area)), the MD diameter of the crown cervix (from the junction of the crown and root on the mesial surface to the junction of the crown and root on the distal surface), the BL diameter of the crown (from the crest of the curvature on the buccal surface to the crest of the curvature on the lingual surface), and the BL diameter of the crown cervix (from the junction of the crown and root on the buccal surface to the junction of the crown and root on the lingual surface) (14). The measurements were also given in millimeters.

Ethics Statement

The study was approved by an Institutional Ethical Review Board (No. 02-3-4-59-1-4/2021).

Statistical Analysis

Descriptive analysis was used to describe and present the characteristics and dimensions of the upper and lower third molars. Continuous variables were presented as means with standard deviations, and categorical variables were presented as percentages. Additionally, t-tests and one-way ANOVAs (analysis of variance) were conducted. Statistical analyses were performed using IBM SPSS software, version 23 (Chicago IL).

Results

Patients who underwent surgery were both male and female, with a mean age of 22.8, SD 6.47.

Out of the 176 third molars included in the study (61 maxillary and 115 mandibular), 89 were impacted and 87 were partially impacted. The frequency of upper and lower third molars in relation to diagnosis, angulation, crown and root morphology, and depth of impaction is shown in Table 1 (A and B).

Root Morphology

According to the Alavi classification for upper third molars, the most frequent finding for upper third molars is a fusion of three roots (Class IV) (Table 1 A). The Machado classification system states that the fusion of roots is the most common finding for lower third molars (Table 1 B).

The number of roots found on OPG images and the number of roots detected on extracted teeth is shown in Figure 1. The dependent samples t-test showed a statistically significant difference between the average number of roots found on OPG and the actual number of roots, i.e., a statistically significant greater number of roots was found on the extracted third molars than on OPG images, $t(175) = -10.776$; $P < 0.001$. The range of the average dimensions of the maxillary and mandibular third molars measured by dental and digital calipers (DC) can be found in Table 2.

Table 1. Descriptive Statistical Parameters: Diagnosis, Angulation, Crown Shape, and Depth of Impaction of Maxillary and Mandibular Third Molars

A Maxillary third molars									
Diagnosis N (%)	Angulation N (%)		Shape of the crown N (%)		Root morphology according to Alavi N (%)		Depth in relation to occlusal plane N (%)		
Impacted	39 (63.93)	Vertical	37 (60.66)	Oval	7 (11.47)	Class I	4 (6.55)	A	6 (9.84)
		Mesioangular	14 (22.95)	Cubic	2 (3.28)	Class II	5 (8.20)	B	15 (24.59)
Partially impacted	22 (36.07)	Distoangular	9 (14.75)	Rectangular	1 (1.64)	Class III	12 (19.67)	C	40 (65.57)
		Horizontal	-	Rhomboid	19 (31.15)	Class IV	16 (26.23)		
		Linguoangular	-	Circular	4 (6.55)	Class V	2 (3.28)		
		Buccoangular	1 (1.64)	Triangular	22 (36.07)	Class VI	2 (3.28)		
				Trapezoidal	6 (9.84)	Class VII	4 (6.55)		
						Class VIII	3 (4.92)		
						Class IX	6 (9.84)		
				Class X	7 (11.48)				
Total	61 (100)	Total	61 (100)	Total	61 (100)	Total	61(100)	Total	61 (100)
B Mandibular third molars									
Diagnosis N (%)	Angulation N (%)		Shape of the crown N (%)		Root morphology according to Machado N (%)		Depth in relation to occlusal plane N (%)		
Impacted	50 (43.48)	Vertical	71 (61.74)	Oval	44 (38.26)	Convergent	16 (13.91)	A	39 (33.91)
		Mesioangular	32 (27.82)	Cubic	19 (16.52)	Parallel	25 (21.73)	B	55 (47.83)
Partially impacted	65 (56.52)	Distoangular	4 (3.48)	Rectangular	12 (10.43)	Fused	43 (37.39)	C	21 (18.26)
		Horizontal	3 (2.61)	Rhomboid	4 (3.48)	Single	4 (3.47)		
		Linguoangular	5 (4.35)	Circular	7 (6.09)	Dilaceration	19 (16.52)		
		Buccoangular	-	Triangular	5 (4.35)	Divergent	8 (6.95)		
				Trapezoidal	24 (20.87)				
Total	115 (100)	Total	115 (100)	Total	115 (100)	Total	115 (100)	Total	115 (100)

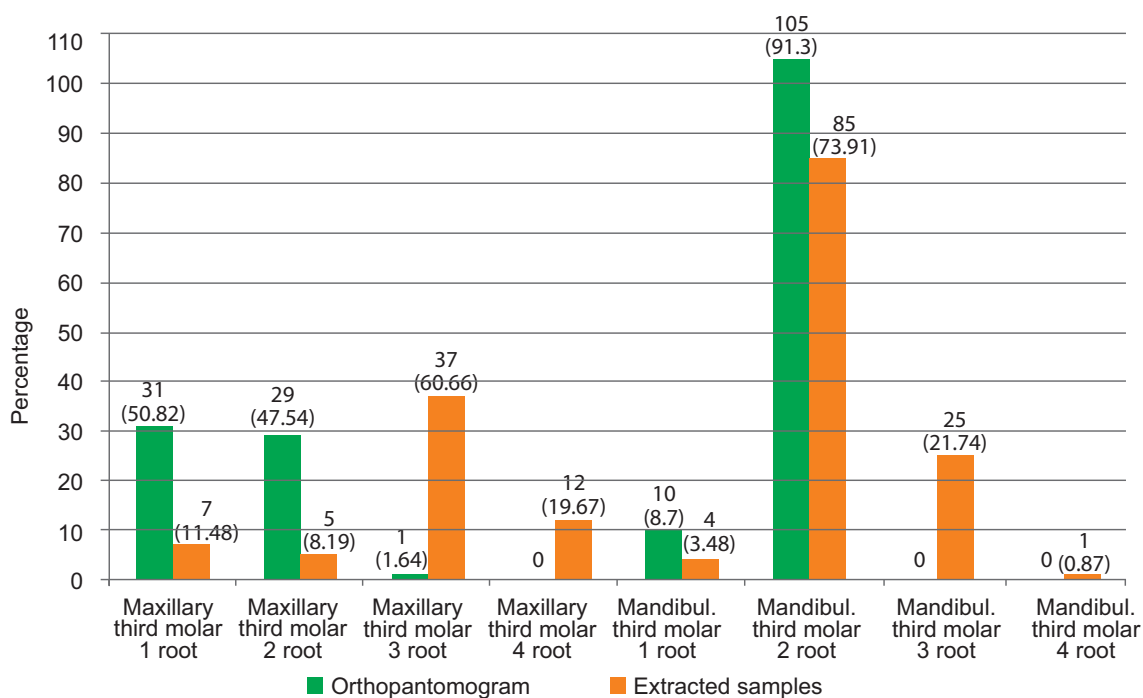


Figure 1. The frequencies of the number of roots of the upper and lower third molars based on the orthopantomogram and extracted samples.

Table 2. Upper and Lower Third Molar Average Dimensions in mm Measured with a Dental and Digital Caliper

Dimension	Maxillary third molars (mm)	Mandibular third molars (mm)	P
Total length	17.86	18.11	>0.05
Length of the crown	7.23	7.65	<0.05 [†]
Length of the root	10.76	10.71	>0.05
Mesiodistal diameter of the crown	9.53	9.70	>0.05
Mesiodistal diameter of the crown at the cervix	9.07	8.97	>0.05
Buccolingual diameter of the crown	8.61	8.63	>0.05
Buccolingual diameter of the crown at the cervix	8.27	7.93	>0.05
Length of the root DC	10.65	10.52	>0.05
Mesiodistal diameter of the crown DC*	9.38	9.57	>0.05
Buccolingual diameter of the crown DC*	8.47	8.50	>0.05

*Digital caliper; [†]Independent samples t-test.

The Average Dimensions of Lower Third Molars in Comparison to the Available Space between the Mandibular Ramus and Second Molar

The position of third molars according to the Pell and Gregory classification is shown in Table 3. One-way between group ANOVA analysis showed a statistically significant difference in the mesiodistal diameter of the crown of lower third molars (measured with a dental caliper) within the Pell and Gregory classes, $F(2, 105)=5.016$; $P<0.01$. The post hoc Scheff test revealed a distinction between classes I and III. The mean mesiodistal diameter of the crown in class I ($M=9.51$; $SD=0.91$) was smaller than the mean mesiodistal diameter of the class III crown ($M=10.50$; $SD=0.96$), $P=0.023$.

One-way between group ANOVA revealed a statistically significant difference in the mesiodistal diameter of the crowns measured with a digital caliper for the Pell and Gregory classes, $F(2, 105)=5.706$; $P<0.01$. The post hoc Sheff test revealed differences between classes I and II, as well as classes I and III. The mean mesiodistal diameter of the class I crowns ($M=9.34$; $SD=0.83$) measured with a digital caliper was significantly smaller than the mean mesiodistal diameter of the class II crowns ($M=9.80$; $SD=0.83$), $P=0.038$. The mean mesiodistal diameter of the class I crowns measured with a digital caliper was smaller than the mean mesiodistal diameter of the class III crowns ($M=10.37$; $SD=0.97$) $P=0.016$ (Table 3).

Table 3. Average Dimensions of Lower Third Molars in mm with Respect to Pell and Gregory's Classification

Dimension	Pell & Gregory's classification of mandibular third molars			P
	Class I (N=32)	Class II (N=76)	Class III (N=7)	
Total length	17.87	18.40	20.00	>0.05
Length of the crown	7.47	7.93	7.86	>0.05
Length of the root	11.19	10.52	11.80	>0.05
Mesiodistal diameter of the crown	9.52	9.94	10.50	<0.01 [†]
Mesiodistal diameter of the crown at the cervix	8.73	9.10	9.00	>0.05
Buccolingual diameter of the crown	8.54	8.68	9.14	>0.05
Buccolingual diameter of the crown at the cervix	7.80	8.14	8.28	>0.05
Length of the root DC	10.66	10.47	11.77	>0.05
Mesiodistal diameter of the crown DC*	9.34	9.81	10.37	<0.01 [†]
Buccolingual diameter of the crown DC*	8.46	8.38	9.10	>0.05

*Digital caliper; [†]One-way between groups ANOVA.

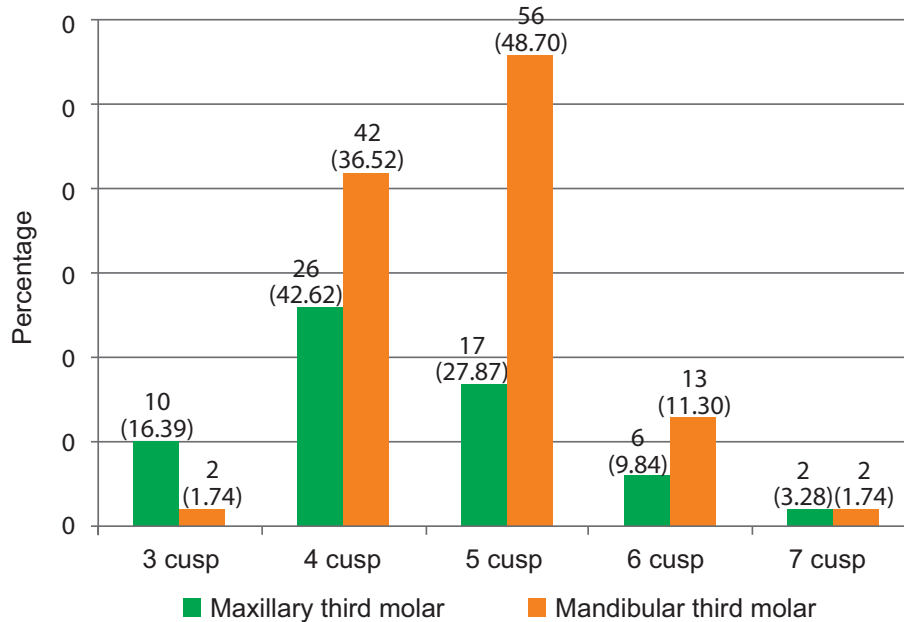


Figure 2. The frequency and percentages of the number of cusps of upper and lower third molars.

Crown Dimensions of the Third Molars

Using an independent samples t-test, measurements with a dental caliper revealed a statistically significant difference in the crown length of the upper and lower third molars. The crown of the upper third molars was smaller than the crown of the lower third molars: $t(174)=-2.277$; $P<0.05$ (Table 2).

The Number of Cusps and Crown Shape

The analysis of the number of cusps on the occlusal surface of third molars established five types of cusp morphology: Type-1 (three cusps), Type-2 (four cusps), Type-3 (five cusps), Type-4 (six cusps), and Type-5 (seven cusps). Type-2 was most often found in the upper third molars, while Type-3 was most commonly found in the lower third molars (Figure 2).

Maxillary third molars were found most often to have a triangular crown shape. The crowns of the lower third molars were mostly oval (Table 1). An analysis of the relationship between the number of cusps and the number of roots revealed that third molars with three cusps usually had three

roots, whereas third molars with 4, 5, 6, and 7 cusps mostly had two roots (Table 4).

Table 4. The Relationship between the Number of Cusps and the Number of Roots of the Upper and Lower Third Molars

Cusps	Number of roots			
	One	Two	Three	Four
Three	3	2	6	1
Four	6	35	24	3
Five	2	40	25	6
Six	0	10	7	2
Seven	0	3	0	1

Discussion

The population of Bosnia and Herzegovina has not been the subject of any analysis of the third molar crown and root morphology. Our study encompasses an equal number of impacted and partially impacted third molars, mostly vertically positioned, that were mainly extracted for orthodontic reasons.

This study included 176 extracted maxillary and mandibular third molars from adults of both genders. A fusion of three roots was the most

common finding for upper-third molars. Root fusion was the most common finding in lower third molars as well. The number of roots detected on extracted third molars was found to be statistically significantly greater than the number of roots seen on OPG images. The mesiodistal diameter of the crown of lower third molars differed significantly between the Pell and Gregory classes. When measured with a dental caliper and a digital caliper, Class I had a smaller mean mesiodistal diameter than Class III. The upper third molar crown was found to be statistically significantly smaller than the lower third molar crown. Type-2 (four cusps) was more common in upper third molars, and Type-3 (five cusps) was more common in lower third molars. Lower third molars were mostly oval, while maxillary third molars were mostly triangular. Third molars with three cusps typically had three roots, whereas third molars with four, five, six, or seven cusps typically had two roots.

Depth of Impaction

From an oral surgeon's point of view, it is important to assess the depth of impaction accurately. The deeper the maxillary or mandibular third molar is placed within the jaw, the more complex the procedure. Our research showed that impacted upper third molars are usually in Class C (65.57%) and rarely in Class A (9.84%). Lower third molars were most commonly found in mid-deep position, Class B (47.83%) and least frequently in Class C (18.26%) (Table 1). This is in accordance with the findings of Khoury et al., who analyzed the depth of third molar impaction in the population of Lebanon (15). This outcome is contrary to that of Carvalho et al., which may be due to the larger sample size of their study. They analyzed 473 mandibular molars and found that they were in Class A in 48.4% of cases, Class B in 41% of cases, and Class C in 10.6% of cases (16).

Root Morphology

One of the reasons for the complexity of third molar extraction is the variability of their root

morphology, which has been the subject of many studies (11–13,17,18). Alavi et al. investigated maxillary third molars in a Thai population and established seven classes: Class I 50.9%; Class II 10.6%; Class IV 26.5%; Class VI 6.6%; Class VII 1.3%; Class IX 2%; and Class X 2%, while the remaining three classes (III, V and VIII) were not present in the sample (11). In our study of 61 maxillary third molars, fusion was present in 26.23% of cases, while the rest were divided among the other classes (Table 1). Compared to the results of Alavi et al., similarity can only be noticed in Class IV. The results of our study in terms of root number and morphology were mostly in line with the study by Todor et al. They classified the morphology and the number of third molar roots into seven categories, with three fused roots being the most common (43.75%), as in our study (13). In their study of the Croatian population (56 maxillary third molars), Ćosić et al. discovered root fusion in 19 samples (33.9%) while the rest of the sample had independent roots (17). However, the comparison between studies would be more accurate if the criteria for the number of roots and their fusion were standardized.

The root morphology of lower third molars is also variable. Our study comprised a larger number of samples (N=115), and found that most mandibular third molars had fused roots (37.39%), followed by parallel roots (21.73%). Machado et al. studied 48 mandibular third molars, and discovered single and fused roots in 27.1% of samples, parallel in 33.3%, convergent in 35.4%, and divergent in 4.2% of cases (12). In contrast, no roots showed fusion in the study of a sample of 50 mandibular molars collected from a Croatia population (17). Since the Bosnian-Herzegovinian and Croatian populations are geographically close and not expected to differ to any great extent, this result may be a reflection of differences in the sample size. Saraswati et al. used a simpler root classification in their study of 100 mandibular molars. They classified mandibular third molar root morphology into three groups: group I —roots with normal morphology (12%); group II —fused roots (7%); group III —curved roots (81%) (18). This differs

from the results of our study. While curved roots were dominant in their study, our sample showed the greatest percentage of fused roots of mandibular third molars.

Root Number

OPG was primarily used as a radiographic tool in preparation for surgical third molar extraction. The number of roots was counted as part of our analysis. To evaluate the accuracy of the OPG assessment, the number of roots found in the OPG images was compared to the number of roots found on the extracted specimen. Our analysis of OPG images showed that maxillary third molars mostly had a single root (50.82%), while lower third molars predominately showed two roots (91.30%). Furthermore, the extracted specimens revealed three roots in the upper third molars (60.66%) and two roots in the lower third molars (73.91%). A statistically significant difference between the number of roots assessed using OPG images and the actual number of roots is evident ($P < 0.001$). In their study of the precision of three imaging techniques in assessing the number of roots of mandibular wisdom teeth, Matzen et al. found no statistically significant difference (19). They used OPG images to analyze 139 mandibular third molar root numbers, and CBCT images and stereoscanometry to examine 147 mandibular third molars. The results showed the equal reliability of the three techniques when assessing the number of third molar roots (19). Zhang et al. investigated 130 maxillary and mandibular third molars using micro-computed tomography. The results of their study on a Chinese population showed that upper third molars mostly had one root (51.5%) and lower third molars were usually two-rooted (47.7%) (20). Our results follow theirs in terms of mandibular third molar root count. Ćosić et al. examined 106 third molars, 56 maxillary and 50 mandibular teeth in Croatians. In their study, Croatians mostly had three-rooted upper third molars (83.9%), as in our study, while lower third molars mostly had single roots (56%) (17). Unlike their study, the population from B&H had predominantly two-rooted

lower third molars. Our study had twice the sample size, which could be a reason for the discrepancy between two geographically close nations. By analyzing CBCT images, Park et al. discovered that a Korean population mostly had two-rooted mandibular third molars (56.5%), then one (37.9%), and three roots (1.9%) (21). As in our population, two rooted mandibular third molars were found most often.

In a study by Bell et al. from the United Kingdom, the number of roots was analyzed on the basis of OPG scans, and the accuracy of the OPG scan in estimating the actual number of roots was assessed. The results of that study showed a statistically significant difference between the number of roots shown on OPG and the actual root number, which brings the reliability of OPG into question (22). Our results confirm the results of Bell et al., especially in terms of assessment of the number of maxillary third molar roots. Although OPG is routinely used preoperatively, it has low diagnostic accuracy and is not a good tool to assess root number and curvature.

The number of roots in the B&H population ranged from one to four for the maxillary and mandibular third molars. In his review article, Ahmed demonstrated that maxillary third molars may have one to five roots, and mandibular one to four roots (5). In the American study by Sidow et al., 17% of mandibular molars had one root, 77% had two roots, 5% had three roots, and 1% had four roots. Out of 150 maxillary third molars, 15% had one root, 32% had two roots, 45% had three roots, and 7% had four roots (3). In accordance with the present results, lower third molars were mostly two-rooted, and upper third molars were three-rooted.

The Position of Third Molars

One of the characteristics of impacted third molars assessed preoperatively using OPG images is their position within the jaw bone, most commonly according to Winter's classification. Winter classified third molars on the basis of their inclination towards the long axis of the second molar

as vertical, horizontal, distoangular, mesioangular, transversal, or inverse (8). In our sample, vertical angulation was found most frequently in the maxilla (60.66%) and mandible (61.74%), followed by mesioangular, linguoangular, distoangular, and horizontal angulation. (Table 1). The results of our study are in accordance with the results of Carvalho et al., who analyzed 473 mandibular third molars and found them predominantly in a vertical position (49.5%) (16). Meanwhile, Bokindo et al., established that mandibular third molars were mostly in a mesioangular position (21.9%), followed by horizontal (2.9%), vertical (1.3%), and distoangular positions (1%) (23). Sampieri et al. also found the mesioangular position to be the most frequent (53.8%) in their sample of Brazilians (N=1205 mandibular third molars) (7). In their study of 181 upper and lower third molars in a population from Lebanon, Khouri et al. found the most mesioangularly positioned third molars, followed by the distoangular, horizontal, and vertical positions (15).

Crown Dimensions of Third Molars

A discrepancy between tooth size and available space is a possible etiological factor for impaction or partial impaction. The present study compared the crown dimensions of third molars with the available space in the sampled B&H population. A statistically significant difference between the crown length of maxillary and mandibular third molars was found, while there was no difference between their root lengths (Table 2). Our results agree with the results of Zhang et al. in a Chinese population (20). It is evident from odontometric measurements that Chinese people have shorter crowns than Bosnians (20). Ahmed et al. also studied the average dimensions of third molars, and noticed the length of third molars to be 14 mm to 22 mm, with an average of 17–19 mm (5). In our study, the average length of maxillary third molars was 17.86 mm, and the average length of mandibular third molars was 18.1 mm. The clinical importance of these measurements is that they may be helpful when choosing the length of instruments during endodontic treatment.

The Average Dimensions of Lower Third Molars in Comparison to the Available Space between the Mandibular Ramus and Second Molar

The average dimensions of lower third molars were compared in relation to Pell and Gregory's classification of the position of lower third molars, i.e., the available space between the mandibular ramus and the second molar. We discovered a significant difference in the mesiodistal diameter of the crowns between Pell and Gregory's Classes I, II, and III. The mesiodistal diameter of the crowns of the lower third molars in Class I was notably smaller than the MD diameter of the crowns of the third molars in Classes II and III (Table 3). This was an attempt to see if tooth dimensions lead to the occurrence of impaction or partial impaction. In a recent study, Orafi et al. questioned the connection between the MD diameter of the crown of third molars and the available space for their eruption (24). This study found three categories by size (the impacted tooth's mesiodistal diameter in relation to its normal space). S1: the MD diameter is lower than the available space for the third molar eruption; S2: the MD diameter is greater than the available space for the third molar eruption; and S3: the MD diameter equals the available space for the third molar eruption (24). Our results are in agreement with the results of Orafi et al. and can be used to assess the possibility of the eruption of third molars. For accurate measurement of unerupted teeth, a 3D imaging technique such as CBCT should be used (24).

Crown Morphology

The study established seven types of crown morphology with regard to the geometric shape it resembles. The occlusal surface of the maxillary third molars was mainly triangular, while the occlusal surface of the mandibular third molars was mostly oval. This differs from the results of a study by Todor et al. in Romanians, who found six possible geometric shapes of maxillary third molars, with the rectangular shape being dominant (28.18%).

Conversely, this shape was the least common in our study (1.64%). This suggests that there are differences in the crown morphology of maxillary third molars between different populations (13). In our analysis of the relationship between the root number and the number of cusps on the occlusal surface of the third molars, we established the following: a three-cuspid crown is usually followed by three roots, while crowns with four, five, six, and seven cusps are usually followed by two roots. This suggests that the number of cusps is not a reliable indicator of the root number.

Study Limitations and Future Research Suggestions

Considering that our study was based on the morphology of crowns and roots, our sample had to be intact. As a result, many of the samples were ineligible due to mechanical defects, or their position necessitated operative separation. This was mostly the case with horizontally positioned lower third molars and molars in unusual positions that could not be extracted as a whole. This affected the results concerning the position of mandibular third molars. For future research, it would be interesting to note all the positions of third molars that require separation in order to be extracted. This would be especially helpful to inexperienced oral surgeons, as it would assist them in deciding when to separate the tooth during the procedure.

Fi - Index Tool

This manuscript has been checked with the Fi-index tool and obtained a score of 0.20 for the first author only on the date 24 July 2023 according to SCOPUS[®] (25). The fi-index tool aims to ensure the quality of the reference list and limit any auto-citations.

Conclusion

Orthopantomogram imaging is not a precise diagnostic method to assess the third molar root count. Our study of a Bosnian and Herzegovina

population showed that maxillary third molars usually had three fused roots (Alavi Class IV), while mandibular third molar roots were mostly fused. Both maxillary and mandibular third molars were mostly vertically positioned. Lower third molars were typically classified as Pell and Gregory Class II. The crowns of upper and lower third molars differ in shape: mandibular third molar crowns are mostly oval, and maxillary crowns are triangular. The number of cusps on the upper and lower third molars cannot be used to predict the number of roots. Knowing the morphological characteristics of wisdom teeth as well as their position is important for clinical practice in assessing the potential risk of impaction, difficulty of extraction, and increased susceptibility to caries and periodontal disease.

What Is Already Known on This Topic:

Various classifications and scoring systems have been identified in studies to categorize impacted third molars on the basis of their position and degree of impaction. These classifications aid in treatment planning and extraction decision-making. Radiological evaluation also aids in determining the relationship between the impacted tooth and adjacent structures, which is important for surgical planning and lowering the risk of complications. Furthermore, assessing crown and root morphology helps predict extraction difficulty, determine the need for preoperative procedures, such as sectioning or bone removal, and to identify the risk of postoperative complications. Overall, clinical and radiological evaluation is important in assessing impacted third molars, facilitating personalized treatment plans, and reducing associated risks and complications.

What This Study Adds:

The prevalence, eruption patterns, and anatomical characteristics of wisdom teeth differ between ethnic groups and populations. This is the first study of wisdom teeth in the Bosnian and Herzegovinian population, and it focuses on wisdom tooth position, as well as crown and root morphology. This study's findings will have an impact on dental care and treatment decisions in the fields of oral surgery, restorative dentistry, and endodontics.

Acknowledgement: The authors would like to thank Ariel Nikitovic, for help in statistical analysis and interpretation of data.

Authors' Contributions: Conception and design: NH and MM; Acquisition, analysis, and interpretation of data: NH, ADZ, MM, SK and AH; Drafting the article: NH, ADZ, MM, SK, IT, LBH and AH; Revising it critically for important intellectual content: NH, ADZ, MM, SK, IT, LBH and AH; Approved final version of the manuscript: NH, ADZ and SK.

Conflict of Interest: The authors declare that they have no conflict of interest.

References

1. Patel S, Mansuri S, Shaikh F, Shah T. Impacted Mandibular Third Molars: A Retrospective Study of 1198 Cases to Assess Indications for Surgical Removal, and Correlation with Age, Sex and Type of Impaction—A Single Institutional Experience. *J Maxillofac Oral Surg.* 2017;16(1):79-84. doi: 10.1007/s12663-016-0929-z. Epub 2016 Jun 10.
2. Mohammadi Z, Jafarzadeh H, Shalavi S, Bandi S, Patil S. Root and Root Canal Morphology of Human Third Molar Teeth. *J Contemp Dent Pract.* 2015;16(4):310-3. doi: 10.5005/jp-journals-10024-1681.
3. Sidow SJ, West LA, Liewehr FR, Loushine RJ. Root Canal Morphology of Human Maxillary and Mandibular Third Molars. *J Endod.* 2000;26(11):675-8. doi: 10.1097/00004770-200011000-00011.
4. Vandeplas C, Vranckx M, Hekner D, Politis C, Jacobs R. Does Retaining Third Molars Result in the Development of Pathology Over Time? A Systematic Review. *J Oral Maxillofac Surg.* 2020;78(11):1892-908. doi: 10.1016/j.joms.2020.06.014. Epub 2020 Jun 15.
5. Ahmed HM. Management of third molar teeth from an endodontic perspective. *Eur J Gen Dent.* 2012;1(3):148-60.
6. Zhang Y, Chen X, Zhou Z, Hao Y, Li H, Cheng Y, et al. Effects of Impacted Lower Third Molar Extraction on Periodontal Tissue of the Adjacent Second Molar. *Ther Clin Risk Manag.* 2021;17:235-47. doi: 10.2147/TCRM.S298147.
7. da Silva Sampieri M, Viana F, Cardoso C, Vasconcelos M, Vasconcelos M, Gonçalves E. Radiographic study of mandibular third molars : evaluation of the position and root anatomy in Brazilian population. *Oral Maxillofac Surg.* 2018;22(2):163-8. doi: 10.1007/s10006-018-0685-y. Epub 2018 Feb 15.
8. Miclotte A, Grommen B, De Llano-Perula MC, Verdonck A, Jacobs R, Willems G. The effect of first and second premolar extractions on third molars: A retrospective longitudinal study. *J Dent.* 2017;1(61):55-66. doi: 10.1016/j.jdent.2017.03.007. Epub 2017 Mar 27.
9. Pell GJ, Gregory BT. Impacted mandibular third molars; classification and modified techniques for removal. *Dent Dig.* 1933;39:330-8.
10. Lim AA, Wong CW, Allen Jr JC. Maxillary third molar: Patterns of impaction and their relation to oroantral perforation. *J Oral Maxillofac Surg.* 2012;70(5):1035-9. doi: 10.1016/j.joms.2012.01.032. Epub 2012 Apr 10.
11. Alavi AM, Opananon A, Ng YL, Gulabivala K. Root and canal morphology of Thai maxillary molars. *Int Endod J.* 2002;35(5):478-85. doi: 10.1046/j.1365-2591.2002.00511.x.
12. Har H, Braga C, Feres M. Preoperative evaluation of third molar root characteristics: Correlation between clinical and radiographic findings. *Revista Odonto Ciência.* 2015;30(4):111-4.
13. Todor L, Matei RI, Muțiu G, Porumb A, Ciavoi G, Cuc EA, et al. Morphological study of upper wisdom tooth. *Rom J Morphol Embryol.* 2018;59(3):873-7.
14. Nelson S. Wheeler's dental anatomy, physiology and occlusion, 10th edition. St. Louis, Missouri: Elsevier Saunders; 2015. p. 350.
15. Khouri C, Aoun G, Khouri C, Saade M, Salameh Z, Berberi A. Evaluation of Third Molar Impaction Distribution and Patterns in a Sample of Lebanese Population. *J Maxillofac Oral Surg.* 2022;21(2):599-607. doi: 10.1007/s12663-020-01415-x. Epub 2020 Jul 16.
16. Carvalho RWF, Do Egito Vasconcelos BC. Assessment of factors associated with surgical difficulty during removal of impacted lower third molars. *J Oral Maxillofac Surg.* 2011;69(11):2714-21. doi: 10.1016/j.joms.2011.02.097. Epub 2011 Jul 12.
17. Ćosić J, Galić N, Vodanović M, Njemirovskij V, Šegović S, Pavelić B, et al. An in vitro morphological investigation of the endodontic spaces of third molars. *Coll Antropol.* 2013;37(2):437-42.
18. Saraswati F, Balajirao B, Mamatha G. Clinical and orthopantomographic evaluation of mandibular third molar. *Contemp Clin Dent.* 2010;1(1):27-30. doi: 10.4103/0976-237X.62518.
19. Matzen LH, Christensen J, Hintze H, Schou S, Wenzel ANN. Diagnostic accuracy of panoramic radiography , stereo-scanography and cone beam CT for assessment of mandibular third molars before surgery. *Acta Odontol Scand.* 2013;71(6):1391-8. doi: 10.3109/00016357.2013.764574. Epub 2013 Jan 29.
20. Zhang W, Tang Y, Liu C, Shen Y, Feng X, Gu Y. Root and root canal variations of the human maxillary and mandibular third molars in a Chinese population: A micro-computed tomographic study. *Arch Oral Biol.* 2018;95:134-40. doi: 10.1016/j.archoralbio.2018.07.020. Epub 2018 Aug 8.
21. Park JB, Kim NR, Park S, Ko Y. Evaluation of number of roots and root anatomy of permanent mandibular third molars in a Korean population, using cone-beam computed tomography. *Eur J Dent.* 2013;7(3):296-301. doi: 10.4103/1305-7456.115413.
22. Bell GW, Rodgers JM, Grime RJ, Edwards KL, Hahn MR, Dorman ML, et al. The accuracy of dental panoramic tomographs in determining the root morphology of mandibular third molar teeth before surgery. *Oral Surg Oral Med Oral Pathol Oral Radiol Endod.* 2003;95(1):119-25. doi: 10.1067/moe.2003.16.
23. Bokindo IK, Butt F. Variant Root Morphology of Third Mandibular Molar in Normal and Impacted Teeth. *Anat J Africa.* 2017;6(3):1052-61. doi:10.4314/aja.v6i3.163510.
24. Orafi MI. Quantitative classification of impacted teeth: A new proposal. *World J Dent.* 2018;9(6):523-6. doi:10.5005/jp-journals-10015-1591.
25. Fiorillo L, Ciccù M. The Use of Fi-Index Tool to Assess Per-manuscript Self-citations. *Publ Res Q.* 2022;38(4):684-92. doi:10.1007/s12109-022-09920-2.