

Perforation of the terminal ileum secondary to ingestion of duck bone

Fahrettin Yildiz¹, Alpaslan Terzi¹, Sacid Coban², Hasan Cece³, Ali Uzunkoy¹

¹ Harran University Medical Faculty,
Department of General Surgery, Sanliurfa, Turkey

² Gaziantep University Medical Faculty,
Department of General Surgery, Gaziantep, Turkey

³ Harran University Medical Faculty,
Department of Radiology, Sanliurfa, Turkey

Corresponding author:

Fahrettin YILDIZ,
Harran University Medical Faculty,
Department of General Surgery,
63300, Sanliurfa, Turkey
fahrettinyildiz@hotmail.com

Received: 18 December 2008

Accepted: 27 April 2009

Foreign body (FB) ingestion is a common clinical problem. The majority of swallowed objects are often passed spontaneously without complications. However, a small proportion of FB that passes from the stomach result in complications distally which require surgery. We describe an ileal perforation following the ingestion of a duck bone which was diagnosed by CT preoperatively and confirmed by laparoscopy. The case reported is of interest for several reasons, such as the lack of any condition that can predispose patients to accidental ingestion of FB, no specific history of FB ingestion and the small possibility of detecting foreign bodies on computed tomography.

Key Words: Foreign body, Duck bone, Ileal perforation.

Introduction

Perforation peritonitis is the most common surgical emergency noticed in the younger age group. There are numerous causes of gastrointestinal tract perforations, and most of these perforations are emergency conditions of the abdomen that require early surgical treatment (1). **Ingestion of foreign bodies** is not an uncommon occurrence although fortunately most pass through the gastrointestinal tract without a problem. **Foreign bodies** such as fish bones (2), chicken bones (3), dentures (4), toothpicks and cocktail sticks (5) have been known to cause gastrointestinal tract perforation especially in certain

classes of people. A very small percentage perforates the gastrointestinal tract, leading to acute abdomen and requiring surgical intervention (6). Preoperative diagnosis is usually difficult.

We report a case of perforation of the ileum by a piece of ingested duck bone diagnosed by CT and confirmed by laparoscopy.

Case Report

A 70-year-old previously well man presented to our hospital with a 20-day history of abdominal pain and with a 5-day history of severe abdominal pain with bilious vomit-

ing and fever. On examination, he was febrile, tachypnoeic, and had tachycardia. His pulse rate was 110/minute, blood pressure was 110/60 mmHg. He was irritable with a high fever of 39°C and on physical examination rebound tenderness was present in the right iliac fossa. His white blood cell count was raised at $17 \times 10^9/l$. Other laboratory blood and urine tests were normal. Chest radiograph showed free intraperitoneal air under the diaphragm. The original preoperative CT scans were reviewed by a senior radiologist, and it was thought that a small region of localized inflammation containing the possibility of a sharp foreign body, as shown in Figure 1 and an enlarged segment of small bowel and free intraperitoneal fluid were present. He was presumed to have intra-abdominal abscess due to foreign body perforation or appendicitis. On laparoscopy of the case, we found a perforation located at the terminal ileum by a foreign body, 20 cm proximally to the ileo-caecal junction. Extraction of the foreign body could not be achieved laparoscopically. There was also purulent peritoneal fluid on laparoscopic evaluation. Thus, we performed laparotomy (Figure 2). Due to the severe inflammatory changes of the terminal ileum and severe peritonitis, segmental resection of the terminal ileum with ileostomy was performed. The patient had an uneventful postoperative course and was discharged seven days after the procedure.

Discussion

Gastrointestinal perforation is a hole that develops through the entire wall of the gastrointestinal tract and can be caused by a variety of illnesses, such as ulcer disease, appendicitis, less commonly, inflammatory bowel diseases (1). Perforation of the ileum by ingested foreign bodies is uncommon. These foreign bodies may lodge anywhere

in the gastrointestinal tract, and less than 1% of ingested foreign bodies perforate the small intestines (2). Abdominal CT scan is considered the most useful imaging to detect foreign bodies or complications arising from them (6).

The mainstay of treatment for gastrointestinal perforation is surgical management. However, if there are no symptoms or signs of generalized peritonitis, nonsurgical management of perforation is a feasible option (7). Treatment usually involves surgery to repair the perforated area. Occasionally, a small part of the intestine must be removed. A temporary colostomy or ileostomy may be needed. The first goal of surgical therapy is to correct the cause of peritonitis. Then the other goals are to correct the underlying anatomical problem and to remove any foreign material in the abdominal cavity. Further, experience and the advancement in accessories have enabled laparoscopic repair of intestinal perforations (8). Marked peritonitis and poor nutritional status were the main factors in this old patient, so preference was given to temporary loop ileostomy.

This case is particularly interesting because peritonitis secondary to perforation due to a foreign body was discovered preoperatively using a CT scan and the definite diagnosis was established by laparoscopy but extraction of the foreign body could not be achieved due to its shape.

Intestinal perforation after foreign-body ingestion must always be considered for the differential diagnosis of acute abdomen even if there is a lack of information about ingestion of a foreign body such as chicken bones preoperatively. Although preoperative diagnosis may be made using an abdominal CT scan, for doubtful conditions, laparoscopy may be more useful, wherefore it allows further examination of the entire abdomen. And as a suggestion, **diners should be more careful.**

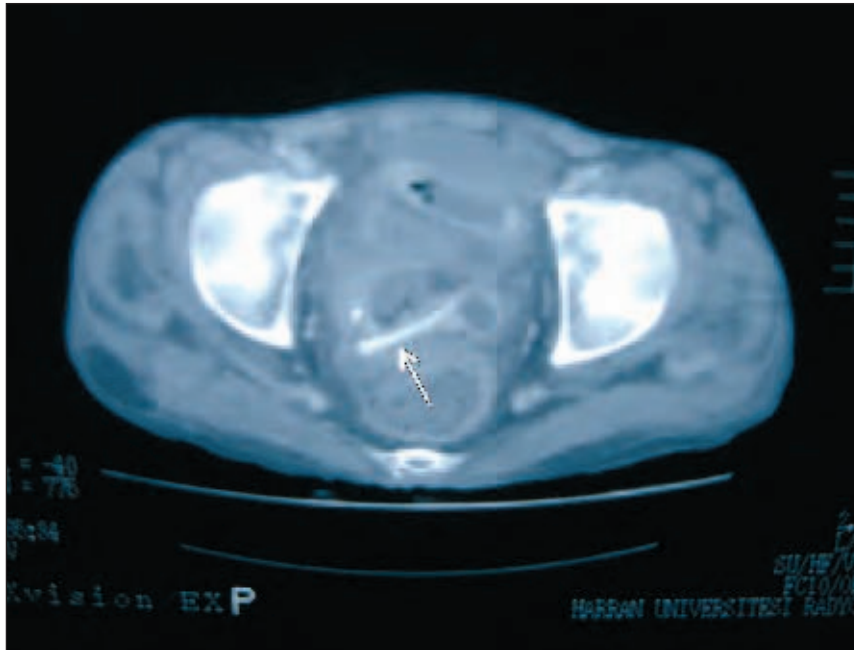


Figure 1 Abdominal CT images of the patient, the arrow is pointing to the foreign body

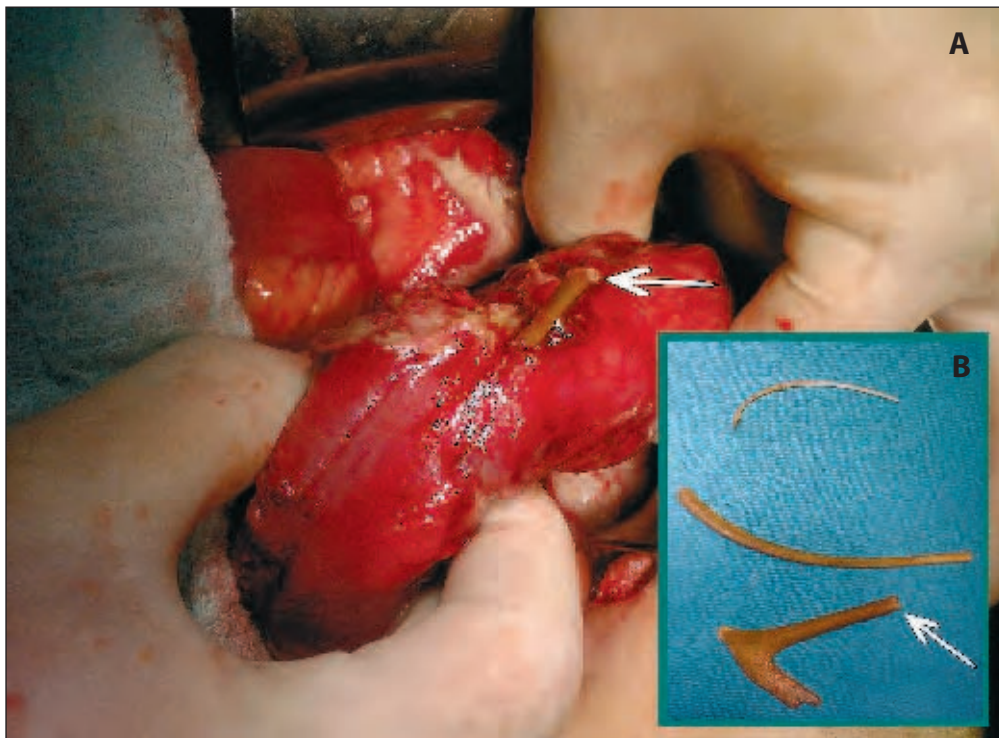


Figure 2 *A* Photograph of the specimen intraoperatively shows a fragment of ingested bone penetrating the ileum. *B* Photograph of the retrieved ingested bones. Both arrows show the same bone and same side

References

1. Afridi SP, Malik F, Ur-Rahman S, Shamim S, Samo KA. Spectrum of perforation peritonitis in Pakistan: 300 cases Eastern experience. *World J Emerg Surg.* 2008;3:31.
2. Hsu SD, Chan DC, Liu YC. Small-bowel perforation caused by fish bone. *World J Gastroenterol.* 2005;11(12):1884-5.
3. Vasapollo L, Chiarot M, Gallinaro L, Papaspyropoulos V, Montesano G, Ciulli A, et al. Intestinal perforation caused by a chicken bone: apropos of a clinical case. *Ann Ital Chir.* 1997;68(4):555-8.
4. Goh BK, Chow PK, Quah HM, Ong HS, Eu KW, Ooi LL, et al. Perforation of the gastrointestinal tract secondary to ingestion of foreign bodies. *World J Surg.* 2006;30(3):372-7.
5. Wichmann MW, Hüttl TP, Billing A, Jauch KW. Laparoscopic management of a small bowel perforation caused by a toothpick. *Surg Endosc.* 2004;18(4):717-8.
6. Furukawa A, Sakoda M, Yamasaki M, Kono N, Tanaka T, Nitta N, et al. Gastrointestinal tract perforation: CT diagnosis of presence, site, and cause. *Abdom Imaging.* 2005;30(5):524-34.
7. Trecca A, Gaj F, Gagliardi G. Our experience with endoscopic repair of large colonoscopic perforations and review of the literature. *Tech Coloproctol.* 2008;12(4):315-21.
8. Hansen AJ, Tessier DJ, Anderson ML, Schlinkert RT. Laparoscopic repair of colonoscopic perforations: indications and guidelines. *J Gastrointest Surg.* 2007;11(5):655-9.