

Anatomical Variation of a Communicating Branch between the Musculocutaneous and the Median Nerve: A Case Report

Dimosthenis Chrysikos, Andreas Athanasopoulos, Panagiotis Georgakopoulos, Ioannis Antonopoulos, Alexandros Samolis, Theodore Troupis

Department of Anatomy, Medical School, National and Kapodistrian University of Athens, Athens, Greece

Correspondence: *ttroupis@med.uoa.gr*; Tel.: + 30 210 746 2388; Fax.: + 30 210 746 2398

Received: 2 October 2019; **Accepted:** 31 March 2020

Abstract

Objective. The aim of our paper is to depict an anatomical variation of the brachial plexus, concerning a communicating branch between the median and the musculocutaneous nerve and its clinical significance. Anatomical variations of the brachial plexus and especially those of the musculocutaneous nerve are quite common. Awareness of these variations is of paramount importance in clinical practice, mainly in achieving best results in minimal invasive or surgical procedures. **Case Report.** After dissection in upper extremities in a 89-year-old male cadaver, a communicating branch between the median and the musculocutaneous nerve was found. This communicating branch was formed before the musculocutaneous nerve perforated the coracobrachialis muscle. It also derived from the level of the ansa medianis and its course was of an approximately 2cm length. **Conclusion.** The clinical significance of our study is the entrapment of the musculocutaneous nerve that may cause clinical findings similar to those of the carpal tunnel syndrome.

Key Words: Median Nerve ▪ Musculocutaneous Nerve ▪ Brachial Plexus Anatomy ▪ Communicating Branch.

Introduction

Brachial plexus is formed by the contribution of all the anterior divisions of the C5 to C8 nerves, along with a sizeable part of the first thoracic nerve (T1) and a small communicating branch of the 4th cervical nerve (C4). These nerves are of similar size and the pattern of communication between them is subject to a non-negligible variation, so that there is no precise pattern that can be followed in all cases.

The Median Nerve (MN) is formed by a lateral and a medial root, the union of which forms the ansa medianis astride the lower third of the axillary artery. After its formation, the MN follows a course downwards along the midline of the arm and antebrachium, giving muscular branches. These branches are the anterior interosseous, the palmar cutaneous branch in the forearm and the three first common digital nerves as well as a motor branch that supplies the muscles of the thumb, in the palm.

The Musculocutaneous Nerve (MCN), or perforans Gasserii nerve, innervates the anterior brachial muscles as well as the outer part of cutem antebrachii. It derives from the lateral cord of the plexus brachialis and after perforating the Coracobrachialis muscle (CBM), it follows an oblique trajectory between the biceps and brachialis anticus muscles down to the elbow, where it finally turns to a cutaneous sensory nerve after perforating the deep fascia. As a cutaneous nerve, it divides into a posterior and an anterior nerval branch, after passing behind the cephalic vein (1).

The anatomical variations of the brachial plexus and especially the existence of anastomotic branches between its nerves, for instance between the MN and MCN or even the ulnar and radial nerve are not rare (2). More specifically the variations of the MCN are quite common as it may pass beneath or even through the biceps rather than

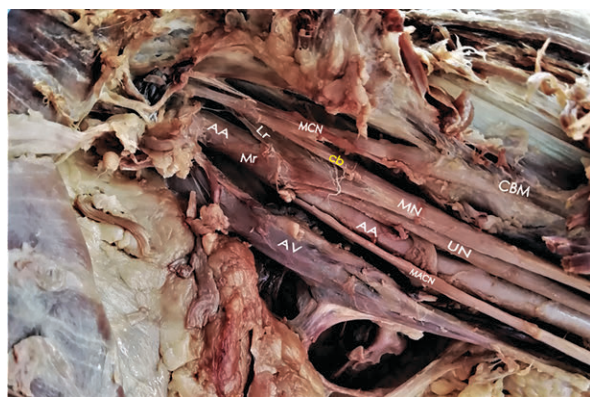
perforating the coracobrachialis, as well as it may send a communicating branch to the MN. Actually, as in our case study, some fibers of the MN are incorporated to the MCN and after covering some distance in it, they secede to unite with their originative nerve (1).

In this paper, we present a case of an interesting and clinically significant anatomical variation of the brachial plexus, concerning a communicating branch between the median and the musculocutaneous nerve.

Case Report

The anatomical variation of our study was depicted in a 89 years old male cadaver of Greek origin, that was formalin-fixed. The cadaveric dissection took place in the Hall of Dissections of the Department of Anatomy, School of Medicine, National and Kapodistrian University of Athens, Greece. The axillary region of the cadaver was dissected and cleaned by the contributors. Finally, the anatomical specimen was properly photographed.

While proceeding a routine dissection of the left axillary region of a Greek male cadaver, we encountered a variation in the ipsilateral plexus brachialis. Between the median and the musculocu-



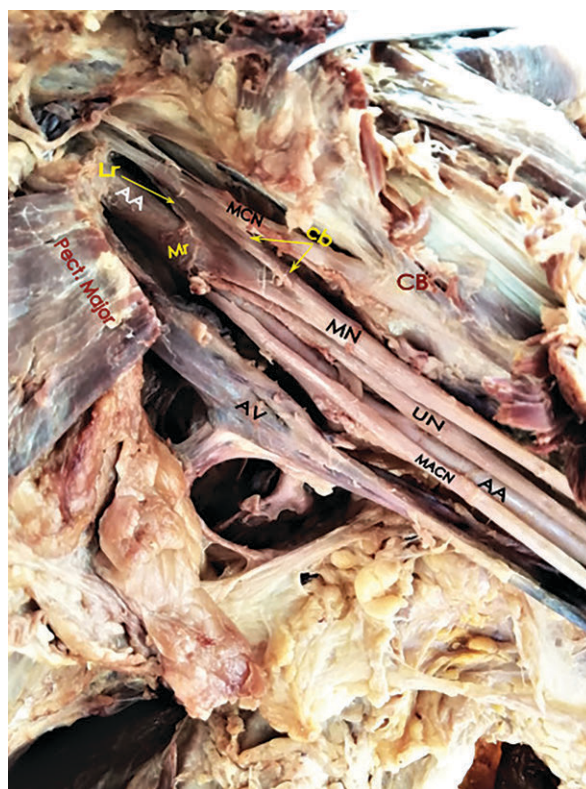AA=Axillary Artery; AV=Axillary Vein; MN=Median Nerve; MCN=Musculocutaneous Nerve; UN=Ulnar Nerve; MACN=Medial Antebrachial Cutaneous Nerve; Mr=Medial root; Lr=Lateral Root; cb=Communicating Branch; CBM=Coracobrachialis Muscle.

Figure 1. The anatomical specimen of the cadaver's left axilla, depicting a communicating branch between MCN and MN. The major and minor pectoralis have been removed.

taneous nerve there existed an anastomotic neural branch that was derived before the musculocutaneous nerve perforated the CBM (Figure 1). This communicating branch stemmed from the level of the ansa medianis formation and its course was approximately 2 cm in length. The MN was formed by a normal median and lateral root, coalescing in the ansa medianis supra, in the outer third of the axillary artery, the course and supply of which were dissected and found normal (Figure 2). The anatomical variation was observed unilaterally.

Discussion

There have been several case reports and studies about anastomotic branches between the median



AA=Axillary Artery; AV=Axillary Vein; MN=Median Nerve; MCN=Musculocutaneous Nerve; UN=Ulnar Nerve; MACN=Medial Antebrachial Cutaneous Nerve; Mr=Medial Root; Lr=Lateral Root (arrow); cb=Communicating Branch (double arrow); CB=Coracobrachialis Muscle.

Figure 2. The axillary cavity of a Greek male cadaver. A communicating branch between MCN and MN derived from the level of the ansa medianis. Its course is approximately 2 cm in length.

and the musculocutaneous nerve. There are also a number of attempts to classify this structural irregularity of the brachial plexus. According to Venieratos et al. (3), our case belongs to the Type I category, in which the communicating branch is given before the MCN pierces the CBM. Type II refers to those branches given after the CBM's perforation by the MCN and in Type III, which seems to be the rarest of the three, the MCN gives the anastomosing branch without entering the CBM. Additionally, in our case the MCN not only perforates but also innervates the CBM. However, there have been reported cases in which the MN is fused with the MCN and the CBM gets innervated from a small neural branch arising from the MN's lateral root (4).

It is not clear when to consider an anastomosis between the MN and the MCN as a communicating branch or a second lateral root of the MN. Buch-Hansen in 1955, has reported (5) that the segregation should be done comparing the thickness of the branch with that of the MN lateral root. In that terms, if the communicating branch is thicker of the lateral root or of equal thickness, then it is considered as a second MN lateral root, if it is not, then it constitutes a neural anastomosis. So, according to this study, our case is indeed a communicating branch.

Referring to the structural characteristics of the communicating branch that we found, it was of a length similar to those found in Elgseder's and Goldman's study (6), in which 108 upper limbs of American origin cadavers were dissected. According to this study, the most common length of the communicating branch was about 1.8 cm. In addition to these findings, Ballesteros et al. (2015) (7) found such branches with 5.78 cm length, significantly longer than our case's branch, as well as the case reported by Gelmi et al. (2018) (8) in which the communicating branch extended from the axilla down to the level of the elbow where it finally rejoined the MN beneath the cephalic vein. Finally, in our case the communicating branch that we encountered, gave off no other branch (motor or sensor), in contrast to other cases in the literature, as the one described by Patil et al. (9).

As already referred, the existence of a communicating branch arising from the MCN downwards to the MN is not a rare variation. On the contrary, a neural branch originating from the MN to the MCN, is not as common. In Ballesteros' study, MCN to MN branch was present in 17% of the upper limbs dissected, while the opposite was observed only in the 2.8% of the specimens. Also, according to Venieratos et al. 158 upper extremities were dissected and no MN to MCN branch was detected. Finally, Mat Taib et al. (2017) (10) found a MN to MCN branch in 13.6% of a total of 44 upper extremities, while Maeda et al. (2009) (11) dissected 453 axillae and found MCN to MN branch in 18.8% of them and MN to MCN branch in 12.8%.

In terms of the clinical significance that such an anatomical variation may have, according to El-Falougy et al. (2013) (12) and Wertsch et al. (1982) (13), entrapment of the MCN (usually while sleeping) may cause clinical findings similar to those of the carpal tunnel syndrome or MN lesion, in case of a communicating branch co-existence. Entrapment of the MCN may occur as a result of CBM spasm or more rarely by MCN's compression by the aponeurosis of biceps brachialis muscle, with its tendon against the brachialis muscle's fascia (14). In such a case, if an electromyography is not done, it may lead to an unnecessary operation in order to release the carpal tunnel. Also, this structural change of the axillary region's anatomy may lead to significant complications during an anterior or anteriolateral approach of the shoulder (deltopectoral incision) in terms of humeral fractures management and during an axillary block by anesthesiologists as well.

Conclusion

The case described above is among the most common anatomical variations of the brachial plexus. However, being aware of such structural abnormalities, it is of a non-negligible practical significance, especially for surgeons operating in the axillary region and managing humerus fractures or anesthesiologists who perform axillary nerve blocks for operations in the upper limb.

What Is Already Known on this Topic:

Anatomical variations of the brachial plexus are very common. Those concerning the median and the musculocutaneous nerve have the most significant clinical impact. Many attempts to classify structural irregularities of the brachial plexus, have contributed to perform safe operations in the axillary cavity, by avoiding disastrous neural complications.

What this Case Adds:

As a complementary in the existing literature, the anatomical variation of a communicating branch between the median and the musculocutaneous nerve, contributes a rare case. The clinical analogue of this finding might be the entrapment of the musculocutaneous nerve that may cause clinical findings similar to those of the carpal tunnel syndrome. It is of paramount importance the awareness of such structural abnormalities in order to further evaluate the anatomy of the axillary cavity, before performing minimally invasive or surgical procedures.

Authors' Contributions: Conception and design: DC, IA and TT; Acquisition, analysis and interpretation of data: PG and AS; Drafting the article: DC and IA; Revising it critically for important intellectual content: TT; Approved final version of the manuscript: DC, PG, IA, AS and TT.

Conflict of Interest: The authors declare that they have no conflicts of interest.

References

1. Gray H, Howden R, Pick T. Gray's Anatomy. 15th ed. New York: Barnes & Noble; 2010. p.745-53.
2. Ferreira Arquez H. Anastomosis Between Ulnar And Radial Nerve: A Cadaveric Study. *International Archives of Medicine*. 2017;10.
3. Venieratos D, Anagnostopoulou S. Classification of communications between the musculocutaneous and median nerves. *Clinical Anatomy*. 1998;11(5):327-31.
4. Clarke E, Wysiadecki G, Haładaj R, Skrzat J. Fusion between the median and musculocutaneous nerve: A case study. *Folia Med Cracov*. 2019;59(3):45-52.
5. Buch-Hansen K. Variations of the median nerve and the musculocutaneous nerve and their connections [in German]. *Anat Anz*. 1955;102(9-14):187-203.
6. Eglseider W, Goldman M. Anatomic variations of the musculocutaneous nerve in the arm. *Am J Orthop*. 1997;26(11):777-80.
7. Ballesteros LE, Forero PL, Buitrago ER. Communication between the musculocutaneous and median nerves in the arm: an anatomical study and clinical implications. *Rev Bras Ortop*. 2014 Dec 27;50(5):567-72.
8. Gelmi C, Pedrini F, Fermi M, Mariani G, Cocco L, Billi A. Communication between median and musculocutaneous nerve at the level of cubital fossa - A case report. *Translational Res Anat*. 2018;11:1-4.
9. Patil S, Meshram M, Kasote A, Kamdi N. Formation of median nerve from single root on left side and communicating branch from median nerve to musculocutaneous nerve on right side. *Morphologie*. 2012;96(313):51-4.
10. Mat Taib C, Hassan S, Esa N, Mohd Moklas M, San A. Anatomical variations of median nerve formation, distribution and possible communication with other nerves in preserved human cadavers. *Folia Morphol*. 2017;76(1):38-43.
11. Maeda S, Kawai K, Koizumi M, Ide J, Tokiyoshi A, Mizuta H, et al. Morphological study of the communication between the musculocutaneous and median nerves. *Anat Sci Int*. 2009;84(1-2):34-40.
12. El-Falougy H, Selmečiova P, Kubikova E, Stenova J, Haviarova Z. The variable communicating branches between musculocutaneous and median nerves: a morphological study with clinical implications. *Bratisl Lek Listy*. 2013;114(5):290-4.
13. Wertsch J, Melvin J. Median nerve anatomy and entrapment syndromes: a review. *Arch Phys Med Rehabil*. 1982;63(12):623-7.
14. Turner O, Taslitz N, Ward S. *Handbook of Peripheral Nerve Entrapments*. Totowa, NJ: Humana Press; 1990. p. 23-4.