

Severe Leptospirosis in a Mexican Woman

Ana Paola Balderrama-Carmona¹, Daniel Cadena-Orea², Santiago Sánchez-Arteaga², María Luisa Aguilera-Ávila², José Guadalupe Soñanez-Organis¹, Alan Andréi López-López³, Luis Alberto Zamora-Alvarez¹, Gabriela de los Ángeles Díaz-Reyes¹, Norma Patricia Adan-Bante¹

¹Departamento de Ciencias Químico Biológicas y Agropecuarias, Universidad de Sonora, Unidad Regional Sur. Navojoa, Sonora, México, ²Instituto Mexicano del Seguro Social (IMSS). Hospital de Especialidades No. 2 “Lic. Luis Donaldo Colosio”. Cd. Obregón, Sonora, México, ³Laboratorio Sonora Labs. Hermosillo, Sonora, México.

Correspondence: patricia.adan@unison.mx; Tel.: + 52 1642 425 9969

Received: 17 May 2019; **Accepted:** 18 February 2020

Abstract

Objective. To describe a severe case of infection by *Leptospira* in a woman in the northwest of Mexico. **Case report.** A 55-year-old woman from Sonora, México arrived at the Intensive Care Unit due to severe multiple organ failure primarily affecting the respiratory, renal and hepatic systems. Diagnostic tests were performed, and they were positive for anti-*Leptospira* antibodies, IgM and IgG; and spirochetes were observed on dark field microscopy and confirmed by Polymerase Chain Reaction (PCR). Doxycycline and platelet apheresis transfusion were used as treatment, which led to a very slow recovery. **Conclusion.** The information presented in this study may help in the identification of pathology caused by spirochetes. This case report is the first to present a case of severe leptospirosis in Sonora, México.

Key Words: Vector-Borne Disease ■ Acute Febrile Illness ■ Leptospirosis ■ Renal Failure ■ Borrelia.

Introduction

Spirochetes are Gram-negative aerobic bacteria with a double membrane and a helicoidal structure; these features allow the bacteria to survive in fresh water or wet soil (1, 2). In public health, one of the most pathogenic spirochetes with worldwide importance in humans is *Leptospira*. The infection may be transmitted by a chronic carrier, through contact with contaminated water, soil, and urine (3). These bacteria are endemic to unsanitary areas (4). A poor diagnosis may lead to inappropriate treatment and allow for the development of complications, and even death, due to the clinical mimicry of these infections of other acute febrile illnesses (AFI) (3). In Mexico, leptospirosis disease is not a very well-known pathology, with most cases being reported predominantly in animals (5).

The aim of this publication is to describe a case of severe leptospirosis infection in a Mexican woman.

Case Presentation

On June 19, 2018, a 55-year old Mexican woman was evaluated at the emergency department of a public hospital, due to a 3-month history of arthralgia, asthenia, fever, diarrhea, and dyspnea. During the epidemiological survey, the patient referred to having 3 dogs as pets, and travelling to the city of Mazatlán, Sonora, a port city with access to the beach, where the patient participated in outdoor activities that put her in contact with free water during her stay, mainly swimming. Without clinical improvement and with compromised respiratory function and tachycardia, she was transferred to a private hospital. Clinical tests were later conducted which showed thrombocytopenia and leukocytosis, after which the patient was admitted to the Intensive Care Unit due to the development of multiple organ failure: predominantly affecting the respiratory, renal and hepatic systems. After be-

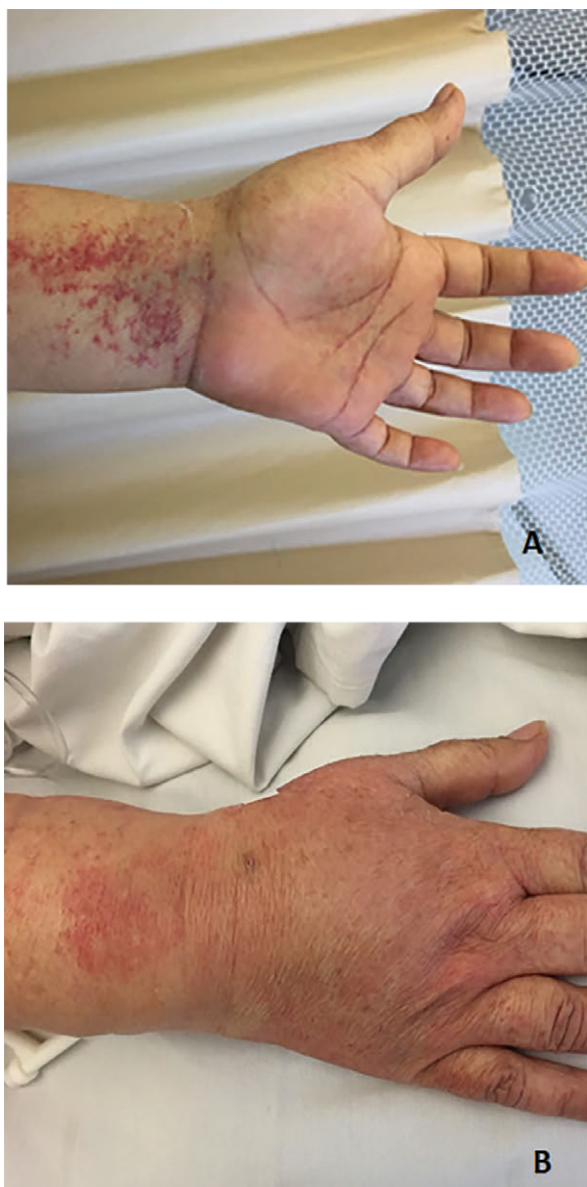

Figure 1. Diffuse ecchymosis in arms (A); Petechia (B).

ing admitted to the Intensive Care Unit, the same symptomatology was reported to persist for 3 more days. She was found to have no febrile antibodies and no antigen reaction to dengue when tested, but was reported positive for anti-*Leptospira* antibodies, IgM 3.510 Optical Density (OD) and IgG 1.574 OD (Range: Negative 0.0 to 0.3 and Positive >1.0; these antibodies were detected using commercial kits (Diagnostic automation, INC. Cat # 8204-3 and Cat # 8208-3 respectively). She was treated

with Doxycycline and underwent platelet apheresis transfusion.

The woman was then transferred to a public hospital where treatment was continued. A day later, she was admitted to the Internal Medicine ward in a very grave condition, with severe thrombocytopenia, generalized petechiae, a hyperemic rash that was hot to the touch, moderate hyperchloremia, mild elevation of LDH, grade III normochromic normocytic anemia, severe thrombocytopenia, and hepatomegaly (Figure 1). A skin-biopsy was conducted, and the results showed thrombocytopenic purpura. In addition, dark-field microscopy of a blood sample showed the presence of spirochetes characteristic of *Leptospira* and *Borrelia*; dark-field microscopy may be considered as a preliminary diagnostic tool associated with finding the morphological characteristics of spirochetes on samples, suggesting the presence of *Borrelia* and/or *Leptospira*. Enzyme immunoassay (EIA) IgM and IgG (Diagnostic Automation, INC.) was performed for *Borrelia burgdorferi* in order to exclude a coinfection by this bacteria, and leptospirosis was confirmed using conventional PCR, and Go Taq Flexible DNA polymerase wasevaluated (6); the tests performed were negative for borreliosis. After more than a month of being hospitalized, the patient was discharged with significant clinical and biochemical improvement.

Discussion

Previous reports of leptospirosis conducted in Sonora, Mexico (2000-2010) have reported that the most affected demographic group is that of males between 25 and 44 years of age, predominantly those that originate from the southernmost regions of the country (5), the opposite of our current case. Due to the specific set of symptoms presented by this patient, it is highly probable that she was suffering from a severe case of Leptospirosis, since in other case reports where this diagnosis was made (7-9), similar symptomatology to that of our patient was reported. *Borrelia* spirochetes are not a common finding when performing dark-field microscopy, and their presence should not always

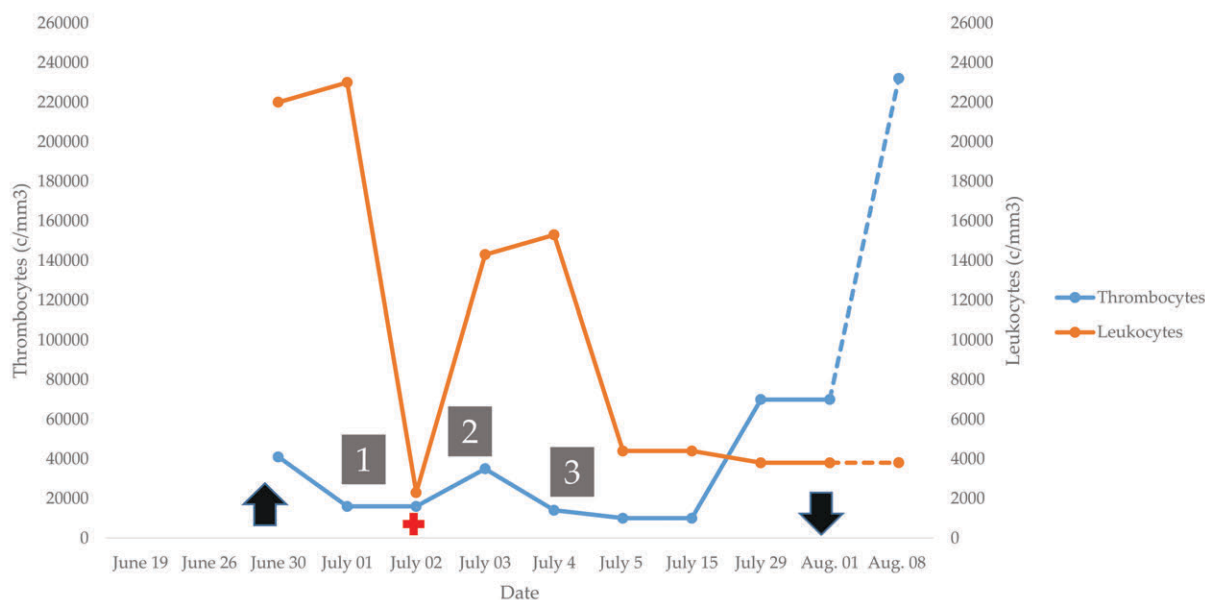


Figure 2. Clinical test and timeline of medical history. ↑=Indicates the onset of the symptomatology, 1=First visit to a public hospital; 2=Intensive care in a private hospital; +=*Leptospira* detection; 3=Transferred to a public Hospital to the internal medicine ward; ↓=Hospital Discharge.

be taken as an indication of a co-infection, because *Borrelia* serology may remain positive for months after the primary infection. It is however important to take into consideration that *Borrelia* and *Leptospira* may occur at different points in time and their sequelae may contribute to the clinical course of one another; during this study, the serological titers obtained for *Borrelia* were IgG 0.60 and IgM 0.30 OD (OD Range: Negative <0.90 and Positive >1.10), discarding coinfection. Upon questioning, the patient reported that she was in contact with pets, but not with rodents. In other leptospirosis case reports, the patients referred to going swimming in free non-sanitized water prior to developing symptoms (2), a risk factor also present in our patient, who said that she had traveled to the beach before becoming ill.

In our patient, the most difficult clinical problems to deal with were renal failure and thrombocytopenia. Figure 2 shows the increase in leukocytes next to the decrease in platelets, as reported in the medical history timeline, which strengthens our position that treatment based on doxycycline (1, 2, 7) and apheresis (10) was needed urgently. This proved to be a decisive factor in our

patient's improvement; plasma apheresis is helpful in eliminating the excess of microorganisms and inflammatory cells, and is a common treatment indicated for cases of multi-organ failure (11, 12). We consider that the severity of the case could have been reduced with preemptive antimicrobial therapy, even before the diagnosis of leptospirosis (13). In this case, even though the proper treatment was used, our patient had to be hospitalized for more than a month, unlike most cases of common leptospirosis where the patients are discharged after no more than two weeks, due to a case of severe leptospirosis (14).

Conclusions

This report demonstrates the presence of *Leptospira*, and the unusual and severe clinical manifestations it causes in relation to the systemic nature of spirochetes. We report the case of a patient who presented with clinical deterioration that rapidly evolved into multi-organ failure involving the respiratory, renal and hepatic systems, together with severe thrombocytopenia and, which suggests immunocompromise. This study again confirms the

utility of plasmapheresis in severe leptospirosis. This report is the first to present a case of severe leptospirosis in the south of Sonora, México.

What is Already Known on this Topic:

Leptospirosis is an under-diagnosed disease in Mexico. In this country, clinical cases in human patients have been historically scarce, and it has been more thoroughly studied in domestic animals. Its clinical diagnosis is difficult due to its polymorphism and because the clinical findings may be attributed to other more common diseases, such as dengue fever, paludism, brucellosis, flu-like syndromes, and others; therefore, complementary laboratory testing is key for its diagnosis and treatment.

What this Case Adds:

Confirmatory testing for leptospirosis, such as dark field microscopy and positive IgG and IgM, are a valuable tool for obtaining an early diagnosis, which, when coupled with the symptoms and suggestive clinical signs, allow for a speedier decision-making process regarding treatment, and rejecting other causative agents. The diagnosis is confirmed by a PCR test. In conclusion, with these measures, it is possible to help the patient, avoid multi-organ deterioration, and shorten hospital time.

Acknowledgments: We are grateful to the Internal Medicine services from the High Specialty Medical Unit, Special Hospital No. 2 "Lic. Luis Donaldo Colosio" of the National Medical Center of the Northwest of Mexico. Special thanks to Dra. Brenda Alicia Gonzalez-Adan for linguistic assistance.

Conflict of Interest: The authors declare that they have no conflict of interest.

Authors' Contributions: Conception and design: NPAB and DCO; Acquisition, analysis and interpretation of data: NPAB and APBC; Drafting the article APBC; Revising it critically for important intellectual content: DCO, SSA, JGSO, AALL, LAZA and GADR; Approved final version of the manuscript: NPAB, JGSO, DCO and SSA.

Source of Support: This study received funding from Universidad de Sonora, México (grand: USO13006243).

References

- Kang YM, Hagiwara A, Uemura T. Leptospirosis infection in a homeless patient in December in Tokyo: a case report. *J Med Case Rep.* 2015;9:198.
- Leen I, Bruynseels P, Mukadi BK, van Oort M, van den Akker M. A 13-year old girl with pancytopenia at the presentation of a *Borrelia hispanica* infection: a case report and review of the literature. *J Med Case Rep.* 2017;11(1):51.
- Jarayaman PA. Innate Immune Responses to Infection by the Pathogenic Spirochetes *Leptospira interrogans* and *Borrelia burgdorferi*. [dissertation]. Raleigh: North Carolina State University; 2015.
- Cutuli SL, De Pascale G, Spanu T, Dell'Anna AM, Bocci MG, Pallavicini F, et al. Lice, rodents, and many hopes: a rare disease in a young refugee. *Crit Care.* 2017;21(1):81.
- Zúñiga CIR, Caro LJ. Epidemiological overview of leptospirosis, United Mexican States 2000-2010. *Enf Inf Microbiol.* 2013;33(2):71-6.
- Kramer MF, Coen DM. Enzymatic amplification of DNA by PCR: standard procedures and optimization. *Curr Protoc Immunol.* 2001;Chapter 10:Unit 10.20.
- Neaterour P, Rivera A, Galloway RL, Negrón MG, Rivera-García B, Sharp TM. Fatal *Leptospira* spp./Zika Virus Coinfection—Puerto Rico, 2016. *Am J Trop Med Hyg.* 2017;97(4):1085-7.
- Maroun E, Kushawaha A, El-Charabaty E, Mobarakai N, El-Sayegh S. Fulminant Leptospirosis (Weil's disease) in an urban setting as an overlooked cause of multiorgan failure: a case report. *J Med Case Rep.* 2011;5:7.
- Sotelo CN, Valencia MP. Borreliosis: recurrent fever due to spirochetes. Case report. *Bol Med Hosp Infant Mex.* 2012;69(2):121-5.
- Małecki M, Gołembiewska E, Muraszko AM, Fiecek B, Lewandowska M, Urańska E, et al. Atypical Renal Presentation in Severe Leptospirosis. *Kidney Int Rep.* 2018;4(1):168-70.
- Bourquin V, Ponte B, Hirschel B, Pugin J, Martin PY, Saudan P. Severe leptospirosis with multiple organ failure successfully treated by plasma exchange and high-volume hemofiltration. *Case Rep Nephrol.* 2011;2011:817414.
- Ekinci F, Yıldızdaş RD, Horoz ÖÖ, Alabaz D, Tolunay İ, Petmezci E. Treatment of severe leptospirosis with therapeutic plasma exchange in a pediatric patient. *Turk J Pediatr.* 2018;60(5):566-70.
- Tubiana S, Mikulski M, Becam J, Lacassin F, Lefèvre P, Gourinat AC, et al. Risk factors and predictors of severe leptospirosis in New Caledonia. *PLoS Negl Trop Dis.* 2013;7(1):e1991.
- Duarte-Neto AN, Croda J, Pagliari C, Soriano FG, Nicodemo AC, Duarte MIS. Severe Leptospirosis Features in the Spleen Indicate Cellular Immunosuppression Similar to That Found in Septic Shock. *Front Immunol.* 2019;10:920.