

## Variable skeletal anatomical features of acromegaly in the skull and craniocervical junction

Maria Piagkou<sup>1</sup>, Othon Manolakos<sup>1</sup>, Theodore Troupis<sup>1</sup>, Nikolaos Lazaridis<sup>2</sup>,  
Konstantinos Laios<sup>1</sup>, Alexandros Samolis<sup>1</sup>, Konstantinos Natsis<sup>2</sup>

<sup>1</sup>Department of Anatomy, Medical School  
Faculty of Health Sciences, National and  
Kapodistrian University of Athens

<sup>2</sup>Department of Anatomy and Surgical  
Anatomy, Medical School, Faculty  
of Health Sciences, Aristotle University  
of Thessaloniki, Thessaloniki, Greece

Correspondence:

*mapian@med.uoa.gr*

Tel.: + 302 10 746 2427

Fax.: + 302 10 746 2398

Received: 16 August 2017

Accepted: 30 October 2017

**Key words:** Acromegaly ■ Skull base ■  
Craniocervical junction ■ Paranasal sinuses  
■ Wormian bones.

### Introduction

Acromegaly is a chronic endocrinopathy caused by growth hormone (GH) hypersecretion and stimulation of periosteal new bone formation, bone remodeling (1) and resorption (2). The subsequent articular chondrocyte replication and hyperfunction lead to cartilage thickening, joint widening and hypermobility (3). The periarticular structures begin to grow and synovial hypertrophy further exacerbates the abnormal mechanical loading of the joints. Disease progression ends with fibrocartilage calcification and osteophyte formation. In advanced cases, the articular cartilage

**Objective.** This study adds important information regarding the morphological alterations caused by growth hormone hypersecretion in the skull and craniocervical junction (CCJ). A variably asymmetric skull due to acromegaly coexists with expansion of the paranasal sinuses and multiple Wormian bones. **Case report.** A pathologically asymmetric dry skull of a European male, aged 38 years at death, with cranial vault and skull base thickening is described. The extensive paranasal sinus pneumatization caused a generalized thinning of the bony walls. The sphenoid sinus expanded intraorbitally, leading to sella enlargement. The orbital asymmetry coexisted with platybasia and hypoplasia of the occipital condyles and the odontoid process. Facial skeleton elongation and mandibular overgrowth were combined with prognathism, malocclusion and overbite. **Conclusion.** Skull and CCJ alterations are of paramount importance when selecting the surgical approach, if surgery is indicated. Consecutively, detailed preoperative evaluation and planning is essential. During surgery, skilled and experienced neurosurgeons recognize anatomical landmarks, use neuro-navigation and micro-instrumentation in order to remain on the midline avoiding any potential lethal vascular injury.

thickening and the joint space narrowing share many features with osteoarthritis (2). Pathognomonic signs in the neurocranium include cranial vault thickening, frontal skull bossing, prominent supraorbital ridges and large external occipital protuberance. In the viscerocranium, nasal bone hypertrophy, maxillary widening, mandibular overgrowth and prognathism with malocclusion and overbite may occur (4).

The current report emphasizes the morphological and morphometric features of acromegaly in the skull and CCJ. These alterations are of special neurosurgical interest and demand a detailed preoperative evaluation and planning. During surgery, the use

of anatomical landmarks, neuronavigation and micro-instrumentation is necessary.

### Case report

A pathologically asymmetric skull, with enlarged paranasal sinuses was found among 440 European adult human skulls from the osseous collections of the Department of Anatomy of the National and Kapodistrian University (Athens) and the Department of Anatomy and Surgical Anatomy of Aristotle University (Thessaloniki). The megalcephalic skull belonged to a European male aged 38 years at death, with a known history of acromegaly, according to his medical records. The male subject was a body donor, after giving written informed consent, before his death. The extensive paranasal sinuses pneumatization resulted in thinning of the bony walls, and thickening of the cranial vault and skull base. The anterior cranial fossa was shallower than usual due to the considerable expansion of the frontal sinus.

The most impressive intracranial finding was the excessive enlargement of the sella turcica (anteroposterior diameter 33.8 mm) and its porosity due to a pituitary adenoma, and the consequent extreme sphenoid sinus expansion. The deep and wide pituitary fossa was perforated by numerous minute apertures. The thickness and density of the outer and inner tables of the skull were decreased due to the over-pneumatization and expansion of the frontal sinus. Remarkable posterior cranial fossa side asymmetry was easily identified (Figure 1A). The massive periorbital expansion of the paranasal sinuses formed asymmetric orbital cavities and particularly pronounced supraorbital ridges bilaterally, associated with facial skeleton elongation. The maxillary sinuses extended to the palate and the alveolar process (Figure 1B). Fifty-two Wormian bones (WBs) had developed from extra ossification centers within the cranium, 34 of them extracranially, 12 intracranially and 6 intraorbitally (Table 1).

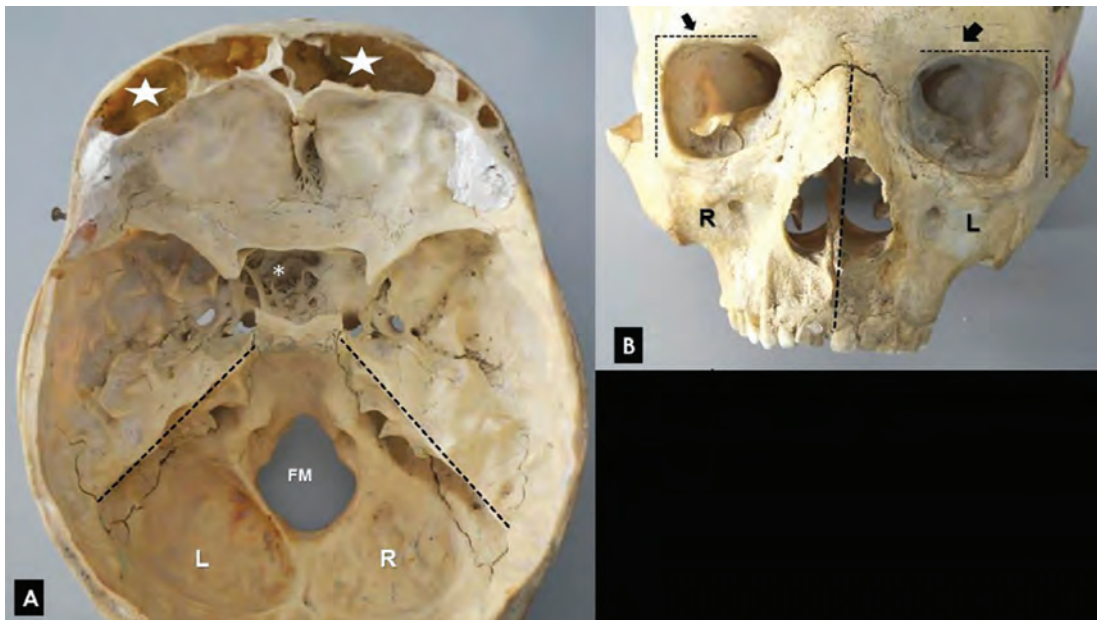


Figure 1A. Posterior cranial fossa side asymmetry indicated by the black dotted lines on the petrous bone crest. The asterisk (\*) indicates sella turcica enlargement and the double asterisks show extensive frontal sinus pneumatization, FM – foramen magnum, L-left side and R-right side. B. Black arrows indicate the particularly pronounced supraorbital ridges. Orbital cavity asymmetry is indicated by the dotted vertical lines.

Table 1 Topographical distribution and frequency of Wormian bones according to side

Wormian bones' positions	Side			Number
	Right	Left	Bilaterally	
<b>Extracranially</b>				
Lambdoid suture	-	-	11	11
Coronal suture	-	-	12	12
Metopic suture	-	-	1	1
Zygomaxillary suture	2	-	-	2
Sphenofrontal suture	2	-	-	2
Frontozygomatic suture	1	-	-	1
Parietomastoid suture	1	-	-	1
Occipitomastoid suture	1	1	-	2
Squamosal suture	-	1	-	1
Pterion	-	1	-	1
<b>Intraorbitally</b>				
Frontal bone	-	1	-	1
Sphenofrontal suture	5	-	-	5
<b>Intracranially</b>				
Asterion	-	1	-	1
Sphenoid bone	-	-	8	8
Frontal bone	-	2	-	2
Coronal suture	1	-	-	1
<b>Total</b>	<b>13</b>	<b>7</b>	<b>32</b>	<b>52</b>

Skull base flattening (platybasia) was detected, taking into consideration the increased basal angle ( $159^\circ$ ) formed between the clival plane and the sphenoid bone (normal range  $121-148^\circ$ ) (2). The wider basal angle in the current case confirms the basilar impression. The foramen magnum (FM), irregular in shape, was surrounded by abnormal protuberances of spongy bone around the right and left occipital condyles (OCs) and the posterior rim of the FM. The mastoid processes were large and bulky and the external occipital protuberance was extremely prominent (bathrocephaly skull) (Figure 2A). Marked side asymmetry was observed in the middle and posterior cranial fossae. The posterior fossa was filled with dental impression (Figure 2B) which was later bisected along the midline and an additional 0.5 cm thick slice was removed from

both sides. This way the depth was measured bilaterally taking into consideration the most anterior, middle and posterior points of the FM rim, known as the prosthion, FM middle and opisthion respectively (5). The relative values were 37.98, 37.01 and 38.91 mm on the left side and 32.87, 32.72 and 32.94 mm on the right side (Figures 2C, D).

The dominance off the left hemicranium was confirmed. The length and width of the right OC were 29.07 mm and 21.88 mm, while those of the left were 28.25 mm and 22.35 mm, respectively. The OCs were hypoplastic and completely flattened. New bone formation along the OC margin and the superior articular facets of the atlas was detected. Changes of the normal contour were accompanied by widening and flattening of the articular facets. An increased concavity existed on the right inferior ar-

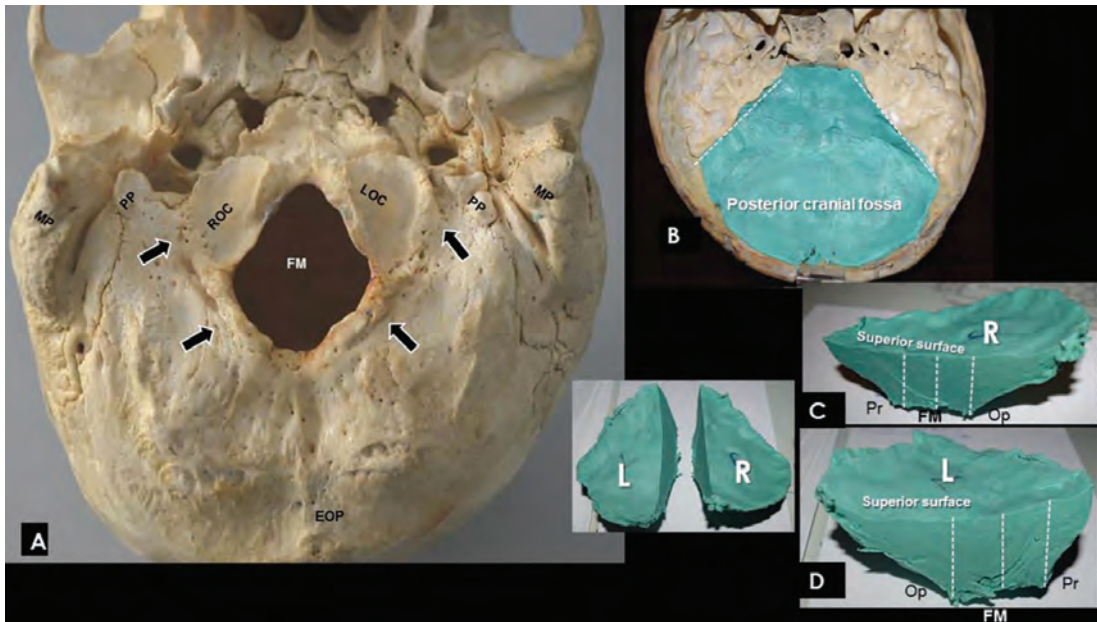


Figure 2A Spongy bone around the right and left occipital condyles (ROC and LOC) and the posterior foramen magnum (FM) rim (arrows). Extremely prominent mastoid processes (MP) and external occipital protuberance (EOP), PP- paracondylar process. B. Posterior fossa filled with dental impression. C, D Left and right half of the impression. Depth measurements at prosthion-Pr, opisthion-Op and the midline of the FM to the superior surface of the impression.

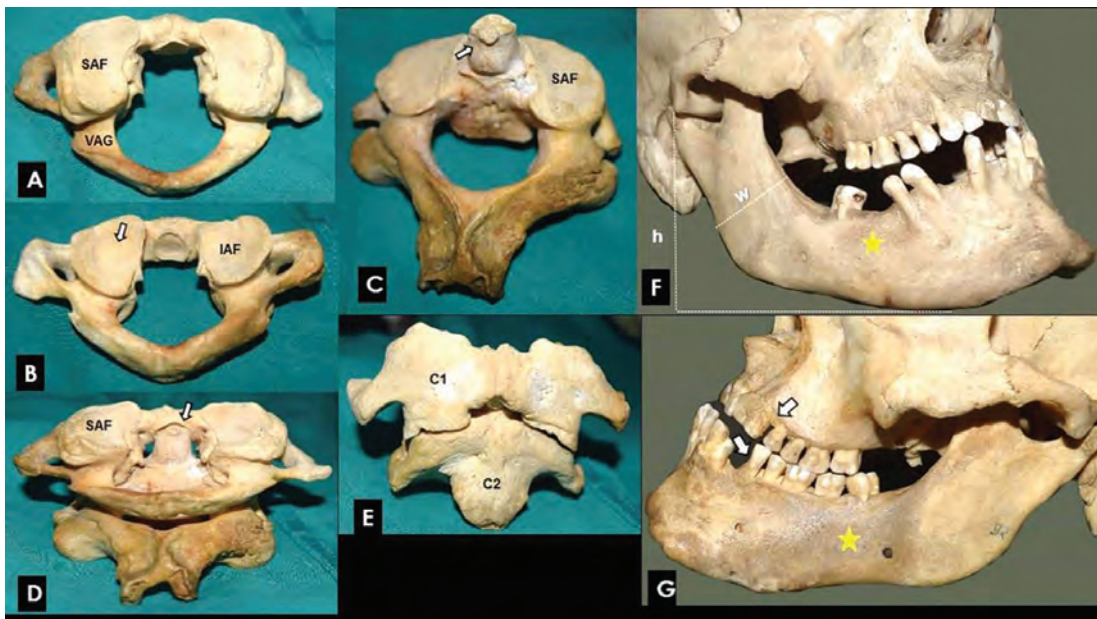


Figure 3A The superior articular facets of the atlas (SAF) and vertebral artery groove (VAG). B. The asymmetric inferior articular facets of the atlas (IAF), arrow indicates right more concave SAF. C. Hypoplastic odontoid process of the axis (arrow), osteophyte formation and asymmetric SAF bilaterally. D. E. The atlanto-axial joint, C<sub>1</sub>- atlas, and C<sub>2</sub>- axis vertebra. Axis vertebral body overgrowth. F. Increased mandibular rami vertical diameter (height-h) and anteroposterior diameter (width-w). G. Periodontal disease inflammation (yellow asterisk) and mandibular incisors enamel hypoplasia (white arrows).



ticular facets of the atlas (Figures 3A, B). The atypical OCs, in combination with the odontoid process hypoplasia and its slight inclination (Figures 3C, D) were responsible for the atlanto-occipital and atlantoaxial instability (5, 6). The gap present between the OCs and the superior articular facets of the atlas indicates atlanto-occipital dislocation. Both atlanto-occipital and atlantoaxial dislocations were associated with a right-sided torticollis.

The mandible was large and elongated, and the dental arches yielded wider interdental spaces. Symphyseal height was markedly increased. The mandibular rami showed a significantly greater vertical diameter (58.40 mm on the right and 59.14 mm on the left) in comparison to the anteroposterior one (41.73 mm on the right and 42.25 mm on the left). Both mandibular condyles were unusually wide. Mandibular overgrowth coexisted with prognathism, malocclusion and overbite. Temporomandibular joint showed arthritic lipping. Mandible bears 14 teeth; no dental occlusion existed in the right dental hemiarch, while traces of abrasion existed in the left hemiarch due to teeth contact. Enamel hypoplasia was present at the mandibular incisors (Figures 3F, G). All measurements were performed by a single investigator by using a digital sliding caliper (accuracy 0.01 mm) and they were taken twice and the average of the two values was taken as the final measurement.

## Discussion

Acromegaly affects both genders equally and occurs with an incidence ranging from 5 to 15 cases per million (7, 8). The true prevalence is higher due to under diagnosis. The excessive skeleton growth depends on the age the disorder becomes active. If the onset of the disease begins early in life (9), as reported in the current case, the ensuing growth is extreme. A benign pituitary ade-

noma may cause GH hypersecretion in 90% of cases, while in the remaining 10%, tumors of the pancreas, lungs or adrenal glands may produce and release GH (10).

Changes in soft tissue and facial bones related to acromegaly have been extensively published and present with a plethora of symptoms. Hydrocephalus may develop due to the pressure exerted on the cerebral aqueduct and the third ventricle. In the reported case, extensive alterations were found in the neurocranium and viscerocranium, as a consequence of the endochondral and periosteal bone growth. We report, for the first time, the coexistence of acromegaly with CCJ deformities, paranasal sinuses expansion and WBs development. The presence of WBs correlates with metabolic bone disease, GH deficiency, connective tissue disorders, skull deformities, bone softening, aplastic sinuses and platybasia (7, 11, 12). Moreover, cartilage overgrowth may provoke mechanical injuries to the TMJ. Apart from the extreme skull and CCJ skeletal alterations, the abnormal growth of the upper and lower extremities in our individual strongly indicates acromegaly. Other clinical manifestations include: arthritis, osteopenia, vertebral fractures, carpal tunnel syndrome, hyperhidrosis, headache, paresthesia, sexual dysfunction, goiter, visual field defects, cardiomyopathy, arrhythmias, valvulopathy, heart failure, insulin resistance, diabetes, hypogonadism, colon anomalies and visceromegaly. Macroglossia, laryngeal and pharyngeal mucosa hypertrophies may lead to upper airway obstruction, hypoventilation, snoring and sleep apnea, which have been reported in 50% of acromegaly patients (7). Unfortunately, no medical records were available about the clinical manifestations of acromegaly in our subject. Regarding differential diagnosis, several syndromes are associated with a skeletal overgrowth, including Sotos, Beckwith-Wiedemann, Weaver, Simpson-Golabi- Behmel, Fragile X, Mc-

Cune Albright, Marfan, Klinefelter, Beals, and Lujan-Fryns syndromes, homocystinuria and pseudoacromegaly. Classic acromegaly is difficult to differentiate from cases combined with McCune-Albright syndrome and fibrous dysplasia (12), or complicated cases of fibrous dysplasia associated with myxomas, such as Mazabraud's syndrome (13).

The reported case focuses on a pathological skull and CCJ aberrations caused by acromegaly. It is important to recognize these alterations, combined with paranasal sinus enlargement, preoperatively. Variants of the frontal sinuses and their expansion into the orbit, optic canal and clinoid process may play a role in the correlation between the frontal sinusitis and orbital complications. Moreover, known frontal sinus over-pneumatization may influence the treatment plan and radiation dose when treating malignancies in the area, to prevent severe complications, such as cerebrospinal fluid fistula and secondary infections (14). In particular the expansion of the sphenoid sinus towards the sella turcica may lead to compression of the optic chiasm. Pituitary adenoma resection is technically challenging due to the anatomic inaccessibility of the pituitary gland and the proximity of the adjacent vital anatomical structures. Therefore, it is of immense significance to know the exact extent of the sphenoid sinus in order preoperatively to locate the exact position of the internal carotid arteries (ICAs), and the limits of the narrow intercarotid space which ultimately makes the trans-sphenoidal approach impossible. Moreover, coexisting ICA abnormalities (elongation, tortuosity, and especially dilatation) warrant particular intraoperative attention. Various complications may occur, including ICA perforation and laceration (0.2-0.4%), iatrogenic formation of pseudoaneurysms, caroticocavernous fistulae, life threatening post-operative hemorrhage, and vasospasm, causing cerebral ischemia (11).

CCJ degenerative changes may cause instability, chronic subluxation and focal atrophy of the upper cervical cord due to the repetitive compression. The OC hypoplasia observed in the current case, as a consequence of atlantoaxial rotation, may lead to transient compression of the vertebral artery, secondary to posterior subluxation of the occiput (15). Hypoplastic OCs, in combination with the odontoid process hypoplasia and its slight inclination are often associated with paramedian type basilar invagination and medullary compression (15, 16).

## Conclusions

The paper reports a case of acromegaly, focusing on the coexistence of the variable and asymmetric skeletal background of the skull and craniocervical area, combined with extensive paranasal sinus pneumatization, significant enlargement of the sella and multiple WBs development. Skull base flattening caused an increased basal angle leading to basilar impression. The atypical OCs, in combination with the odontoid process hypoplasia and its slight inclination, were responsible for atlanto-occipital and atlantoaxial instability. The gap between the OCs and the superior articular facets of the atlas indicate atlanto-occipital dislocation. Both the atlanto-occipital and the atlantoaxial dislocations were associated with torticollis. Skull bone alterations are of paramount importance in choosing the preferred surgical approach. Consecutively, detailed preoperative evaluation and planning, the use of anatomical landmarks, neuronavigation and micro-instrumentation may help skilled and experienced neurosurgeons to remain on the midline and avoid potential vascular injury.

---

### What is already known on this topic

*Acromegaly is a chronic endocrinopathy caused by growth hormone hypersecretion and stimulation of periosteal new bone formation and bone remodeling. Bone resorption is also stimulated. The consequent articular chondrocyte replication*

and hyperfunction lead to cartilage thickening yielding joint widening and hypermobility. Pathognomonic features in the neurocranium include cranial vault thickening, frontal skull bossing, prominent supraorbital ridges and a large external occipital protuberance. In the viscerocranium, nasal bone hypertrophy, maxillary widening, mandibular overgrowth and prognathism, with malocclusion and overbite, may occur.

#### What this study adds

The study adds important information about the morphometric alterations in a megaloccephalic skull and its craniocervical area in a case of acromegaly. The coexistence of an extensive pneumatization of the paranasal sinuses with significant enlargement of the sella and multiple WBs development are highlighted. Skull base flattening (platybasia) led to an increased basal angle leading to basilar impression. The atypical OCs in combination with the odontoid process hypoplasia and its slight inclination were responsible for atlanto-occipital and atlantoaxial instability. Atlanto-axial dislocation existed due to the gap between the OCs and the superior articular facets of the atlas. Both atlanto-occipital and atlantoaxial dislocations were associated with torticollis. Skull bone alterations are of paramount importance in choosing the appropriate surgical approach. Consecutively, detailed preoperative evaluation and planning, the use of anatomical landmarks, neuronavigation and micro-instrumentation may help skilled and experienced neurosurgeons to remain on the midline avoiding potential vascular injury.

**Acknowledgements:** We thank the male subject for his body donation before death, after signing the informed consent.

**Authors' contributions:** Conception and design: KN and MP; Acquisition, analysis and interpretation of data: MP, OM, NL and KN; Drafting the article: MP, OM, NL, KL and AS; Revising it critically for important intellectual content: KN and TT; Approved final version of the manuscript: MP, OM, TT, NL, KL, AS and KN.

**Conflict of interests:** The authors declare that they have no conflict of interest.

#### References

1. Kaur M, Shailaja S, Chandra S, Mamatha B. Acromegaly – A case report with dentist's perspectives and review of literature. *J Adv Oral Research*. 2012;3(2):17-21.
2. Killinger Z, Kužma M, Sterančáková L, Payer J. Osteoarticular Changes in Acromegaly. *Int J Endocrinol*. 2012; 839282.
3. Colao A, Ferone D, Marzullo P, Lombardi G. Systemic complications of acromegaly: epidemiology, pathogenesis, and management. *Endocr Rev*. 2004;25(1):102-52.
4. Chanson P, Salenave S. Acromegaly. *Orphanet J Rare Dis*. 2008;3:17.
5. Natsis K, Lyrtzis C, Totlis T, Anastasopoulos N, Piagkou M. A morphometric study of the atlas occipitalization and coexisted congenital anomalies of the vertebrae and posterior cranial fossa with neurological importance. *Surg Radiol Anat*. 2017;39(1):39-49.
6. Künzler A, Farmand M. Typical changes in the viscerocranium in acromegaly. *J Craniomaxillofac Surg*. 1991;19(8):332-40.
7. Melmed S. Acromegaly pathogenesis and treatment. *J Clin Invest*. 2009;119(11):3189-202.
8. Placzek H, Xu Y, Mu Y, Begelman SM, Fisher M. Clinical and Economic Burden of Commercially Insured Patients with Acromegaly in the United States: A Retrospective Analysis. *J Manag Care Spec Pharm*. 2015;21(12):1106-12.
9. Resnick D. Pituitary disorders. In: Resnick D, Niwayama G, editors. *Diagnosis of Bone and Joint Disorders*. Vol. 4. 2nd ed. Philadelphia, PA: WB Saunders Company; 1988. p. 2173-98.
10. Aegerter E, Kirkpatrick JA. *Orthopedic Diseases. Physiology, Pathology, Radiology*. 4th ed. Philadelphia, PA: WB Saunders; 1975.
11. Ebner FH, Kürschner V, Dietz K, Bültmann E, Nägele T, Honegger J. Craniometric changes in patients with acromegaly from a surgical perspective. *Neurosurg Focus*. 2010;29(4):E3.
12. Mulhern DM. A Probable Case of Gigantism in a Fifth Dynasty Skeleton from the Western Cemetery at Giza, Egypt. *Int J Osteoarchaeol*. 2005;15(4):261-75.
13. Tsitouridis I, Sayegh FE, Natsis K, Goutsaridou F, Melidis D, Emmanouilidou M. Mazabraud's syndrome: MRI evaluation. *Eur J Radiol Extra*. 2003;45(2):83-7.
14. Natsis K, Karabatakis V, Tsikaras P, Chatzibalas T, Stangos A, Stangos N. Frontal sinus anatomical variations with potential consequences for the orbit. Study on cadavers. *Morphologie*. 2004;88(280):35-8.
15. Tubbs RS, Lingo PR, Mortazavi MM, Cohen-Gadol AA. Hypoplastic occipital condyle and third occipital condyle: review of their dysembryology. *Clin Anat*. 2013;26(8):928-32.
16. McGreger M. The significance of certain measurements of the skull in the diagnosis of basilar impression. *Br J Radiol*. 1948;21(244):171-81.