

## Lipoma and Occult Spinal Dysraphism

Harun Brkić, Hasan Altumbabić, Mirza Moranjkic

Neurosurgical Department  
University Clinical Center of Tuzla

Corresponding author:  
Harun Brkić  
Neurosurgical Department  
University Clinical Center of Tuzla  
Trnovac b.b., 75000 Tuzla  
Bosnia and Herzegovina  
e-mail: brkicharun@yahoo.com

Congenital abnormality, an occult spinal dysraphism with spinal lipoma, is a rare dysraphic spinal abnormality. The syndrome, treatments, outcomes, and current controversies are reviewed.

Occult spinal dysraphism usually is usually manifested without clinical changes, either neurological or local changes. Local cutaneous changes associated with occult spinal dysraphism include midline lumbosacral hypertrichosis, lumbosacral cutaneous hemangiomas, lumbosacral dermal sinus and midline lumbosacral subcutaneous lipoma. Neurological changes in spina bifida occulta and spinal lipoma include local and radicular pain, asymmetric hyporeflexia, spasticity, sensory changes, weakness and bowel/bladder dysfunction. A progressive neurological/urological dysfunction limited to the conus medullaris may also suggest other spinal cord syndromes. Ultrasonography, CT scanning, MR imaging, and plain radiography assist with the localization of the conus medullaris level changes but also the identification of the specific spinal elements affected. Surgical intervention for the asymptomatic lipoma of the conus medullaris has been an area of controversy, primarily due to the paucity of studies in which the natural history of this disorder is researched in detail. Excising cutaneous changes is recommended in case of any esthetic or functional disturbances.

Received: 19. 10. 2006.  
Accepted: 20. 11. 2006.

**Key words:** Lipoma; Meningomyelocele; Spina Bifida Occulta; Spinal Cord; Spinal Dysraphism.

### Introduction

Spinal dysraphism is a term that refers to all forms of developmental abnormalities occurring in the midline of the back - from the skin externally to the vertebral bodies internally (1). Although the true incidence of spinal dysraphism is unknown, authors of

some studies have estimated an incidence of 0.05 to 0.25 per 1000 births (2, 3).

The embryonic development includes 50-62 days of postconceptional period. The period between the 18<sup>th</sup> and 32<sup>nd</sup> day is very important for the development of the central nervous system. The neural tube is formed during the 18-48 day period (4, 5,

6). Errors during neurulation may lead to various congenital malformations (4). The most common expression is spina bifida in the lumbosacral region. These abnormalities usually involve the lumbosacral spine, although lesions in the cervical and thoracic region may also occur.

Lipomas of the spine are among the most fascinating lesions encountered by the pediatric neurosurgeon. Terminology related to this particular problem and understanding of spinal lipomas may be difficult, because differentiation of the accumulations of fat in the spinal canal is confusing. Lipomas of the lumbar spine are very rare, and they cause symptoms related to mass effect and secondary compressive radiculopathy. Lipomas of the conus medullaris are the most common form of fatty masses in the spine and can be divided into different forms. These lesions are a manifestation of occult spinal dysraphism and a common cause of the tethered cord syndrome (1, 2).

Spinal dysraphism with lipoma may exist in an open form (spina bifida aperta), and in a closed form, (spina bifida occulta). Mechanical traction of the spinal cord and neural structures in the spinal canal may be a cause of progressive symptoms (7). These symptoms could appear after hypoxic damage within the conus medullaris (8). Blood flow improvement has been noted after the spinal cord has been decompressed surgically.

Clinical manifestations, that are associated with other stigmata, include the dysraphic spinal elements, cutaneous stigmata, vertebral anomalies, orthopedic abnormalities (scoliosis and extremity abnormalities), neurological deterioration at the level of the lower spinal cord, including bowel and bladder dysfunction, and anorectal malformations (9, 10). Usually, there are just cosmetic changes without neurological disturbances during pediatric growth.

Occult spinal dysraphism with lipoma is sometimes manifested without local or neu-

rological changes. Most commonly, lipomas are localized extraspinally and they seldom exhibit intraspinal or intradural localization. Extraspinal and extradural forms are usually presented without neurological changes. It is possible for lipoma to grow and make compression on lumbosacral nerves and cause radicular symptoms. Intradural lipoma is usually manifested with neurological changes, causing compression of the conus medullaris elements.

## **Clinical Features of Lipoma with Spinal Dysraphism**

### *Cutaneous Stigmata*

The cutaneous changes associated with occult spinal dysraphism include the midline lumbosacral cutaneous hemangiomas, lumbosacral hypertrichosis, lumbosacral dermal sinus and midline lumbosacral subcutaneous lipoma (11). Extraspinal lipomas in adolescents are very rare because surgery is usually performed at an earlier age (Figure 1-A, B).

### *Neurological, Orthopedic Changes*

Infants born with spina bifida occulta and lipoma are usually neurologically intact; even though progressive neurological deterioration is common and represents a single most important reason why detection and appropriate treatment is important. The authors of many large-scale studies have demonstrated progressive neurological symptoms in patients left surgically untreated (8).

Low-back pain is very unusual in infants and children, but it is felt by adolescents and adults, commonly manifested as a generalized low-back pain and radicular leg pain, which may vary in distribution over time. Local and radicular pain, weakness, sensory changes, and bowel/bladder dysfunction could occur in occult spinal dysraphism (7, 12).

Deformity of extremities and feet is visible in early childhood in some children har-

boring lipomyelomeningoceles rather than spinal lipoma. These changes are often progressive and most commonly detected later in childhood. Asymmetrical foot deformities (typically cavovarus, but occasionally cavovalgus) arise from asymmetrical innervation of feet. Foot-length, leg-length and limb-length discrepancies, limb pain and progressive joint deformities, such as scoliosis, can be seen as well (11, 13, 14).

### **Anorectal Anomalies**

Lipoma and occult spinal dysraphism have been found to be associated with various anorectal

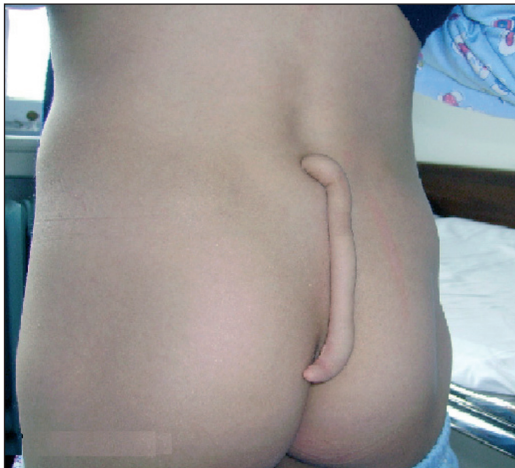

Figure 1. A Skin tag that resembles a tail and a subcutaneous lipoma are displaced out (15 cm)

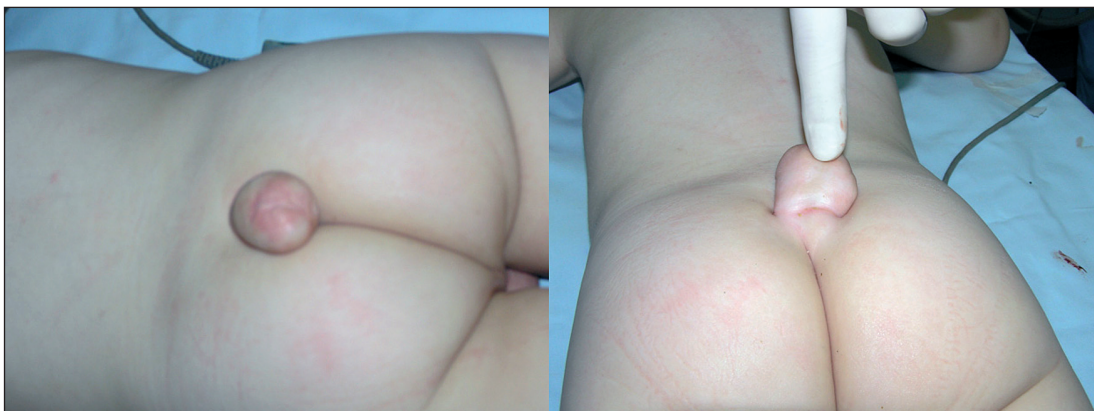

Figure 1. B Subcutaneous lipoma and a cutaneous hemangioma are shown.

and urogenital malformations, albeit rarely. Deterioration of urinary bladder function is common in patients harboring lipomyelomeningocele. The detection of bladder anomalies appears to correlate with the age at which a child is examined and the sensitivity of means by which the patient is evaluated (15, 16).

### **Occult Dysraphic Elements**

Fatty accumulations within the spinal canal represent lesions associated with spina bifida occulta and take three different forms (17):

1. Cutaneous and subcutaneous lipomas that extend into the spinal canal without extension to subdural neural structures (11).

2. The most common form of abnormality is subcutaneous lipoma within the spinal canal that extends through a defect of the paravertebral muscles, lamina, dura, and pia into the low-lying spinal cord. These cases usually come to clinical attention within the first few months or years of life (18, 19).

3. The intradural lipoma (spinal cord lipoma) is a rare intramedullary lesion that is usually found within the thoracic spinal cord. It is not commonly associated with cutaneous or bone anomalies, and it is often manifested with symptoms of spinal cord compression (20). The fatty filum could involve fatty infiltration of the whole length or part of the terminal filum. The fat within the short,

thick filum is discernible by unenhanced CT or MR imaging (21). The occurrence of incidental fat within the terminal filum in the normal adult population has been estimated to be 3.7% in cadaveric studies (22) and 1.5 to 5% in MR imaging studies (22, 23).

### Diagnosis

If occult spinal dysraphism is suspected on clinical grounds, the first logical step is to obtain appropriate neuroimaging studies to define the anatomical and pathological features of the lesion. Ultrasonography is a useful modality to apply on an infant suspected of harboring lipomyelomeningocele (24).

Plain x-ray films almost uniformly demonstrate abnormal findings. The most com-

mon findings include dorsal midline fusion defects (spina bifida) and a widened spinal canal (25).

Computerized tomography myelography provides an excellent resolution of the anomaly; however, this modality is invasive, and requires exposure to radiation as well as lumbar puncture which can be particularly hazardous in the setting of the low-lying conus (Figure 2) (26).

Magnetic resonance imaging has evolved to become the imaging modality of choice for dysraphic states. Lipomatous tissue demonstrates a high signal on T1-weighted MR images and a low signal on T2-weighted MR images. Contrast material administration is not necessary (Figure 3) (27).

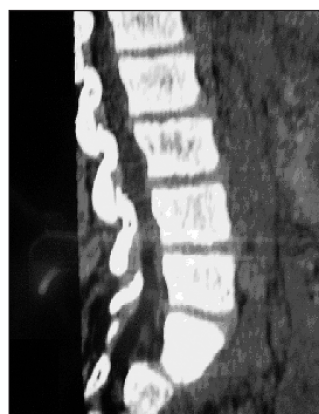
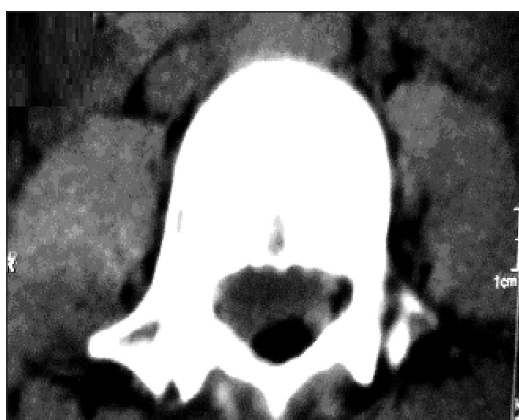

Figure 2. CT lumbosacral region lipoma revealing defect of the lamina and intraspinal lipoma

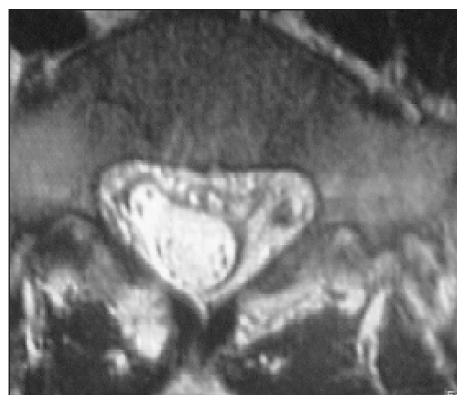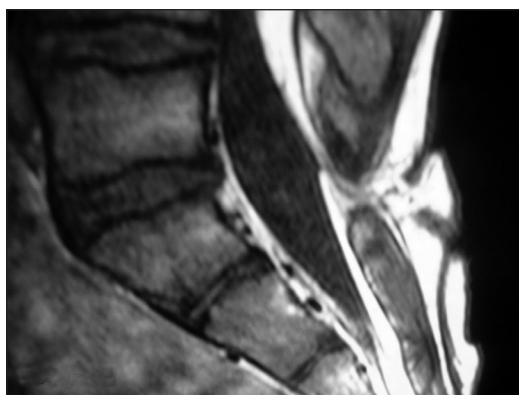


Figure 3. MRI lumbosacral region with spina bifida occulta associated with intradural and extraspinal lipoma

### ***Surgical treatment***

Surgical intervention for the asymptomatic lipoma of the spine has been an area of controversy, primarily due to the paucity of studies in which the natural history of this disorder is detailed (7, 28, 29). Many authors have advocated the use of an early prophylactic surgery to prevent deterioration, noting that asymptomatic patients rarely become symptomatic after the surgical procedure and that a minority of symptomatic patients experienced a reversal of their preoperative deficits (7, 30, 31). Other authors have maintained that, in their series of patients, prophylactic untethering may not prevent some deterioration, and, because the natural history of the asymptomatic lipoma of the conus medullaris is not clearly known, prophylactic untethering may not be warranted (29).

The majority of authors propose early prophylactic surgery in patients with asymptomatic lipoma of the conus medullaris due to the low rate of neurological worsening (3-4%), resulting from the surgery but also because of better neurological outcome in a follow-up of the asymptomatic patients as compared with that of symptomatic patients (7, 19, 30, 31). If indicated, surgical intervention for lipoma on the spinal cord or conus medullaris involves intraoperative identification of the tumor (lipoma) lesions, release of the spinal cord, and reconstruction to as normal anatomy as possible.

The carbon dioxide laser has been found to be useful for debulking and dissecting intradural lipoma and reducing blood loss. Intraoperative electromyography or evoked potentials may also be used (7, 32, 33).

### **Conclusion**

The diagnosis of this abnormality is most easily acquired in the setting of clinical findings that are supplemented with neuro-imaging studies. Clinical evidence of the sub-

cutaneous lipoma, including skin changes, orthopedic anomalies, vertebral anomalies, and associated anorectal malformations may suggest spina bifida abnormality. CT scanning, MR imaging, and plain radiography assist with localization of level of the conus medullaris and the identification of specific changes on the lumbar spine. Neurological and urological status may be further investigated by using electromyography, cystometrography, and evoked potential monitoring.

The goal of the spinal cord surgery is to stabilize neurological function. Surgical intervention for lipoma with spinal dysraphism involves intraoperative identification of the defect of lamina, release of the spinal cord, and reconstruction to as normal anatomy as possible. Surgery-related complications include standard anesthesia-related risks, neurological worsening, cerebrospinal fluid leakage, and meningitis. Surgery is indicated for relevant cosmetic or esthetic disturbances.

### **References**

1. James CC, Lassman LP. Diastematomyelia and the tight filum terminale. *J Neurol Sci.* 1970;10(2):193-6.
2. Kanev PM, Bierbrauer KS. Reflections on the natural history of lipomyelomeningocele. *Pediatr Neurosurg.* 1995;22(3):137-40.
3. Soonawala N, Overweg-Plandsoen WC, Brouwer OF. Early clinical signs and symptoms in occult spinal dysraphism: a retrospective case study of 47 patients. *Clin Neurol Neurosurg.* 1999;101(1):11-4.
4. French BN. The embryology of spinal dysraphism. *Clin Neurosurg.* 1983;30:295-340.
5. Lemire RJ, Siebert JR. Neuroembryology. In: Wilkins RH, Rengachary SS, editors. *Neurosurgery Update II.* New York: McGraw-Hill; 1991. p. 286-91.
6. Streeter GL. Factors involved in the formation of the filum terminale. *Am J Anat.* 1991;25(1):1-11.
7. McLone DG. Occult dysraphism and the tethered spinal cord lipomas. In: Choix M, Di Rocco C, Hockley A, et al, editors. *Pediatric Neurosurgery.* Philadelphia: Churchill Livingstone; 1999. p. 61-78.
8. Yamada S, Zinke DE, Sanders D. Pathophysiology of "tethered cord syndrome". *J Neurosurg.* 1981;54(4):494-503.

9. Schropp C, Speer CP, Schweitzer T, Krauss J: Congenital Skin Lesions in Occult Spinal Dysraphism- What is Typical? *Z Geburtshilfe Neonatol.* 2006;210(6):222-227.
10. Brkić H, Moranjković M: Lumbar lipoma and occult lumbar dysraphism. *Pedijatrija danas* 2007;3(1): 82-86.
11. James CC, Lassman LP: Spinal dysraphism. Spinal cord lesions associated with spina bifida occulta. *Physiotherapy.* 1962;48:154-7.
12. Warder DE, Oakes WJ: Tethered cord syndrome: the low-lying and normally positioned conus. *Neurosurgery.* 1994;(34):597-600.
13. Guthkelch AN: Diastematomyelia with median septum. *Brain.* 1974;97(4):729-42.
14. Lassman LP, James CC: Lumbosacral lipomas: critical survey of 26 cases submitted to laminectomy. *J Neurol Neurosurg Psychiatry.* 1967;30(2):174-81.
15. Davidoff AM, Thompson CV, Grimm JM, Shorter NA, Filston HC, Oakes WJ: Occult spinal dysraphism in patients with anal agenesis. *J Pediatr Surg.* 1991;26(8):1001-5.
16. Warf BC, Scott RM, Barnes PD, Hendren WH 3rd: Tethered spinal cord in patients with anorectal and urogenital malformations. *Pediatr Neurosurg.* 1993;19(1):25-30.
17. Pang D: Tethered cord syndrome: newer concepts. In: Wilkins RH, Rengachary SS, editors. *Neurosurgery Update II.* New York : McGraw-Hill; 1991. p. 336-344.
18. Hoffman HJ, Taecholarn C, Hendrick EB, Humphreys RP: Management of lipomyelomeningoceles. Experience at the Hospital for Sick Children, Toronto. *J Neurosurg.* 1985;62(1):1-8.
19. Oakes WJ: Management of spinal cord lipomas and lipomyelomeningoceles: newer concepts. In: Wilkins RH, Rengachary SS, editors. *Neurosurgery Update II.* New York : McGraw-Hill; 1991. p. 345-52.
20. Ammerman BJ, Henry JM, De Girolami U, Earle KM: Intradural lipomas of the spinal cord. A clinicopathological correlation. *J Neurosurg.* 1976;44(3):331-6.
21. McLendon RE, Oakes WJ, Heinz ER, Yeates AE, Burger PC: Adipose tissue in the filum terminale: a computed tomographic finding that may indicate tethering of the spinal cord. *Neurosurgery.* 1988;22(5):873-6.
22. Uchino A, Mori T, Ohno M: Thickened fatty filum terminale: MR imaging. *Neuroradiology.* 1991;33(4):331-3
23. Brown E, Matthes JC, Bazan C 3rd, Jinkins JR: Prevalence of incidental intraspinal lipoma of the lumbosacral spine as determined by MRI. *Spine.* 1994;19(7):833-6.
24. Chapman P, Stieg PE, Magge S, Barnes P, Feany M: Spinal lipoma controversy. *Neurosurgery.* 1999;44(1):186-92.
25. Colak A, Tahta K, Ozcan OE, Eryilmaz M: Congenital lumbosacral lipomas presenting as a form of occult spinal dysraphism. A report of 9 surgically treated cases. *Zentralbl Neurochir.* 1992;53(1):15-9.
26. McLone D, Thompson D: Lipomas of the spine. In: McLone D, editor. *Pediatric Neurosurgery.* Philadelphia : WB Saunders; 2001. p. 289-301.
27. Patwardhan V, Patanakar T, Patkar D, Armao D, Mukherji SK: MR imaging findings of intramedullary lipomas. *AJR Am J Roentgenol.* 2000;174(6):1792-3.
28. Cornette L, Verpoorten C, Lagae L, Van Calenberghe F, Plets C, Vereecken R, et al: Tethered cord syndrome in occult spinal dysraphism: timing and outcome of surgical release. *Neurology.* 1998;50(6):1761-5.
29. Zerah M, Pierre-Kahn A, Catala M: Lumbosacral lipomas. In: Choix M, Di Rocco C, Hockley A, Wet al, editors. *Pediatric Neurosurgery.* Philadelphia : Churchill Livingstone; 1999. p. 79-100.
30. Byrne RW, Hayes EA, George TM, McLone DG: Operative resection of 100 spinal lipomas in infants less than 1 year of age. *Pediatr Neurosurg.* 1995;23(4):182-6.
31. Kanev PM, Lemire RJ, Loeser JD, Berger MS: Management and long-term follow-up review of children with lipomyelomeningocele, 1952-1987. *J Neurosurg.* 1990;73(1):48-52.
32. Ratliff J, Mahoney PS, Kline DG: Tethered cord syndrome in adults. *South Med J.* 1999;92(12):1199-203.
33. Satar N, Bauer SB, Scott RM, Shefner J, Kelly M, Darbey M: Late effects of early surgery on lipoma and lipomenigocele in children less than 1 year old. *J Urol.* 1997;157(4):1434-7.