

The inframammary dome – a modification of the keyhole pattern for reduction mammoplasty/mastopexy

Srdan Babovic¹, William D. Leighton²

¹Plastic Surgery Department, Olmsted Medical Center, Rochester, Minnesota, USA

²The Leighton Institute for Aesthetic and Reconstructive Plastic Surgery, Scottsdale, Arizona, USA

Corresponding author:

Srdan Babovic
Plastic Surgery Department
Olmsted Medical Center
1650 Fourth street SE
Rochester, Minnesota 55904
USA

SBabovic@olmmed.org
Tel.: + 1 507 529 6740
Fax.: + 1 507 529 6742

Received: 4 April 2011
Accepted: 23 May 2012

Copyright © 2012 by
Academy of Sciences and Arts
of Bosnia and Herzegovina.
E-mail for permission to publish:
amabih@anubih.ba

Dear Editor,

A modification of the keyhole pattern for reduction mammoplasty and mastopexy is presented. An inframammary dome with a 3-cm diameter and 6 cm base is inserted on the inframammary fold. The authors believe that this modification reduces the incidence of vertical incision separation and minimizes later “bottoming out” of the surgically reduced/lifted breast.

Breast reduction and mastopexy are among the few procedures in plastic surgery that test our ability to achieve superb and long lasting aesthetic results. The choice of the appropriate breast reduction technique and attention to fine technical details in planning and execution are very important in determining the outcome of surgery and ultimately, patient satisfaction (1, 2). The inferior pedicle technique and its variations are in wide use thanks to the reliability that the technique offers (3). We present a minor modification of the dependable keyhole pattern with additional technical pearls, proven to be effective in our hands. The senior author has used these modifications in his practice over the last 5 years in 333 patients (161 mastopexies and 172 reduction mammoplasties) with high patient and surgeon satisfaction.

Preoperative markings are made with the patient in the standing position (3). The mid-clavicular line is marked through the nipple. Standard keyhole markings are made and the inframammary fold is then marked. On the mid-clavicular line an inframammary dome is designed with a 3-cm radius and 6 cm base in the inframammary fold (Figure 1).

Note deepithelization of the pedicle, except for the inframammary dome, follows the preoperative markings (4). The new nipple position skin resection is left to be

performed at the end of the procedure, similar to the technique suggested by Hester (5). A figure-of-eight 3-0 Vicryl suture is placed through the nipple in a 3^{hr} to 9^{hr} vector at the beginning of the procedure to facilitate the final nipple position, nipple areola delivery and to prevent rotational distortion (Figure 2).

In the final step of the central and inferior skin flap resection, adjustment is made to fit around the inframammary dome. In this way the tension of the skin flap closure is distributed along a 9.42-cm arch instead of a one-point maximal tension juncture, which is standard with the standard inverted T- closure (Figure 3).

The postoperative course in all our patients has been uneventful with no skin flap necrosis and no incisional separation occurring on the vertical and horizontal scar

connection. Reduction mammoplasty using the inferior glandular pedicle to perfuse the nipple-areola complex has maintained its popularity and proven its reliability over two decades of widespread use (3, 6, 7). The majority of published series report a 5-10% incidence of incisional separation that causes delayed wound healing (5, 8). Different techniques have been recommended for prevention of incisional skin separation, including a double dermal keyhole technique (9) and the sliding nipple technique (10). Both groups report improved cosmetic appearance and decreased early postoperative wound dehiscence. We believe that with the dome modification of the inframammary incision the incidence of wound dehiscence is reduced.

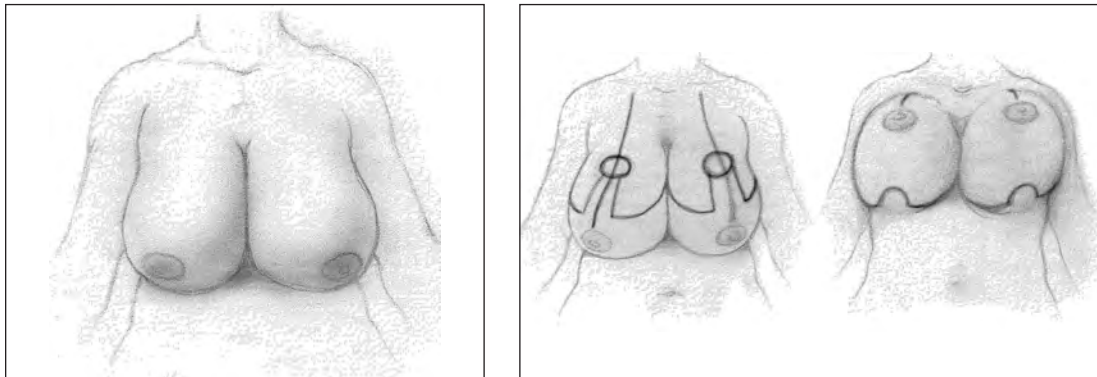


Figure 1 Preoperative markings of the inframammary dome.

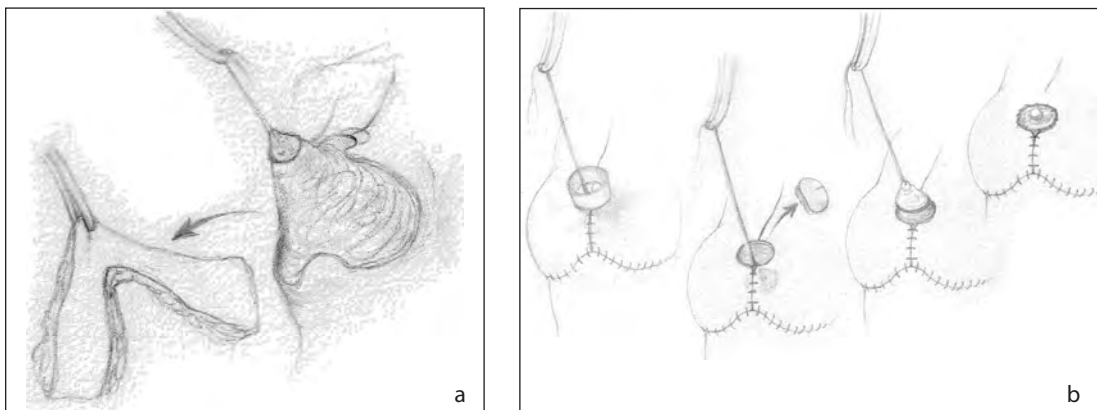


Figure 2 a) Resection; b) Nipple/areola is delivered to the final position.

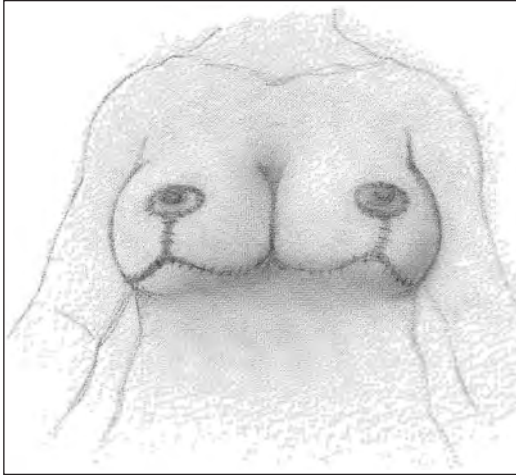


Figure 3 Final inframammary closure.

Authors' contributions: Conception and design: SB and WDL; Drafting the article: SB; Revising it critically for important intellectual content: SB and WDL.

Conflict of interest: The authors declare that they have no conflict of interest. This study was not sponsored by any external organization.

References

1. McKissock PK. Reduction mammoplasty with a vertical dermal flap. *Plast Reconstr Surg.* 1972;49(3):245-52.

2. Aufricht G. Mammoplasty for pendulous breast. *Plast Reconstr Surg.* 1949;4:13.
3. Georgiade GS, Riefkohl RE, Georgiade NG. The inferior dermal-pyramidal type breast reduction: long-term evaluation. *Ann Plast Surg.* 1989;23:203-11.
4. Kroll SS. A comparison of deepithelialization and deskinning in inferior pedicle breast reduction. *Plast Reconstr Surg.* 1988;81(6):913-6.
5. Hester TR Jr, Bostwick J III, Miller L, Cunningham SJ. Breast reduction utilizing the maximally vascularized central breast pedicle. *Plast Reconstr Surg.* 1985;76(6):890-900.
6. Hudson DA. Editorial: Some thoughts on choosing a technique in breast reduction. *Plast Reconstr Surg.* 1998;102(2):554-7.
7. DeBono R, Rao GS. Vasoconstrictor infiltration in breast reduction surgery: is it harmful? *Br J Plast Surg.* 1997;50(4):260-2.
8. Krysander L, Bröte L, Ostrup LT. Reduction mammoplasty: comparison of results of plastic and general surgeons. *Eur J Surg.* 1993;159(5):259-62.
9. Harouche EF. The double dermal keyhole pattern for breast reduction. *Plast Reconstr Surg.* 1995;96(6):1451-3.
10. Holmström H, Lossing C. Reduction mammoplasty with a sliding nipple technique. *Scand J Plast Reconstr Surg Hand Surg.* 1990;24(3):245-52.