

Oral Mucositis

Berislav Topić¹, Ana Cekić-Arambašin²

¹Department of Medical Sciences,
Academy of Sciences and Arts of Bosnia and
Herzegovina, Sarajevo, Bosnia and Herzegovina

²Department of Oral Medicine, Zagreb University
School of Dental Medicine, Zagreb, Croatia

Corresponding author:

Berislav Topić
Academy of Sciences and Arts
of Bosnia and Herzegovina
Bistrik 7, 71000 Sarajevo
Bosnia and Herzegovina

e-mail: btopic@anubih.ba

Received: 27. 07. 2006

Accepted: 11. 10. 2006

Oral mucositis develops in 100% of patients receiving radical radiotherapy for head and neck malignancies, 70%-80% of patients on chemotherapy for bone marrow transplantation, 75% of patients on high-dose chemotherapy, and 40% of patients on standard chemotherapy. The oncologic team managing this casuistics should also include a dental medicine doctor to take active part in the treatment of these patients before, during and after therapy administration because of the associated oral complications. Oral mucositis and xerostomia pose difficulties in the intake of food and drinks, leading to malnutrition and dehydration. An array of agents with a varying therapeutic efficacy is now available for the treatment of oral mucositis. Recently, a novel agent named Gelclair, manufactured by Helsin Birex Pharmaceuticals from Dublin, Ireland, has appeared on the market. Gelclair has proved highly efficacious in the management of oral mucositis, ulcerous lesions of oral mucosa of other etiologies, postoperative wounds in oral cavity, etc. Gelclair has been approved by the US Food and Drug Administration FDA, CE and Drug Commission of the Republic of Croatia as a class 1 medical aid.

Key words: Mucositis; Stomatitis; Antineoplastic Agents; Radiation Injuries; Radiotherapy; Gelclair; Review.

Introduction

Oral mucositis is inflammation of the oral mucosa caused by ionizing radiation and chemotherapeutics (Figure 1).

Stomatitis is inflammation of the oral mucosa caused by infection (Figure 2). Epidemiologic data show cardiovascular diseases to account for 52%, malignancies for

22%, and all other causes of death for 26% of total mortality (1, 2). The prevalence of malignant neoplasms of the head and neck region in men is threefold that in women (3-5). A study conducted in 1993 in the USA found oral carcinoma in 20,300 of 600,000 (3.4%) and 9,500 of 577,000 (1.6%) carcinomas in male and female population, respectively (6). Therapeutic methods for the

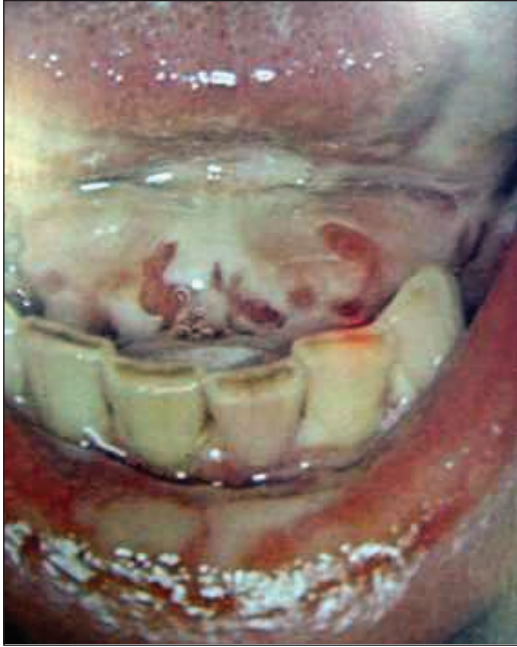

Figure 1. Oral mucositis

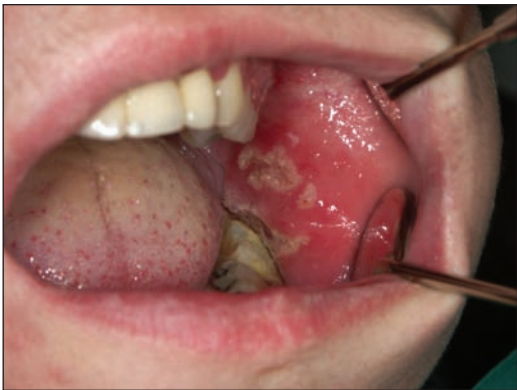

Figure 2. Ulceronecrotic stomatitis in AIDS

management of malignancies include surgical therapy, radiotherapy, chemotherapy, hormone therapy, immunotherapy, and their combinations (7).

Radiotherapy

In medicine, radioactive irradiation is used for experimental, diagnostic and therapeutic purposes. Orofacial region is an area where nuclear medicine finds application in the

radiation casuistics of the head and neck, involving specialist disciplines of neurosurgery, ophthalmology, otorhinolaryngology, cervicofacial surgery, maxillofacial surgery, oral surgery, oral medicine, endocrinology (pituitary, thyroid and parathyroid glands), and dermatology (8, 9).

The potential oral complications of radiotherapy may be acute and chronic. Acute complications include mucositis, xerostomia, infection, dysgeusia, dysphagia and malnutrition, whilst chronic complications are xerostomia, cervical caries, telangiectasias, myofibrosis, trismus, impaired vascularization, soft tissue necrosis, osteoradionecrosis, dentofacial malformations (if exposed to radiation before adolescence), and malnutrition.

Chemotherapy

Along with surgical therapy and radiotherapy, chemotherapy is frequently used as an adjuvant therapeutic method or as a method of choice in bone marrow transplantation. Chemotherapy administered for malignant lesions beyond the head and neck region may also induce oral complications. Local oral secondary infection consequential to myelosuppression is the most common oral complication of chemotherapy; it may lead to sepsis and occasionally to lethal outcome (10). Other complications associated with chemotherapy are electrolyte imbalance, hemorrhage, acute drug toxicity (including nausea and vomiting), photosensitivity, central nervous system dysfunction, alopecia, and inadequate nutrition. Sonis *et al.* describe oral complications (mucositis, ulceration and xerostomia) in 40% of patients treated with standard chemotherapy and free from malignant lesions in the head and neck region (11). Oral complications are reported in 75% of patients on high-dose chemotherapy, 70%-80% of patients with bone marrow transplantation, and 100% of

patients receiving radiotherapy for head and neck malignancies (12-14).

Chemotherapeutics exert an effect on bone marrow and lead to reduced myeloproliferation which results, among other sequels, in thrombocytopenia, leukopenia and neutropenia. These agents also elicit an effect on oral mucosa, manifesting as a decreased mitotic activity of the oral epithelial cells, which in turn results in epithelial atrophy, reduced epithelial resistance to mechanical irritation, mucositis and oral ulcerations. Ulcerations provide free access to secondary infection from massive and virulent oral flora, while the presence of neutropenia may lead to sepsis and its serious sequels, occasionally with lethal outcome.

Dental doctor in oncology team

Malignancies are managed by an oncology team that consists of an oncologist, pathologist, radiologist, hematologist, radiation physicist, dosimetrist, radiology technician, radiology nurse, physiatry technician, psychologist, dietitian, social worker, and specialists in various health care fields, including dental doctor, depending on the given casuistics. Dental doctor as member of the oncology team can upgrade the quality of life in these patients by reducing the severity of acute irradiation complications and preventing the development of chronic irradiation complications (15-17). Patients scheduled for radiotherapy of the head and neck region or for chemotherapy undergo dental examination and dental treatments, which are divided into those administered before, during and after radiotherapy or chemotherapy.

Procedures performed before radiotherapy or chemotherapy:

– oral clinical examination with x-ray of the teeth and jaws (orthopantomography or panoramix and retroalveolar images);

- patient education, instructions and motivation for a higher level of oral hygiene before, during and after therapy administration; an aggressive protocol of oral hygiene;
- complete and thorough dentition and jaw treatment;
- radical approach to dental treatment;
- extraction of all teeth that lack the prognosis of being retained in the oral cavity for >5 years;
- indications for extraction are pulpless teeth, apical periodontitis, teeth requiring endodontic treatment, teeth with true periodontal pockets of >6 mm in depth and furcation involvement, teeth with destroyed crowns, retained root, impacted tooth, no dilemma between extraction and apicoectomy, and teeth adjacent to a tumor (8);
- in patients scheduled for radiotherapy and chemotherapy, tooth extraction should be performed 14-20 days (minimum 10 days) and 7 days (minimum 5 days) before the respective therapeutic modality;
- extraction wound should not be left with sharp margins or alveolar prominence, therefore alveoloplasty should be performed;
- upon tooth extraction, the extraction wound should be sutured to allow for healing at primary intention; a fresh coagulum is sensitive to radiation;
- the regimen of antibiotic administration after tooth extraction is the same as in patients with infective endocarditis, with possible continuation (18);
- cystectomy should be performed when jaw cysts are present;
- removable prostheses should not be used during radiotherapy and for a prolonged time after this therapy; removable prostheses can only be worn at meal and social contacts, as approved and regularly controlled by dental doctor; and
- individual splint for fluorine application in 1% gel should be designed.

Procedures performed during radiotherapy or chemotherapy:

- control of mucositis (ultra soft toothbrush, dental floss for interdental space hygiene without provoking bleeding, chlorhexidine, topical application of 1% sodium fluoride gel by use of the specially designed individual splint);
 - pain control (local anesthetics in the form of gel); and
 - prevention of secondary infection (mouth wash several times a day with a mixture of sodium bicarbonate and table salt, chlorhexidine, nystatin, miconazole).

Procedures performed after radiotherapy or chemotherapy:

- all efforts should be invested for thorough health care of the teeth, gingiva, oral mucosa and pharynx (19, 20);
 - teeth should be washed with a soft toothbrush after each meal and before bedtime;
 - fluorinated toothpastes should be used;
 - tooth necks (cervical caries) and interdental spaces (tooth floss and interdental stimulators) require special hygienic measures that do not induce gingival bleeding;
 - mouth should be washed several times a day with physiologic saline with the addition of sodium bicarbonate;
 - mouth wash shower with moderate pressure dosage should be used, for interdental spaces in particular;
 - post-irradiation xerostomia is quite common; these patients should be instructed as follows: discomforts are alleviated by sipping some fresh drink; a vacuum bottle with water and ice cubes should be brought along in the morning and occasionally sip ice-cold water; sugar-free chewing gum and candies are helpful; if there is no syndrome of burning mouth, it is recommended to spread a mixture of virgin olive oil and lemon juice over oral mucosa (21, 22);

- artificial saline (Glandosan spray, Oral Balance gel, Xero-Lube) should be prescribed;
- sialogogues (pilocarpine hydrochloride solution, Salagen tablets, mallow-root demulcent) should be prescribed;
- vitamin creams (d-panthenol) should be spread over lips; and
- control visits to dental doctor office at appointment, at least once in three months.

Maxillomandibular complications of radiotherapy

Maxillomandibular complications pose a specific problem as post-irradiation sequels with a clinical picture of osteomyelitis, post-irradiation osteonecrosis (PRON) and sequestration (23-26). The risk of these complications is minimized by taking appropriate pretherapeutic dental measures. However, irradiation reduces the bone regenerative ability, impairs interosseous vascular flow, and reduces osteocyte-osteoclast count. The mandible is more vulnerable to these effects than the maxilla (Figure 3).

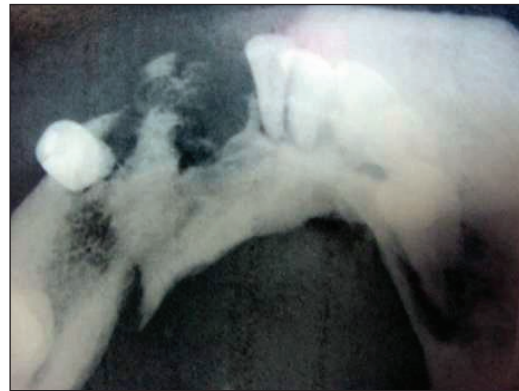


Figure 3. Post-irradiation osteonecrosis of the mandible.

When these complications have set in, the following measures are suggested:

- high doses of antibiotics according to antibiotic sensitivity report;

- oxygenation in hyperbaric chamber to increase tissue oxygenation which stimulates angiogenesis, osteoblast function and fibroblast function (27); and
- critical consideration of surgical therapy if there is no sequestration.

Dietary regimen

Dietary management is extremely demanding in patients receiving radiotherapy and chemotherapy. Oral difficulties (pain, mucositis, ulceration, xerostomia, thick and sticky saliva, absence of tooth and mouth self-cleaning, dysgeusia, depressive mood, stress situations, difficult communication, etc.) require nutritionist's assistance to avoid tube feeding or parenteral nutrition. Low bacteria diet should be introduced. All these measures require education and great patience on patient management. Dietary regimen guidelines are listed below (28):

- caloric protein rich diet containing adequate amounts of vitamins, minerals and water;
- raw foods, uncooked vegetables, fresh unwashed fruits, dried fruit, salad, nuts, hazelnut, uncooked or semi-cooked meat, fish, eggs should be avoided; vegetarian foods should be thoroughly cooked; unboiled milk, old cheese, all kinds of yoghurt (containing bacterial flora), shells, non-pasteurized fruit drinks, uncooked honey, zwieback, and sweets between meals should be avoided;
- only vacuum packed meat with clearly stated expiry date should be used;
- food prepared by street vendors should not be used;
- irritant drinks and sour food should not be used;
- cigarette smoking and alcohol drinks are forbidden;
- alcohol-free mouth wash should be used because alcohol induces mucosal dryness;
- food is taken when the patient is hungry rather than waiting for meal time;

- at least three meals should be taken daily, in the form most appropriate for a particular patient;
- if the amount of food taken by the patient is inadequate, it should be calorie enriched (butter, creams, dressings, cheese, thoroughly washed or peeled sweet fruit);
- perishable food (milk, meat, sandwich) should not be left at room temperature for more than 2 hours;
- food should be tasteful, soft, chopped, nicely served in a cozy atmosphere with nice music and consumed in pleasant company;
- the patient should kindly order food with certain modifications that suit him/her best;
- a popular saying states that "the strength enters the body by mouth"; and
- attention should be paid to the organization of the patient's free time.

Mucositis

Oral mucositis is inflammation of the mucosa caused by ionizing radiation or chemotherapy. Oral mucositis interferes with the patient's quality of life. The intake of food and drinks is difficult or even impossible, leading to malnutrition and dehydration. Communication is hampered due to severe pain (29-31). Clinical evaluation of mucositis is done according to the World Health Organization criteria modified by Scully et al. (32) (Table 1).

Table 1. Clinical evaluation of mucositis

Grade	Clinical feature
0	No mucosal lesions
1	Mucosal sensitivity – erythema
2	Erythema – ulcerations, solid food intake possible
3	Ulcerations, liquid diet required
4	Oral feeding impossible

The casuistics of oral clinical complications following ionizing radiation is presented in Figures 4, 5, 6 and 7.

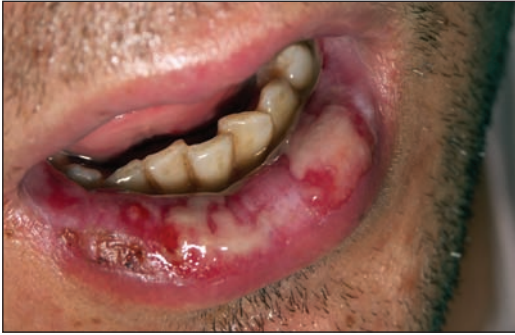

Figure 4. Oral mucositis.

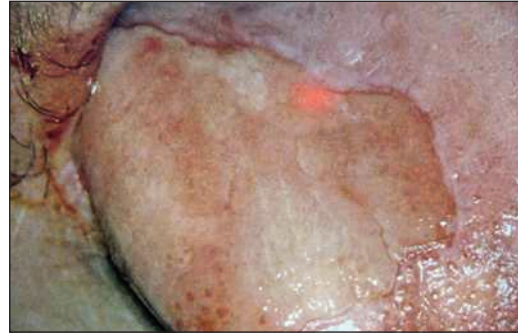


Figure 6. Ulcus linguae.

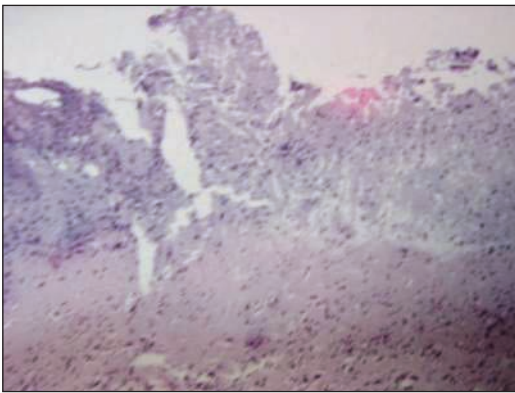


Figure 5. Histopathology finding in oral mucositis.

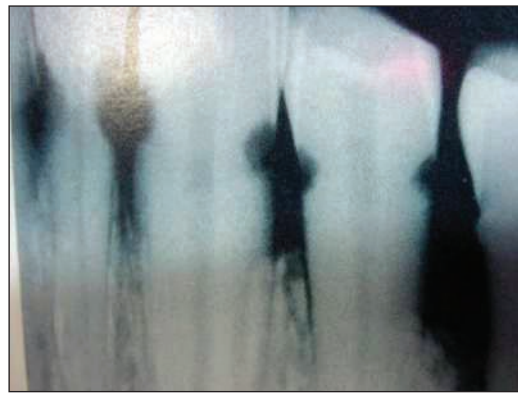

Figure 7. Cervical caries.

Treatment of oral mucositis

The management of oral mucositis includes a wide array of drugs and procedures: local anesthetics, corticosteroids, systemic analgesics, systemic or topical anti-inflammatory agents, antiseptics, antibiotics, mucosal dressing (Orabase), keratinocyte growth factor (stimulating proliferation and differentiation of epithelial cells), interferon, Lysobact, mixture of physiologic saline and sodium bicarbonate, artificial saliva, and various teas.

Patients with poor oral hygiene and untreated teeth have a higher incidence of mucositis, a more severe clinical picture, and longer time to treatment than those with properly treated teeth and good oral hygiene based on an aggressive protocol (Figure 8).

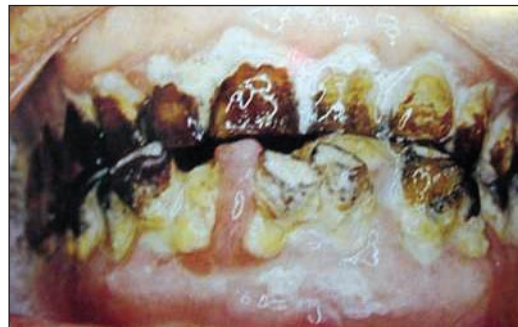

Figure 8. Neglected mouth – severe post-irradiation sequels.

Gelclair, a novel agent for the management of acute symptoms of oral mucositis manufactured by Helsin Birex Pharmaceuticals, Ltd., from Dublin, Ireland, and distributed by Pharmaswiss, Ltd., Zagreb – Sarajevo, has appeared on the market. Gelclair is a viscous oral gel for the treatment of oral

mucositis lesions and oral ulcerative lesions of other etiologies. Gelclair alleviates painful sensitivity by creating mechanical protection in the form of a bioadherent coating that covers and spans mucosal surface discontinuities (ulcers), fills uneven areas while moisturizing damaged tissue, alleviates irritation of denuded nerves in the ulcer area, thus helping the patient to take of food and drinks *per os* as well as in the speech function (Figures 9 and 10).

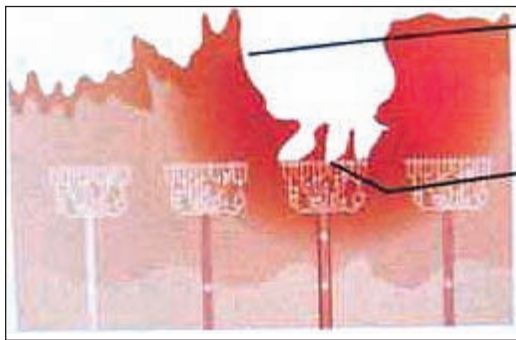


Figure 9. Schematic presentation of oral ulcer.

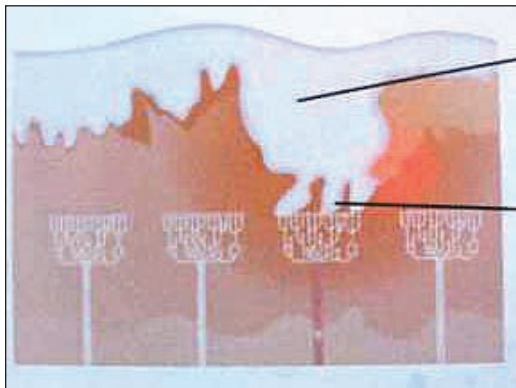


Figure 10. Gelclair dressing adheres to the mucosa, covers the ulcer and shields nerve endings.

Gelclair contains 16 different components, of which the following should be noted:

- polyvinylpyrrolidone (PVP), sodium hyaluronate and glycyrrhetic acid;
- PVP is a hydrophilic polymer which creates a muco adherent coating, increases

tissue moisturizing and accelerates wound healing;

- sodium hyaluronate protects the coating thus formed; its molecules possess the properties of hydration, lubrication and wound repair; and

- the glycyrrhetic acid molecules exert topical antiallergic and anti-inflammatory effects.

The National Cancer Institute describes Gelclair as follows: "Gelclair (approved by FDA). This gel soothes oral mucositis pain by forming protective coating that shields exposed and over stimulated nerve endings" (33). The journal *Hospital Medicine* reports: "Gelclair, a new concentrated oral gel, may provide an interesting new way managing the pain associated with oral mucositis, and it may help patients to eat and drink more easily" (34). A large body of clinical data on the efficacious management of oral sequelae of radiotherapy and chemotherapy by use of Gelclair has been reported in the literature. So, Innocenti *et al.* prescribed Gelclair for 10 days, 3 times daily before meal, in 30 patients diagnosed with ulcerative mucositis, while monitoring pain and deglutition (35). Pain intensity was evaluated according to the Visual Analog Scale (VAS). At 5-7 hours of Gelclair application, pain intensity was reduced by 92%, from 8.2 to 0.6 (Figure 11).

In 7-10 days of Gelclair application, pain associated with swallowing various food contents, e.g., saliva, liquid, liquid creams, semi-solid food, chopped food and normal diet, showed a statistically significant reduction ($p < 0.05$) (Figure 12).

Bonassi *et al.* treated 15 grade III and IV mucositis patients with Gelclair applied 3 times daily (36). Five of these patients had to be hospitalized due to their inability to take food *per os*. The symptom of pain was evaluated according to VAS. After three days of Gelclair application, all patients experienced substantial improvement, on day 7 mucositis showed significant reduction, and on day 19

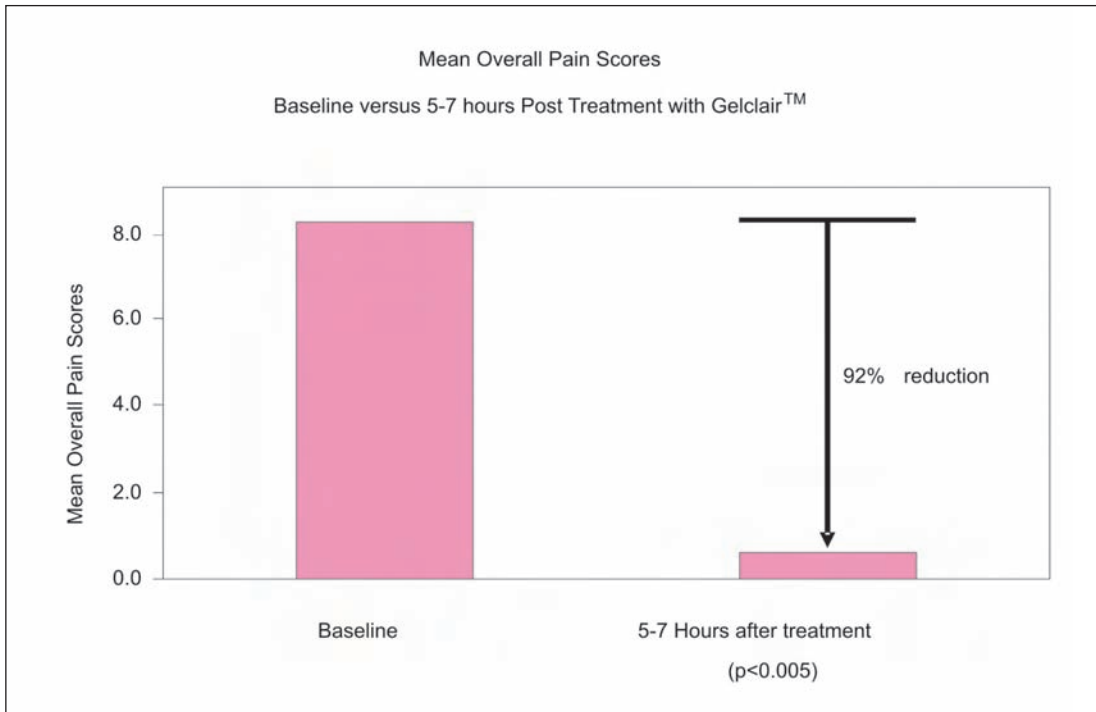


Figure 11. Quantification of pain reduction in mucositis.

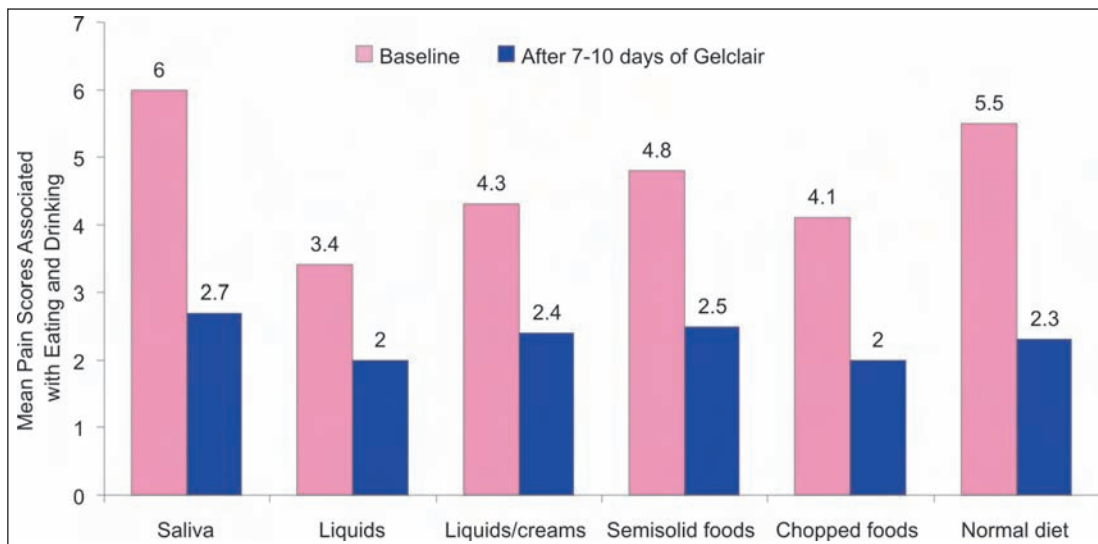


Figure 12. Pain severity on various food intakes.

oral mucosa was completely normal. All patients had the symptom of dysgeusia, which vanished with the regression of mucositis, and the patients showed interest in and need of an increased intake of food and drinks.

In Sweden, ten patients with the diagnosis of oral mucositis were treated with Gelclair during radiotherapy or chemotherapy, and they all continued and completed their therapy without interruption (37).

Gelclair also finds application in oral and maxillofacial surgery after operative procedures in the oral cavity, as exemplified by a Spanish sample of 60 patients (30 in experimental and control group each) with benign tumor lesions and treated with CO₂ laser. Experimental group patients were postoperatively prescribed Gelclair 3 times daily for 7 days. On days 1 and 7, pain reduction and easier food and drink intake yielded statistically significant differences between the experimental and control groups of patients (38). At Department of Oral Medicine, Zagreb University School of Dental Medicine, Gelclair was administered in five patients diagnosed with erythema exudativum (n=2), allergic stomatitis (n=1), ulcus linguae (n=1) and pemphigus vulgaris (n=1). If the area of erosive-ulcerative lesions at zero time point is expressed as 100%, the area involved by the lesion was 47.8% on day 2, 26.4% on day 4, and 9.9% on day 8. Pain severity according to VAS score was 7.6 at zero time point, 6.5 on day 2, 4.5 on day 4, and 2.2 on day 8. All patients reported easier food and drink intake following the application of Gelclair. Gelclair also proved efficacious in soothing pain in patients with ulcer due to dental trauma, after oral surgery procedures, in relapsing aphthae, leukoplakia, oral and gingival lesions associated with AIDS, and oral erosive lichen (33, 39).

Conclusions

1. Oral mucositis is the most common acute oral complication of radiotherapy and chemotherapy.

2. Oral mucositis makes food and drink intake difficult, thus leading to malnutrition and dehydration in these patients. Tube feeding or parenteral nutrition may be needed in some patients.

3. An array of agents to soothe the painful symptoms of oral mucositis is available.

4. A number of clinical studies demonstrated Gelclair, an agent manufactured by Helsin Birex Pharmaceuticals, Ltd. from Ireland, to be efficacious in the management of oral mucositis, oral ulceration of other etiologies, and postoperative treatment of operative wounds in oral cavity.

5. Gelclair has been approved by the Food and Drug Administration, CE and Drug Commission of the Republic of Croatia as a class 1 medical aid.

6. Due to oral sequels of radiotherapy and chemotherapy, an oncologic team should also include a dental medicine doctor for prevention and treatment of the possible oral sequels before, during and after radiotherapy and chemotherapy.

References

1. Zavod za javno zdravstvo FBiH. Zdravstveno statistički godišnjak Federacije Bosne i Hercegovine 2004 : 3. Sarajevo : Zavod za javno zdravstvo FBiH; 2005. p. 9-12.
2. Zavod za statistiku R. Hrvatske. Uzroci smrtnosti u R. Hrvatskoj. Demografski podaci. Zagreb: Zavod za statistiku R. Hrvatske; 2000.
3. Hrvatski zavod za javno zdravstvo. Novi slučajevi raka u R. Hrvatskoj 1999. Bilten 2000; p. 24.
4. Topić B. Egzozna oštećenja oralnih sluznica. In: Malić M, editor. Oralna medicina. Sarajevo : Stomatološki fakultet Univerziteta u Sarajevu; 2001. p. 67-90.
5. Topić B. The prevalence of precancerous lesions in primary dental health care. Radovi ANUBiH (Odjeljenje medicinskih nauka ; Centar za medicinska istraživanja). 2003;92(31; 2): 61-71.
6. ACS Cancer facts and figures – 1993. Atlanta: American Cancer Society; 1993.
7. Dautović S. Tumori. In: Malić M, editor. Oralna medicina. Sarajevo : Stomatološki fakultet Univerziteta u Sarajevu; 2001. p. 371-404.
8. Topić B. Oral sequels of postradiation syndrome. Radovi ANUBiH (Odjeljenje medicinskih nauka). 2004;93(33):55-62.
9. Cekić-Arambašin A, *et al.* Oralna medicina. Zagreb: Školska knjiga; 2005. p. 251.
10. ACS. Cancer manual. 8th ed. Boston : American Cancer Society, Massachusetts Division; 1990.

11. Sonis ST, Sonis AL, Lieberman A. Oral complications in patients receiving treatment for malignancies other than of the head and neck. *J Am Dent Assoc.* 1978;97(3):468-72.
12. Pico JL, Avila-Garavito A, Naccache P. Mucositis: its occurrence, consequences and treatment in the oncology setting. *Oncologist.* 1998;3(6):446-51.
13. Woo SB, Sonis ST, Monopoli MM, Sonis AL. A longitudinal study of oral ulcerative mucositis in bone marrow transplant recipients. *Cancer.* 1993;72(5):1612-7.
14. Kostler WJ, Hejna M, Wenzel C, Zielinski CC. Oral mucositis complicating chemotherapy and/or radiotherapy: options for prevention and treatment. *CA Cancer J Clin.* 2001;51(5):290-315.
15. Meraw SJ, Reeve CM. Dental considerations and treatment of the oncology patients receiving radiation therapy. *J Am Dent Assoc.* 1998;129(2):201-5.
16. Jansma J, Vissink A, Spijkervet FK, Roodenburg JL, Panders AK, Vermey A, et al. Protocol for the prevention and treatment of oral sequelae resulting from head and neck radiation therapy. *Cancer.* 1992;70(8):2171-80.
17. Vissink A, Burlage FR, Spijkevert FK, Jansma J, Coppes PR. Prevention and treatment of the consequences of head and neck radiotherapy. *Crit Rev Oral Biol Med.* 2003;14(3):213-25.
18. Topić B, Alajbeg I. Prevencija bakterijskog endokarditisa u praksi polivalentnog stomatologa. *Stomatološki dani BiH sa internacionalnim učešćem, 2. Knjiga sažetaka.* Sarajevo : Stomatološki fakultet Univerziteta u Sarajevu; 2003. p. 51.
19. Silverman S Jr. *Oral cancer.* 3rd ed. Atlanta : American Cancer Society; 1990.
20. Sonis ST, Fazio RC, Fang L. *Principles and practice of oral medicine.* 2nd ed. Philadelphia : Saunders; 1995. p. 46-54.
21. Fox PC. Management of dry mouth. *Dent Clin North Am* 1997; 41(4):863-75.
22. Topić B. Višestruke funkcije sline. *Medix* 1999; 5(25/26): 110-2.
23. Epstein JB, Wong FLW, Stevenson-Moore P. Osteoradionecrosis: clinical experience and a proposal for classification. *J Oral Maxillofac Surg.* 1987; 45(2): 104-10.
24. Epstein JB, Rea G, Wong FLW, Stevenson-Moore P. Osteoradionecrosis: study of the relationship of dental extractions in patients receiving radiotherapy. *Head Neck Surg.* 1987; 10(1): 48-54.
25. Vissink A, Jansma J, Spijkervet FK, Burlage FR, Coppes RP. Oral sequelae of head and neck radiotherapy. *Crit Rev Oral Biol Med.* 2003; 14(3): 199-212.
26. Sciubba JJ, Goldenberg D. Oral complications of radiotherapy. *Lancet Oncol.* 2006; 7(2): 175-83.
27. Myers RA, Marx RE. Use of hyperbaric oxygen in postradiation head and neck surgery. *NCI Monogr.* 1990; 9: 151-7.
28. Sheean PM. Nutrition support of blood or marrow transplant recipients: how much do we really know? *Nutr Iss Gastroenterol* 2005; Series 26(1): 84-97.
29. Šoda A. Oralni mukozitis i mogućnosti liječenja. *Hrvat Stomatol Vjesn.* 2006; 13(2): 10-1.
30. Brailo V. Oralne komplikacije zračenja glave i vrata. *Hrvat Stomatol Vjesn.* 2006; 13(2): 12-5.
31. Konjhodžić-Prcić A, Cekić-Arambašin A, Malić M. Incidence of radiation induced mucositis in Bosnian population. *Oral Dis.* 2006; 12(Suppl 1): 13-30.
32. Scully C, Epstein J, Sonis S. Oral mucositis: a challenging complication of radiotherapy, chemotherapy and radiochemotherapy. Part 2: Diagnosis and management of mucositis. *Head Neck.* 2004; 26(1): 77-84.
33. National Cancer Institute. Oral complications of chemotherapy and head/neck radiation: health professional version 2005; Available from: <http://www.cancer.gov/cancertopics/pdq/supportivecare/oralcomplications/healthprofessional>.
34. Smith F, Gelclair: managing the symptoms of oral mucositis. *Hosp Med.* 2001; 62(10): 623-6.
35. Innocenti M, Moscatelli G, Lopez S. Efficacy of gelclair in reducing pain in palliative care patients with oral lesions: preliminary findings from an open pilot study. *J Pain Symptom Manage.* 2002; 24(5): 456-7.
36. Bonassi L, Cotroneo G, Nastasi G. Treatment with Gelclair in patients suffering grade III-IV oral mucositis: efficacy and impact on quality of life (QOL). *Ann Oncol.* 2003; 14(Suppl 4, Abstract 38): 58.
37. Berndtson M. Preliminary study of Orassist (Gelclair) in the management of oral mucositis. *Swed Hosp Dent.* 2001; 26(1): 17-21.
38. Hita-Iglesias D, Torres-Legares D, Gutierrez-Perez JL. Evaluation of the clinical behaviour of a polyvinylpyrrolidone and sodium hyalonurate gel (Gelclair) in patients subjected to surgical treatment with CO2 laser. *Int J Oral Maxillofac Surg.* 2006; 35(6): 514-7.
39. Topić B, Cekić-Arambašin A, Malčić S. Oral lichen ruber (OLR) epidemiology and clinical findings in 143 cases. *Acta Stomatol Croat.* 1996; 30(2): 111-5.