

Gastrocolic Trunk: Anatomical Variations and Surgical Significance

Grigorios Stefanou, Dimosthenis Chrysikos, Dimitrios Filippou, George Tsakotos, Theodore Troupis

Department of Anatomy, School of Medicine, Faculty of Health Sciences, National and Kapodistrian University of Athens, Athens, Greece

Correspondence: grigorios.stefanou@gmail.com; Tel.: +30 695 9086907

Received: 21 November 2025; **Accepted:** 6 February 2026

Abstract

Objective. This review aims to summarize the Henle trunk configurations and tributary patterns presented in cadaveric, intraoperative, and imaging studies. **Background.** The Henle gastrocolic trunk is a highly variable venous structure formed by the confluence of the gastric, colic, and pancreatic veins. It has notable surgical importance, particularly during laparoscopic procedures, such as right colectomy and pancreaticoduodenectomy. **Methods.** A systematic review was performed in accordance with the Preferred Reporting Items for Systematic Reviews and Meta-Analyses (PRISMA) guidelines. A comprehensive literature search was conducted using the PubMed/MEDLINE and Google Scholar databases. **Discussion.** Twenty-one publications comprising 2,454 cases were analyzed to classify Henle trunk configurations and tributary patterns. The trunk was identified in 92.5% of the cases, with the gastropancreatocolic (GPC) type being the most prevalent (73.1%). A total of 38 unique venous confluences were recorded, highlighting the considerable anatomical complexity and variability of the trunk. The Henle gastrocolic trunk is a common anatomical structure with significant heterogeneity in its venous configurations. The GPC type, most frequently formed by the confluence of the right gastroepiploic vein, the anterior superior pancreaticoduodenal vein, and either the right colic vein or the superior right colic vein, predominates across cadaveric, intraoperative, and imaging studies. Understanding this variability is crucial for ensuring safe dissection during pancreatic and colorectal resections. **Conclusion.** Comprehensive knowledge of the Henle trunk anatomy and its variations enhances operative planning, minimizes the risk of vascular injury, and supports safer and more efficient minimally invasive abdominal surgery.

Key Words: Henle Gastrocolic Trunk ▪ Venous Anatomy ▪ Colorectal Surgery ▪ Pancreaticoduodenectomy.

Introduction

Anatomical variation is not an exception but the rule and represents a foundational principle of human biology, particularly evident in the venous anatomy of the gastrointestinal tract (1). In 1868, Jacob Henle characterized a venous variation, the venous trunk of Henle (also known as the Henle gastrocolic trunk), as a blood vessel that a) consists of two branches, the right gastroepiploic vein (RGEV) and the right colic vein (RCV), and b) drains into the superior mesenteric vein (SMV) at the lower edge of the pancreas (2). In 1912, Decomps et al. discovered a pancreatic tributary associated with the Henle trunk, which they referred to as either the anterior superior

pancreaticoduodenal vein (ASPDV) or the anterior inferior pancreaticoduodenal vein (AIPDV) (3). This finding completed the definition of the Henle trunk as a tripod anatomical structure. Given the growing importance of the Henle trunk in surgical procedures, further research has identified new tributaries and various possible confluences of these veins (4-7).

In recent years, laparoscopic techniques for colon cancer have progressed notably, with the adoption of complete mesocolic excision (CME) and central vascular ligation (CVL) during right colectomy rising significantly (8, 9). Such procedures can result in complications, such as severe bleeding; thus, successful outcomes depend on a precise understanding of essential anatomical

structures, such as the trunk of Henle (10). It is crucial to identify the veins draining into the Henle trunk when performing a pancreaticoduodenectomy (11). Dissection at the trunk of Henle provides access to the infrapancreatic section of the superior mesenteric vein (SMV), which is essential during the Whipple procedure (12). Consequently, numerous research teams have investigated the anatomical structure of the Henle trunk using intraoperative and advanced imaging techniques in recent years (13-15).

This study aimed to gather and examine both historical and contemporary scientific data to accurately describe the morphological characteristics of the Henle trunk.

Methods

This systematic review was conducted following the guidelines set out by the Preferred Reporting Items for Systematic Reviews and Meta-Analyses (PRISMA) (16, 17). The review protocol was submitted to the Institutional Review Board of the Department of Anatomy at the National and Kapodistrian University of Athens, Greece, and is accessible upon request. A literature search across the PubMed/MEDLINE and Google Scholar databases was conducted to assess the anatomy of the Henle trunk using the search terms: “Henle gastrocolic trunk,” “trunk of Henle,” “Henle’s gastrocolic trunk,” “gastrocolic trunk,” “gastrocolic vein,” “gastrocolic trunk of Henle,” “gastrocolic veins,” “gastro-colic venous trunk,” as well as the Boolean operators “AND” and “OR.” All co-authors approved the study protocol. Language restrictions were applied, considering only articles published in English, French, or German. Two investigators (GS and DC) independently conducted literature searches and extracted data from all eligible studies. Review articles were excluded, whereas all prospective and retrospective studies, along with case reports, were included in this systematic review.

Furthermore, all references were reviewed to identify relevant reviews, and suitable articles were retrieved from this search for potentially relevant conference abstracts. The titles of

interest were further examined through their abstracts. Eligible articles were identified from the inception of the databases until November 2025. Ultimately, 21 studies were included in the analysis (4-6, 10, 11, 13-15, 18-30), encompassing cadaveric, intraoperative, and imaging studies involving a total of 2,454 subjects. The studies were categorized based on their methodological approaches for the stratified analysis. To evaluate the distribution of venous confluences, the frequency of each identified configuration of the Henle trunk was calculated. A chi-square test was conducted to determine whether the distribution of the 38 identified venous confluences significantly deviated from a uniform distribution, with statistical significance set at $P < 0.001$.

Results

Article Selection

The search strategy retrieved 41 articles that were considered for full-text evaluation. Twenty-one studies were deemed eligible and were included in the analytic cohort. Overall, studies encompassing a total of 2454 patients were included in this systematic review. The search strategy is illustrated in Figure 1.

Analysis of Henle Trunk Tributaries

The Henle trunk presents high variability, consisting of many different combinations of venous tributaries. The literature presents distinct views concerning the definition of the Henle trunk. In this study, the Henle trunk was defined as any combination of gastric, colic, and pancreatic venous tributaries draining on the right border of the superior mesenteric vein below the pancreas. To organize our findings, the studies were grouped into cadaveric, intraoperative, and imaging studies.

Cadaveric Studies

Seven studies, including 296 cases, described Henle vessel variations using cadaveric examinations (Table 1).

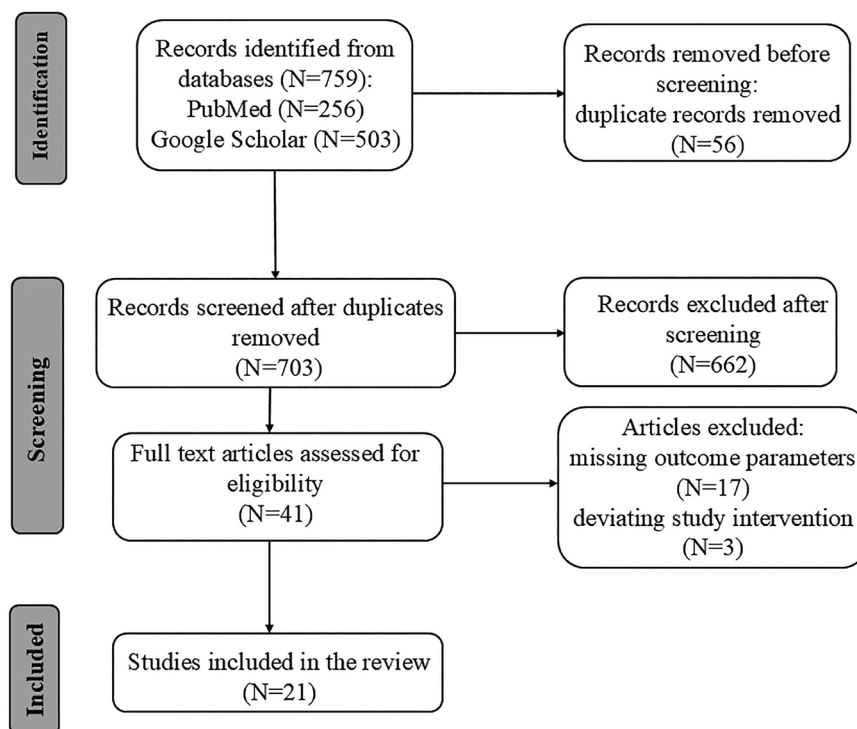


Figure 1. PRISMA flow diagram of study selection.

Table 1. Henle Trunk Forming Veins

Study Type	Author	Year	Cases	Frequency	Confluences	Number of Subjects
Cadaveric	Zhang et al. (4)	1994	54	51	RGEV + ASPDV + SRCV	18
					RGEV + ASPDV + SRCV + antral branch of the right gastroepiploic v.	5
					RGEV + ASPDV + SRCV + AIPDV	3
					RGEV + ASPDV + SRCV + middle right colic vein	1
					RGEV + ASPDV + SRCV + retropyloric v.	1
					RGEV + ASPDV	13
					RGEV + ASPDV + AIPDV	5
					RGEV + AIPDV	1
	Yamaguchi et al. (5)	2002	58	41	RGEV + SRCV	4
					RGEV + ASPDV + MCV	7
					RGEV + ASPDV + aMCV	23
					RGEV + ASPDV + RCV	11
	Ignjatovic et al. (19)	2004	10	10	RGEV + ASPDV+MCV	1
					RGEV + ASPDV	9
	Jin et al. (20)	2006	9	9	RGEV + ASPDV + SRCV + RCV	4
					RGEV + ASPDV + SRCV	3
RGEV + ASPDV + SRCV + RCV + MCV					1	
RGEV + ASPDV					1	
Ignjatovic et al. (18)	2010	42	34	RGEV + ASPDV + SRCV	25	
				RGEV + SRCV	9	

Continuation of Table 1.

Study Type	Author	Year	Cases	Frequency	Confluences	Number of Subjects				
Cadaveric	Açar et al. (21)	2014	12	12	RGEV + ASPDV + SRCV	8				
					RGEV + ASPDV + SRCV + MCV	2				
					RGEV + ASPDV + SRCV + RCV	1				
					RGEV + ASPDV	1				
	Kuzu et al. (6)	2017	111	111	RGEV + ASPDV + RCV	46				
					RGEV + ASPDV + SRCV + RCV	14				
					RGEV + ASPDV + SRCV	12				
					RGEV + ASPDV + RCV + MCV	4				
					RGEV + ASPDV + RCV + ICV	3				
					RGEV + ASPDV + MCV	2				
					RGEV + ASPDV + ICV	2				
					RGEV + ASPDV + SRCV + RCV + MCV	2				
					RGEV + ASPDV + SRCV + RCV + ICV	2				
					RGEV + ASPDV	24				
Intraoperative	Lange et al. (22)	2000	37	33	RGEV + ASPDV + SRCV	14				
					RGEV + ASPDV	16				
					RGEV + SRCV	3				
	Lee et al. (10)	2016	116	116	RGEV + ASPDV + SRCV	63				
					RGEV + ASPDV + SRCV + aSRCV	29				
					RGEV + ASPDV	19				
					ASPDV + SRCV	5				
	Alsabilah et al. (23)	2017	70	55	RGEV + ASPDV + RCV	10				
					RGEV + ASPDV + aMCV	5				
					RGEV + ASPDV + RCV + MCV	2				
					RGEV + ASPDV + MCV	2				
					RGEV + ASPDV	36				
	Wu et al. (24)	2019	60	53	RGEV + ASPDV + RCV	14				
					RGEV + ASPDV + RCV + MCV	10				
					RGEV + ASPDV + MCV	4				
					RGEV + ASPDV	5				
					RGEV + RCV	13				
					RGEV + MCV	1				
					RGEV + RCV + MCV	5				
					RGEV + double RCV	1				
					He et al. (13)	2022	583	567	RGEV + ASPDV + RCV	253
									RGEV + ASPDV + sRCV	32
	RGEV + ASPDV + MCV	14								
	RGEV + ASPDV + aMCV	4								
	RGEV + ASPDV + RCV + sRCV	64								
	RGEV + ASPDV + RCV + MCV	55								
	RGEV + ASPDV + RCV + aMCV	26								
	RGEV + ASPDV + sRCV + MCV	4								
RGEV + ASPDV + sRCV + aMCV	2									
RGEV + ASPDV + RCV + ICV	2									
RGEV + ASPDV + RCV + SRCV + MCV	17									
RGEV + ASPDV + RCV + SRCV + aMCV	11									
RGEV + ASPDV + RCV + MCV + aMCV	2									
RGEV + ASPDV + RCV + SRCV + aSRCV	1									
RGEV + ASPDV	80									

Continuation of Table 1.

Study Type	Author	Year	Cases	Frequency	Confluences	Number of Subjects
Intraoperative	Ghimire et al. (30)	2024	49	45	RGEV + ASPDV + SRCV	21
					RGEV + ASPDV + SRCV + RCV	11
					RGEV + ASPDV + SRCV + RCV + MCV	1
					RGEV + ASPDV	12
Imaging	Sakaguchi et al. (25)	2010	102	79	RGEV + SRCV	42
					RGEV + SRCV + RCV	15
					RGEV + SRCV + MCV	10
					RGEV + SRCV + RCV + MCV	9
					RGEV + MCV	2
					RGEV + RCV	1
	Ogino et al. (26)	2014	81	71	RGEV + ASPDV + RCV	29
					RGEV + ASPDV + RCV + MCV	22
					RGEV + ASPDV + RCV + SRCV	14
					RGEV + ASPDV + SRCV + RCV + MCV	3
					RGEV + ASPDV + RCV + MCV + ICV	2
	Miyazawa et al. (11)	2015	120	100	RGEV + ASPDV + ICV	1
					RGEV + ASPDV + SRCV	71
					RGEV + ASPDV + SRCV + MCV	13
RGEV + ASPDV + SRCV + RCV					7	
Gao et al. (27)	2018	120	102	RGEV + ASPDV	7	
				RGEV + ASPDV + SRCV	32	
				RGEV + ASPDV + RCV	17	
				RGEV + ASPDV + SRCV + RCV	12	
				RGEV + ASPDV + SRCV + RCV + MCV	5	
				RGEV + ASPDV + MCV	3	
				RGEV + SRCV	12	
				RGEV + RCV	8	
				RGEV + SRCV + RCV	7	
				RGEV + SRCV + MCV	4	
Gu et al. (28)	2021	96	78	RGEV + RCV + MCV	2	
				RGEV + ASPDV + RCV	36	
				RGEV + ASPDV + SRCV + RCV	22	
				RGEV + ASPDV + SRCV + MCV	12	
				RGEV + ASPDV + MCV	2	
Grytsenko et al. (29)	2022	103	83	RGEV + ASPDV	6	
				RGEV + ASPDV + RCV	55	
				RGEV + ASPDV + MCV + aMCV	12	
				RGEV + MCV	15	
Yu et al. (14)	2023	418	418	RGEV + RCV + ICV	1	
				RGEV + ASPDV + SRCV	158	
				RGEV + ASPDV + RCV + SRCV	66	
				RGEV + ASPDV + RCV	20	
				RGEV + ASPDV	122	
Zhao et al. (15)	2024	203	203	RGEV + ASPDV + SRCV	114	
				RGEV + ASPDV + SRCV + RCV	24	
				RGEV + ASPDV + SRCV + MCV	23	
				RGEV + ASPDV + MCV	5	
				RGEV + ASPDV + SRCV + ICV	3	
				RGEV + ASPDV + SRCV + MCV + ICV	1	
RGEV + ASPDV	33					

The occurrence of the Henle trunk varied from 71% (5) to 100% in three of the seven studies (6, 18, 21). The gastro-pancreato-colic (GPC) type of the Henle trunk was the most frequent type in most studies, reaching 100% in the report by Kuzu et al. (6). The gastro-pancreatic trunk (GP) was more common in only two studies (19, 23). The GPC Henle trunk was formed by the RGEV, ASPDV tributaries, and a colic vein. The colic vein was either SRCV (4, 18, 21) or RCV (6) in most cases. However, in the study by Yamaguchi et al. (5), the accessory MCV (aMCV) appeared as the most common colic vein. In some studies, a combination of more than one colic vein contributed to the Henle trunk (4, 20, 21). In rare cases, the ileocolic vein (ICV) was also described as a tributary of the trunk (6). With respect to the pancreatic veins, the anterior superior pancreaticoduodenal vein is the pancreatic tributary present in almost all cases, whereas the anterior inferior pancreaticoduodenal vein (AIPDV), though rarely encountered, was also observed as a feature of the Henle trunk (4).

Intraoperative Studies

Intraoperative studies (Table 1) represent the most accurate method for identifying variations of the trunk of Henle. In recent years, many reports comprising a considerable number of cases have contributed to the clarification of the anatomy of the trunk (13, 24). The six intraoperative studies presented in Table 1 comprise 915 cases, of which 692 were reported in the last six years. The Henle trunk is present in a high percentage of intraoperative studies, starting from 79% (23) and reaching 100% (10). The gastro-pancreato-colic (GPC) type dominates the Henle trunk in these studies (10, 13, 24), in accordance with the cadaveric analysis reported above. The only exception is the study by Alsabilah et al. (23), where the gastro-pancreatic (GP) type occurs more frequently than the GPC type. RGEV and ASPDV are gastric and pancreatic tributaries, respectively, that are always observed in the GPC trunk during surgery. In most cases, the colic vein is the SRCV (10) or the RCV (13), appearing separately or together. The MCV is also found in more

recent analyses (13, 25, 29), mostly in combination with the SRCV and RCV, and rarely alone (24, 25). ICV has also been reported in a limited number of studies (13) in combination with other colic veins.

Imaging Studies

The preoperative evaluation of the complex and diverse trunk of Henle before laparoscopic surgery is extremely important since it helps avoid intraoperative bleeding and serves as an anatomical marker due to the particularity of its location (14). Modern 3D imaging techniques are noninvasive and reliable, offering great assistance to surgeons. Imaging studies of the Henle trunk comprise 8 studies and 1243 cases (Table 1), in which the percentage of the trunk varies from 75% (26) to 100% (14, 15). Consistent with the cadaveric and intraoperative studies mentioned above, the GPC type of the trunk is the most abundant, with the exception of the study by Sakaguchi et al. (25), where, surprisingly, the ASPDV vein is completely absent. The SRCV appears again more frequently in this Henle type (11, 14, 15, 27), along with the RCV (26, 28, 29). Rare colic tributaries, such as the ICV or aMCV, have also been reported in imaging studies (15, 26, 29). The ASPDV monopolizes the pancreatic tributaries.

Henle Trunk Tributaries Summary

Overall, the Henle trunk is present in percentages ranging from 71% to 100% of all cases studied using the three different approaches mentioned above, whereas the pooled prevalence of the trunk is 92.54%. The GPC is the main type of the trunk, corresponding to 73.09%, followed by the GP at 17.17% and GC at 9.51%. The PC type is very rare, accounting for only 0.22% of cases. The SRCV, RCV, and the combination of the two account for approximately 57.29% of the 73.09% of the GPC Henle trunk and 7.31% of the 9.51% of the GC trunk. The two veins also appear in combination with other colic veins, thereby increasing their total percentage. MCV is also often present in the GPC type of the trunk, representing alone

or in combination with other colic veins, 9.64% of the GPC type. MCV is also a tributary of the GC Henle type. The colic veins, aMCV and ICV, are rarely part of the trunk. ASPDV is the prevalent vein of the pancreatic tributaries since only Zhang (4) refers to another pancreatic vein, the AIPDV.

Analysis of Venous Trunk Confluences

A total of 38 different types of venous confluences forming the venous trunk of Henle were found (Table 2).

Table 2. Chi-Square Analysis of the Distribution of the Henle Trunk Configurations

Confluences	Frequency	Percentage	P-value
RGEV + ASPDV + SRCV	550	24.22	<0.001
RGEV + ASPDV + RCV	512	22.54	<0.001
RGEV + ASPDV	384	16.91	<0.001
RGEV + ASPDV + SRCV + RCV	239	10.52	<0.001
RGEV + SRCV	122	5.37	<0.001
RGEV + ASPDV + RCV + MCV	91	4.0	<0.001
RGEV + ASPDV + SRCV + MCV	54	2.38	<0.001
RGEV + ASPDV + MCV	38	1.67	<0.001
RGEV + ASPDV+ aMCV	34	1.50	<0.001
RGEV + ASPDV + SRCV + RCV + MCV	31	1.37	<0.001
RGEV + ASPDV + SRCV + aSRCV	29	1.28	<0.001
RGEV + ASPDV + RCV + aMCV	26	1.14	<0.001
RGEV + SRCV + RCV	22	0.97	<0.001
RGEV + RCV	22	0.97	<0.001
RGEV + MCV	18	0.79	<0.001
RGEV + SRCV + MCV	14	0.62	<0.001
RGEV + ASPDV + RCV + MCV +aMCV	14	0.62	<0.001
RGEV + ASPDV + RCV + SRCV + aMCV	11	0.48	<0.001
RGEV + SRCV + RCV + MCV	9	0.40	<0.001
RGEV + RCV + MCV	7	0.31	<0.001
RGEV + ASPDV + RCV + ICV	5	0.22	<0.001
RGEV + ASPDV + AIPDV	5	0.22	<0.001
RGEV + ASPDV + SRCV + antral branch	5	0.22	<0.001
ASPDV + SRCV	5	0.22	<0.001
RGEV + ASPDV + ICV	3	0.13	<0.001
RGEV + ASPDV + SRCV + ICV	3	0.13	<0.001
RGEV + ASPDV + SRCV + AIPDV	3	0.13	<0.001
RGEV + ASPDV + sRCV + aMCV	2	0.09	<0.001
RGEV + ASPDV + RCV + MCV + ICV	2	0.09	<0.001
RGEV + ASPDV + RCV + MCV	2	0.09	<0.001
RGEV + ASPDV + SRCV + RCV + ICV	2	0.09	<0.001
RGEV + AIPDV	1	0.04	<0.001
RGEV + ASPDV + SRCV + MCV + ICV	1	0.04	<0.001
RGEV + ASPDV + RCV + SRCV + aSRCV	1	0.04	<0.001
RGEV + ASPDV + SRCV+ retropyloric v.	1	0.04	<0.001
RGEV + ASPDV + SRCV + MRCV	1	0.04	<0.001
RGEV + double RCV	1	0.04	<0.001
RGEV + RCV + ICV	1	0.04	<0.001

The GPC type of the trunk, which, as mentioned above, is the most common, comprises a variety of 25 venous combinations, with RGEV+ASPDV+SRCV or RCV being the most frequent (33.13% and 30.84%, respectively) (Figure 2).

Although the GP type comprises 3 different vein confluences, the RGEV + ASPDV

combination accounts for 98% of cases (Table 1). The GC type consists of 9 different vein confluences, in which the RGEV + SRCV combination demonstrates the highest frequency (56.48%), followed by the RGEV + RCV (10.19%) (Figure 3).

The ASPDV + SRCV tributary confluence is the only one reported for the PC combination

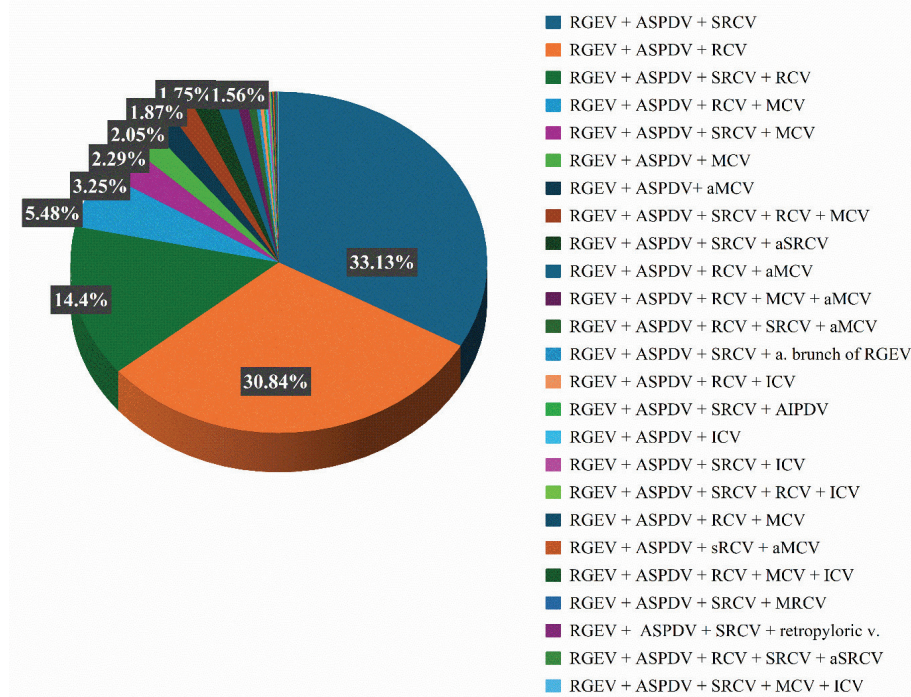


Figure 2. Distribution of the Henle trunk configurations forming the gastropancreatocolic (GPC) type.

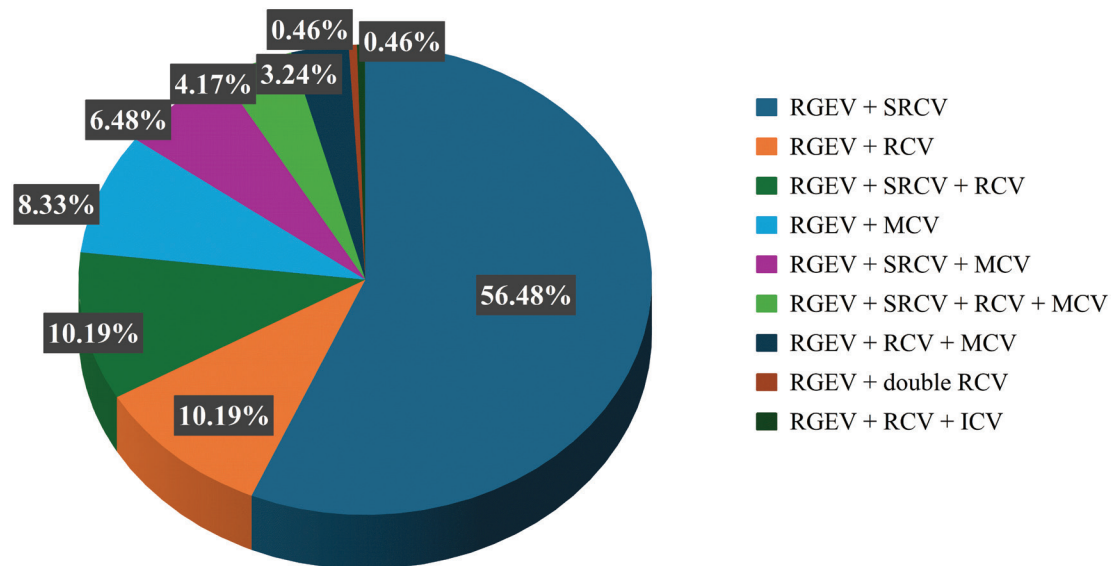
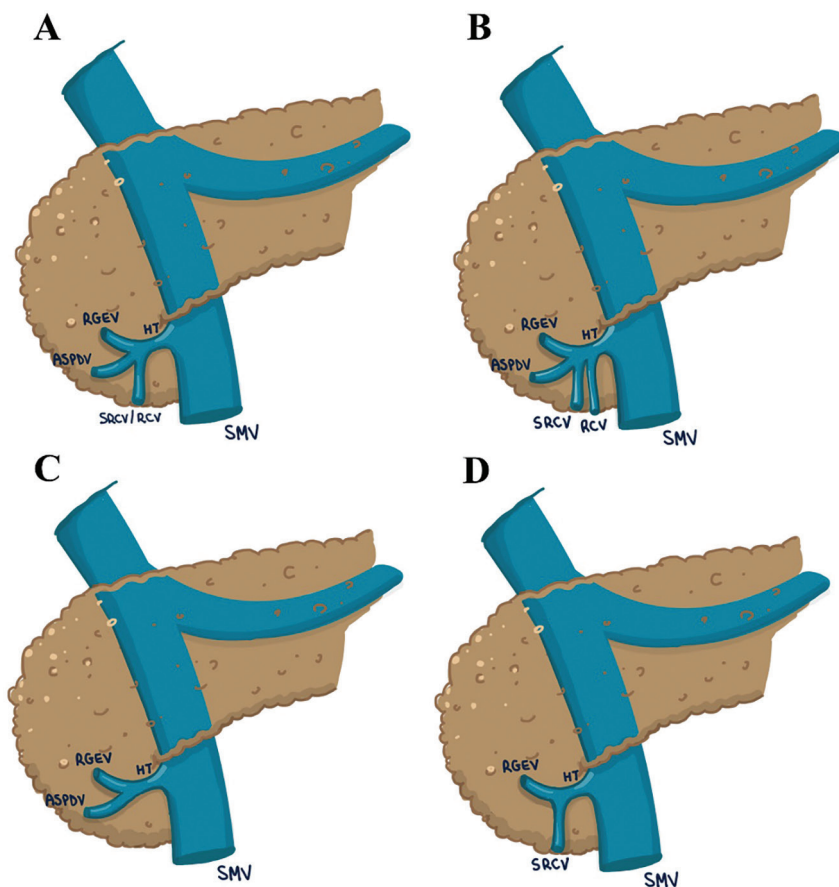


Figure 3. Distribution of the Henle trunk configurations forming the gastrocolic (GC) type.



artbydeep

Figure 4. Tributaries of the Henle trunk. (A) Gastropancreatocolic type with a single colic vein; (B) Gastropancreatocolic type with two colic veins; (C) Gastropancreatic type; (D) Gastrocolic type. HT=Henle trunk; RGEV=Right gastroepiploic vein; SRCV=Superior right colic vein; RCV=Right colic vein; ASPDV=Anterior superior pancreaticoduodenal vein; SMV=Superior mesenteric vein.

(Table 1). Overall, the most frequent vein confluence is RGEV+ASPDV+SRCV, accounting for 24.21% of the combinations, followed by RGEV+ASPDV+RCV at 22.54%. Although the GPC type is the most common, with its two main combinations (RGEV+ASPDV+SRCV or RCV) reaching 46.75% of all tributary confluences, the GP variation RGEV+ASPDV is the third most frequent confluence of the Henle trunk, with 16.90% of all vein combinations. The distributions of all the variation percentages are shown in Table 2. A chi-square test was performed, which revealed a high value ($P < 0.001$), confirming that certain confluences occur far more frequently than others (Table 2). Figure 4 presents schematic drawings

of the four most common Henle trunk configurations based on their venous tributary composition.

Discussion

The Henle trunk is an intricate three-dimensional anatomical structure resulting from the merging of the gastric, colic, and pancreatic veins, converging into the superior mesenteric vein (SMV) at an average distance of 2.2 cm from the inferior margin of the pancreas (19). Due to its considerable variability and often challenging accessibility, insufficient anatomical understanding can lead to inadvertent injury and substantial hemorrhage during abdominal surgeries (20, 31). However, a

well-defined trunk can serve as a vital reference point for surgeons, particularly in minimally invasive laparoscopic procedures (18). In recent years, numerous intraoperative (13, 24) and imaging investigations (14, 15, 29) have been conducted, involving extensive case studies that have enhanced the detailed characterization of the Henle trunk.

The morphological characteristics of the Henle trunk have long been debated due to the notable variability in its tributaries and the diverse anatomical definitions proposed by various research teams. In this study, the Henle trunk is defined as the confluence of the gastric, colic, and pancreatic veins draining into the SMV, comprising four primary types: the gastropancreatocolic (GPC), gastropancreatic (GP), gastrocolic (GC), and pancreatocolic (PC) trunk. This terminology contrasts with the original description by Henle (2), which equated the gastrocolic trunk with the Henle trunk rather than classifying it as a subset, further clarifying that the pancreatic vein may not always be present in the trunk, as noted by other scholars (11, 13).

The investigation involved 2,454 individuals, of whom 1,452 were sourced from studies conducted in the last six years. A 92.54% prevalence of the trunk was observed, aligning with numerous prior studies (4, 11, 22, 24, 26), although it is slightly elevated owing to more recent findings. The results stem from three analytical approaches—cadaveric, intraoperative and imaging—showing similar percentages of trunk presence (90.5%, 95%, and 91.2%, respectively).

Over two-thirds of Henle cases (73.09%) fall under the gastropancreatocolic (GPC) type, consistent with earlier research (5, 6, 10, 25) and more recent studies (13, 14, 28, 29). This figure is higher than that reported in previous review articles (32–34), reflecting an increased frequency of the GPC type in contemporary literature. The GPC type has consistently been identified as the most prevalent, with the sole exception being the analysis by Alsabilah et al. (23), in which the GPC trunk comprised only 34.5% of the patient population. The GP and GC types were found to be significantly less common than the GPC type, accounting for 17.17% and 9.51% of the cases, respectively. These

findings align with those of earlier reviews and recent analyses (32, 13).

In this study, the most frequent confluences of the gastropancreatocolic type included those featuring RGEV, ASPDV, and RCV or SRCV. The combinations involving SRCV and/or RCV colic veins constituted 57.27% of all venous arrangements. Cadaveric, operative, and imaging studies yielded comparable findings (52.9%, 55.47%, and 61.02%, respectively). The combination of RGEV+ASPDV+SRCV emerged as the most common type in 9 of the 21 publications reviewed (4, 10, 11, 14, 18, 21, 22, 27, 30), while RCV appeared in 6 of those studies (6, 13, 24, 26, 28, 29). The pooled prevalence of SRCV was slightly higher (33.13%) than that of RCV (30.84%) within the GPC Henle trunk. Surgeons should be aware that while GPC is the predominant Henle type, the GP variation containing RGEV and ASPDV ranks as the third most frequent, making up 16.9% of all Henle confluences.

Conclusions

The Henle gastrocolic trunk is an anatomical structure with a high prevalence that can be used as a landmark during pancreatic or colorectal resections and other abdominal procedures. Our findings confirmed the significant heterogeneity of venous configurations. Precise knowledge of venous anatomy in the GTH region is essential for improving surgical safety and minimizing intraoperative bleeding.

What Is Already Known on This Topic:

The gastrocolic trunk of Henle (GTH) is a venous confluence located at the inferior pancreatic border that drains into the superior mesenteric vein. The complex vascular anatomy of the structure is of major clinical importance during minimally invasive colorectal and pancreatic surgery, in which inadvertent injury can lead to significant hemorrhage. Cadaveric, intraoperative, and imaging studies have identified numerous variations in GTH anatomy. However, the reported prevalence and configuration patterns vary considerably in the literature, partly due to differences in definitions and classification systems.

What This Study Adds:

This systematic review includes 21 studies and the largest number of reported cases to date (2454 cases), providing the most comprehensive analysis of Henle trunk morphology. By integrating 1452 new cases re-

ported in the last six years, in operative and imaging studies, it contributes to precise knowledge of the trunk anatomy. Moreover, it offers a unified classification system (GPC, GP, GC, and PC) and documents 38 venous confluences, quantifying their prevalence. This approach resolves previous inconsistencies in definitions, updates the literature, and provides a clear anatomical framework for improving surgical planning and safety.

Authors' Contributions: Conception and design: GS and DC; Acquisition, analysis and interpretation of data: GS and DC; Drafting the article: GS, DF and DC; Revising it critically for important intellectual content: DF, GT and TT; Approved final version of the manuscript: GS, DC, DF, GT and TT.

Acknowledgements: The authors would like to thank Despoina Sperdouli for her valuable contribution to the creation of the anatomical drawings depicting the variations of the Henle trunk.

Conflict of Interest: The authors declare that they have no conflict of interest.

References

- Snow EL. Variation is the rule: Insights about translational research on anatomical variations. *Translational Research in Anatomy*. 2024;37(2):100333. doi: 10.1016/j.tria.2024.100333.
- Henle J. *Handbuch Der Systematischen Anatomie Des Menschen [Handbook of Systematic Human Anatomy]*. Braunschweig, Germany: Druck und Verlag von Friedrich Vieweg und Sohn; 1868.
- Descomps P, De Lalaubie G. Les veines mésentériques [The mesenteric veins]. *J Anat Physio Norm Pathol Homme Anim* 1912;48:337-76. French.
- Zhang J, Rath AM, Boyer JC, Dumas JL, Menu Y, Chevrel JP. Radioanatomic study of the gastrocolic venous trunk. *Surg Radiol Anat*. 1994;16(4):413-8. doi: 10.1007/BF01627663.
- Yamaguchi S, Kuroyanagi H, Milsom JW, Sim R, Shimada H. Venous anatomy of the right colon: precise structure of the major veins and gastrocolic trunk in 58 cadavers. *Dis Colon Rectum*. 2002;45(10):1337-40. doi: 10.1097/01.DCR.0000027284.76452.84.
- Kuzu MA, İsmail E, Çelik S, Şahin MF, Güner MA, Hohenberger W, et al. Variations in the Vascular Anatomy of the Right Colon and Implications for Right-Sided Colon Surgery. *Dis Colon Rectum*. 2017;60(3):290-8. doi: 10.1097/DCR.0000000000000777.
- Voiglio EJ, Boutillier du Retail C, Neidhardt JP, Caillet JL, Barale F, Mertens P. Gastrocolic vein. Definition and report of two cases of avulsion. *Surg Radiol Anat*. 1998;20(3):197-201. doi: 10.1007/s00276-998-0197-9.
- Clinical Outcomes of Surgical Therapy Study Group; Nelson H, Sargent DJ, Wieand HS, Fleshman J, Anvari M, et al. A comparison of laparoscopically assisted and open colectomy for colon cancer. *N Engl J Med*. 2004;350(20):2050-9. doi: 10.1056/NEJMoa032651.
- West NP, Hohenberger W, Weber K, Perrakis A, Finan PJ, Quirke P. Complete mesocolic excision with central vascular ligation produces an oncologically superior specimen compared with standard surgery for carcinoma of the colon. *J Clin Oncol*. 2010;28(2):272-8. doi: 10.1200/JCO.2009.24.1448. Epub 2009 Nov 30.
- Lee SJ, Park SC, Kim MJ, Sohn DK, Oh JH. Vascular Anatomy in Laparoscopic Colectomy for Right Colon Cancer. *Dis Colon Rectum*. 2016;59(8):718-24. doi: 10.1097/DCR.0000000000000636.
- Miyazawa M, Kawai M, Hirono S, Okada K, Shimizu A, Kitahata Y, et al. Preoperative evaluation of the confluent drainage veins to the gastrocolic trunk of Henle: understanding the surgical vascular anatomy during pancreaticoduodenectomy. *J Hepatobiliary Pancreat Sci*. 2015;22(5):386-91. doi: 10.1002/jhbp.205. Epub 2015 Jan 7.
- Negoi I, Beuran M, Hostiuc S, Negoi RI, Inoue Y. Surgical Anatomy of the Superior Mesenteric Vessels Related to Pancreaticoduodenectomy: a Systematic Review and Meta-Analysis. *J Gastrointest Surg*. 2018;22(5):802-17. doi: 10.1007/s11605-018-3669-1. Epub 2018 Jan 23.
- He Z, Yang C, Diao D, Wu D, Fingerhut A, Sun Y, et al. Anatomic patterns and clinical significance of gastrocolic trunk of Henlé in laparoscopic right colectomy for colon cancer: Results of the HeLaRC trial. *International Journal of Surgery*. 2022;104:1-8. doi: https://doi.org/10.1016/j.ijssu.2022.106718.
- Yu A, Li Y, Zhang H, Hu G, Zhao Y, Guo J, et al. Development and validation of a preoperative nomogram for predicting the surgical difficulty of laparoscopic colectomy for right colon cancer: a retrospective analysis. *Int J Surg*. 2023;109(4):870-8. doi: 10.1097/JS9.0000000000000352.
- Zhao X, Zhang H, Zhao H, Kong D, Zeng W, Gao F, et al. Anatomic association between the gastrocolic trunk of Henle and right colic artery by high-quality CT venography. *Sci Rep*. 2024;14(1):32054. doi: 10.1038/s41598-024-83588-w.
- Henry BM, Tomaszewski KA, Walocha JA. *Methods of Evidence-Based Anatomy: a guide to conducting systematic reviews and meta-analysis of anatomical studies*. *Ann Anat*. 2016;205:16-21. doi: 10.1016/j.aanat.2015.12.002. Epub 2016 Feb 1.
- Henry BM, Tomaszewski KA, Ramakrishnan PK, Roy J, Vikse J, Loukas M, et al. Development of the anatomical quality assessment (AQUA) tool for the quality assessment of anatomical studies included in meta-analyses and systematic reviews. *Clin Anat*. 2017;30(1):6-13. doi: 10.1002/ca.22799. Epub 2016 Nov 18.

18. Ignjatovic D, Spasojevic M, Stimec B. Can the gastrocolic trunk of Henle serve as an anatomical landmark in laparoscopic right colectomy? A postmortem anatomical study. *Am J Surg.* 2010;199(2):249-54. doi: 10.1016/j.amjsurg.2009.03.010. Epub 2009 Nov 5.
19. Ignjatovic D, Stimec B, Finjord T, Bergamaschi R. Venous anatomy of the right colon: three-dimensional topographic mapping of the gastrocolic trunk of Henle. *Tech Coloproctol.* 2004;8(1):19-21; discussion 21-2. doi: 10.1007/s10151-004-0045-9.
20. Jin G, Tuo H, Sugiyama M, Oki A, Abe N, Mori T, et al. Anatomic study of the superior right colic vein: its relevance to pancreatic and colonic surgery. *Am J Surg.* 2006 Jan;191(1):100-3. doi: 10.1016/j.amjsurg.2005.10.009.
21. Açar Hİ, Cömert A, Avşar A, Çelik S, Kuzu MA. Dynamic article: surgical anatomical planes for complete mesocolic excision and applied vascular anatomy of the right colon. *Dis Colon Rectum.* 2014;57(10):1169-75. doi: 10.1097/DCR.000000000000128.
22. Lange JF, Koppert S, van Eyck CH, Kazemier G, Kleinsink GJ, Godschalk M. The gastrocolic trunk of Henle in pancreatic surgery: an anatomo-clinical study. *J Hepatobiliary Pancreat Surg.* 2000;7(4):401-3. doi: 10.1007/s005340070035.
23. Alsabilah JF, Razvi SA, Albandar MH, Kim NK. Intraoperative Archive of Right Colonic Vascular Variability Aids Central Vascular Ligation and Redefines Gastrocolic Trunk of Henle Variants. *Dis Colon Rectum.* 2017;60(1):22-9. doi: 10.1097/DCR.0000000000000720.
24. Wu C, Ye K, Wu Y, Chen Q, Xu J, Lin J, et al. Variations in right colic vascular anatomy observed during laparoscopic right colectomy. *World J Surg Oncol.* 2019;17(1):16. doi: 10.1186/s12957-019-1561-4.
25. Sakaguchi T, Suzuki S, Morita Y, Oishi K, Suzuki A, Fukumoto K, et al. Analysis of anatomic variants of mesenteric veins by 3-dimensional portography using multidetector-row computed tomography. *Am J Surg.* 2010;200(1):15-22. doi: 10.1016/j.amjsurg.2009.05.017. Epub 2010 Jan 15.
26. Ogino T, Takemasa I, Horitsugi G, Furuyashiki M, Ohta K, Uemura M, et al. Preoperative evaluation of venous anatomy in laparoscopic complete mesocolic excision for right colon cancer. *Ann Surg Oncol.* 2014;21 Suppl 3:S429-35. doi: 10.1245/s10434-014-3572-2. Epub 2014 Mar 17.
27. Gao Y, Lu Y. Variations of Gastrocolic Trunk of Henle and Its Significance in Gastrocolic Surgery. *Gastroenterol Res Pract.* 2018;2018:3573680. doi: 10.1155/2018/3573680.
28. Gu L, Wen S, Xu C, Zhu J, Liu P, Xu Q. Computed Tomography Angiography of Gastrocolic Vein Trunk by Morphological Filtering Technique in Right Colon Cancer. *Ther Clin Risk Manag.* 2021;17:1-7. doi: 10.2147/TCRM.S282504.
29. Grytsenko S, Dzyubanovsky I, Hrytsenko I, Bedeniuk A. PREOPERATIVE COMPUTED TOMOGRAPHY ANGIOGRAPHY IN MULTIDISCIPLINARY PERSONALIZED ASSESSMENT OF PATIENT WITH RIGHT-SIDED COLON CANCER: SURGEON AND RADIOLOGIST POINT OF VIEW. *ABCD Arq Bras Cir Dig.* 2022;35:e1679. doi: <https://doi.org/10.1590/0102-672020220002e1679>.
30. Ghimire R, Thapa N, Acharya BP, Sah BP, Limbu Y, Regmee S, et al. Intraoperative Variations of the Gastrocolic Trunk of Henle noted in Gastrointestinal Surgeries. *J Nepal Health Res Counc.* 2024;22(2):366-9. doi: 10.33314/jnhrc.v22i02.5132.
31. Kimura W. Surgical anatomy of the pancreas for limited resection. *J Hepatobiliary Pancreat Surg.* 2000;7(5):473-9. doi: 10.1007/s005340070017.
32. Stefura T, Kacprzyk A, Droś J, Pędziwiatr M, Major P, Hołda MK. The venous trunk of henle (gastrocolic trunk): A systematic review and meta-analysis of its prevalence, dimensions, and tributary variations. *Clin Anat.* 2018;31(8):1109-21. doi: 10.1002/ca.23228. Epub 2018 Aug 30.
33. Negoï I, Beuran M, Hostiuç S, Negoï RI, Inoue Y. Surgical Anatomy of the Superior Mesenteric Vessels Related to Colon and Pancreatic Surgery: A Systematic Review and Meta-Analysis. *Sci Rep.* 2018 Mar 8;8(1):4184. doi: 10.1038/s41598-018-22641-x.
34. Peltrini R, Luglio G, Pagano G, Sacco M, Sollazzo V, Bucci L. Gastrocolic trunk of Henle and its variants: review of the literature and clinical relevance in colectomy for right-sided colon cancer. *Surg Radiol Anat.* 2019;41(8):879-87. doi: 10.1007/s00276-019-02253-4. Epub 2019 May 14.